



## **Dramatic response of STRN-NTRK -fused malignant glioneuronal tumor to larotrectinib in adult**

Julie Boyer, Cristina Birzu, Franck Bielle, Clara Goulas, Julien Savatovsky,  
Carine Karachi, Ahmed Idbaih

### **► To cite this version:**

Julie Boyer, Cristina Birzu, Franck Bielle, Clara Goulas, Julien Savatovsky, et al.. Dramatic response of STRN-NTRK -fused malignant glioneuronal tumor to larotrectinib in adult. *Neuro-Oncology*, 2021, 10.1093/neuonc/noab080 . hal-03251623

**HAL Id: hal-03251623**

**<https://hal.sorbonne-universite.fr/hal-03251623>**

Submitted on 7 Jun 2021

**HAL** is a multi-disciplinary open access archive for the deposit and dissemination of scientific research documents, whether they are published or not. The documents may come from teaching and research institutions in France or abroad, or from public or private research centers.

L'archive ouverte pluridisciplinaire **HAL**, est destinée au dépôt et à la diffusion de documents scientifiques de niveau recherche, publiés ou non, émanant des établissements d'enseignement et de recherche français ou étrangers, des laboratoires publics ou privés.

## **Dramatic response of *STRN-NTRK* fused malignant glioneuronal tumor to Larotrectinib in adult**

Key words: glioneuronal tumor, *NTRK* fusion, molecular targeted therapy.

**Julie Boyer, Cristina Birzu, Franck Bielle, Clara Goulas, Julien Savatovsky, Carine Karachi, and Ahmed Idbaih.**

Sorbonne Université, Inserm, CNRS, UMR S 1127, Institut du Cerveau et de la Moelle épinière, ICM, AP-HP, Hôpitaux Universitaires La Pitié Salpêtrière - Charles Foix, Service de Neurologie 2-Mazarin, F-75013, Paris, France (J.B., C.B., A.I.) ; Sorbonne Université, Inserm, CNRS, UMR S 1127, Institut du Cerveau et de la Moelle épinière, ICM, AP-HP, Hôpitaux Universitaires La Pitié Salpêtrière - Charles Foix, Service de Neuropathologie-Escourolle, F-75013, Paris, France (F.B.) ; AP-HP, Hôpitaux Universitaires La Pitié Salpêtrière - Charles Foix, Service de Pharmacie, F-75013, Paris, France (C.G.) ; Service d'Imagerie Médicale, Hôpital Fondation Rothschild, F-75019, Paris, France (J.S.) ; Sorbonne Université, Inserm, CNRS, UMR S 1127, Institut du Cerveau et de la Moelle épinière, ICM, AP-HP, Hôpitaux Universitaires La Pitié Salpêtrière - Charles Foix, Service de Neurochirurgie, F-75013, Paris, France (C.K.).

**Corresponding author:** Ahmed Idbaih, AP-HP, Hôpitaux Universitaires La Pitié Salpêtrière - Charles Foix, Service de Neurologie 2-Mazarin, 47-83 boulevard de l'Hôpital F-75013, Paris, France (ahmed.idbaih@aphp.fr, Tel 0033142160385, Fax 0033142160418).

Glioneuronal tumors (GNT) are rare entities characterized by the proliferation of cells expressing a mixture of neuronal and glial markers. Most GNT are classified as low-grade, but some may present high grade features.

We report here a case on a left-handed 53 year-old Caucasian man with no medical history who presented in 2011 with partial seizures, revealing a right non-enhancing insular brain lesion compatible with a diffuse low-grade glioma (Fig 1A). The lesion was therefore monitored and remained stable for 8 years. In June 2019 the patient presented rapid clinical and radiological tumor progression. The tumor was surgically removed. Pathological examination identified a high-grade GNT exhibiting frequent mitosis, vascular proliferation, necrosis, and Ki67 proliferative activity of 20%. Immunohistochemistry analysis revealed no IDH1R132H, FGFR3, BRAFV600E mutations or EGFR expression. No microsatellite instability or 1p19q codeletion was detected. In contrast, pan-TRK staining was positive (Fig 1B) and transcriptomic analysis revealed *STRN1-NTRK2* fusion.

First line treatment included concurrent radiochemotherapy delivering 59.4 Gy plus Temozolomide, followed by 5 cycles of adjuvant Temozolomide, which ended in February 2020. Follow-up MRI showed tumor progression in March 2020 and led to the initiation of a second line treatment with Larotrectinib (TRK inhibitor) starting March 30<sup>th</sup>, 2020 with 75 mg twice a day, to 100 mg twice a day starting the 24<sup>th</sup> of April, 2020.

The patient then remained clinically stable with minor troubles with word finding. The patient has presented no seizures since September 2019 and is currently being treated with regular anticonvulsant monotherapy.

Follow-up MRI performed in June 2020 showed complete response, that was maintained in February 2021 (Fig 1C). Larotrectinib tolerance is good with no adverse events.

*NTRK* genes are involved in neurodevelopment, three *NTRK* genes are described: *NTRK1*, *NTRK2* and *NTRK3*, which respectively encode transmembrane Tyrosine kinase Receptors TrkA, TrkB and TrkC proteins. When activated by their specific ligands (mainly neurotrophins and neuronal growth factors) Trk receptors lead to activation of intracellular downstream differentiation and proliferation signaling pathways.

*NTRK* fusions have first been described in 1982. Since the approval by the FDA of TRK inhibitors in 2018, *NTRK* fusions have been increasingly screened for in solid cancers, including in CNS tumors <sup>1</sup>. *NTRK* fusions' resulting chimera proteins show constitutive activation of the tyrosine kinase domain inducing aberrant cell proliferation (Fig 1D).

In 2017 Alvarez-Breckenridge *et al.* reported an *STRN3-NTRK2* fused ganglioglioma (with no therapeutic implication) and a *BCAN-NTRK1* fused low-grade GNT, which treated with Entrectinib, led to partial tumor response <sup>2</sup>.

A limited number of cases showing efficacy of Larotrectinib in pediatric *NTRK* fusion-positive intracranial tumors have been reported since 2018 <sup>3</sup>. Although preclinical studies highlight a better CNS penetration for Entrectinib <sup>4</sup>, Larotrectinib has also been found in significant levels in brain homogenates <sup>5</sup>. The CNS penetration, paired with durable disease control in patients with both metastatic and primary CNS *NTRK* fused tumors (A. E. Drilon, unpublished data), in addition to a satisfying security profile, support Larotrectinib as a therapeutic option in these tumors.

One case of *ARHGEF2-NTRK1* fused high-grade GNT was described by Kurozumi *et al.* in 2019 <sup>6</sup>, emphasizing the need for fusion testing in such tumors.

To our knowledge, our patient is the first one in the literature exhibiting a GNT with a gene fusion involving *NTRK2* as oncogene and *STRN1* as upstream gene partner. The pathological diagnosis of an unusual aggressive GNT lacking BRAFV600E mutation led to further molecular analysis and allowed identification of a specific druggable molecular alteration with clinical benefit for the patient.

This case illustrates the importance of complementary molecular analysis and the brain penetrance and efficacy of *NTRK* inhibitors in *NTRK*-fused high-grade GNT.

## References

1. Gambella A, Senetta R, Collemi G, et al. NTRK Fusions in Central Nervous System Tumors: A Rare, but Worthy Target. *Int J Mol Sci.* 2020;21(3). doi:10.3390/ijms21030753
2. Alvarez-Breckenridge C, Miller JJ, Nayyar N, et al. Clinical and radiographic response following targeting of BCAN-NTRK1 fusion in glioneuronal tumor. *NPJ Precis Oncol.* 2017;1. doi:10.1038/s41698-017-0009-y
3. Alharbi M, Mobark NA, Balbaid AAO, et al. Regression of *ETV6-NTRK3* Infantile Glioblastoma After First-Line Treatment With Larotrectinib. *JCO Precis Oncol.* 2020;(4):796-800. doi:10.1200/PO.20.00017
4. Fischer H, Ullah M, de la Cruz CC, et al. Entrectinib, a TRK/ROS1 inhibitor with anti-CNS tumor activity: differentiation from other inhibitors in its class due to weak interaction with P-glycoprotein. *Neuro-Oncol.* 2020;22(6):819-829. doi:10.1093/neuonc/noaa052
5. Sparidans RW, Wang Y, Schinkel AH, Schellens JHM, Beijnen JH. Quantitative bioanalytical assay for the tropomyosin receptor kinase inhibitor larotrectinib in mouse plasma and tissue homogenates using liquid chromatography-tandem mass spectrometry. *J Chromatogr B.* 2018;1102-1103:167-172. doi:10.1016/j.jchromb.2018.10.023
6. Kurozumi K, Nakano Y, Ishida J, et al. High-grade glioneuronal tumor with an ARHGEF2–NTRK1 fusion gene. *Brain Tumor Pathol.* 2019;36(3):121-128. doi:10.1007/s10014-019-00345-y

## Legend to Figure 1:

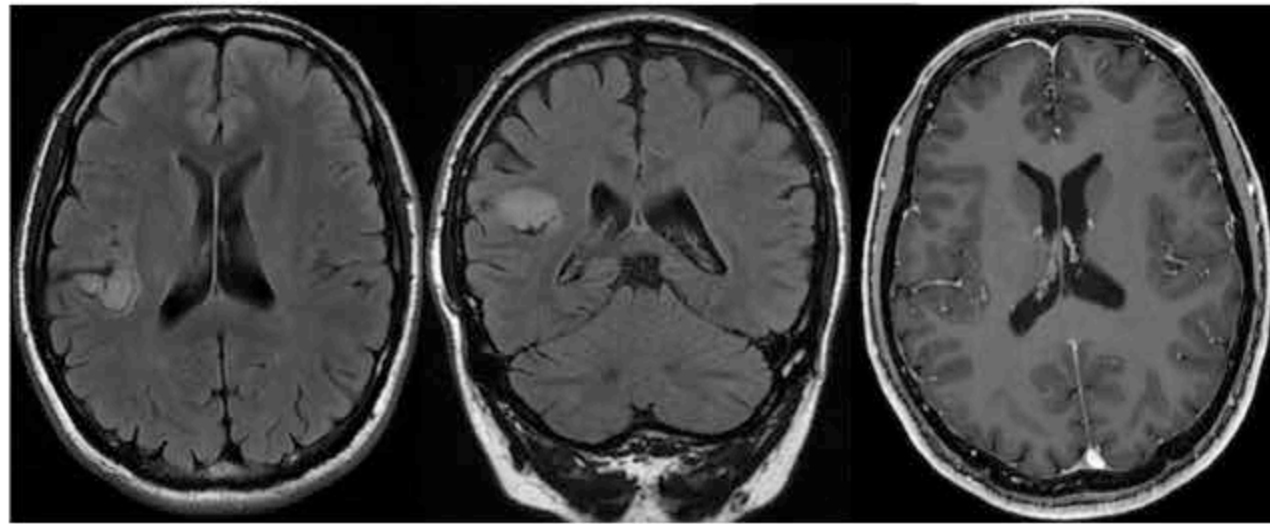
A, brain MRI in 2012. From left to right: axial and coronal FLAIR, axial T1 gadolinium-enhanced section showing a right non-enhancing insular intraaxial lesion. B, from left to right: 1) epithelioid and ganglion-like tumor cells and microvascular proliferation ; 2) strong expression of the glial marker ; 3) heterogeneous expression of the neuronal marker ; 4) p53 strong and heterogeneous staining ; 5) pan-TRK strong expression in tumor cells ; 6) high proliferation index of 20%. Images 2 to 6 were obtained using IHC (HE: hematoxylin-eosin, IHC: immunohistochemistry). C, T1 gadolinium-enhanced MRI measured tumor volume as a function of time and corresponding MRI scans. (RCT: radiochemotherapy). D, schematic representation of *NTRK2-STRN1* fusion (TKD: Tyrosine Kinase Domain, CCD: Coiled Coil Domain).

## **Acknowledgments**

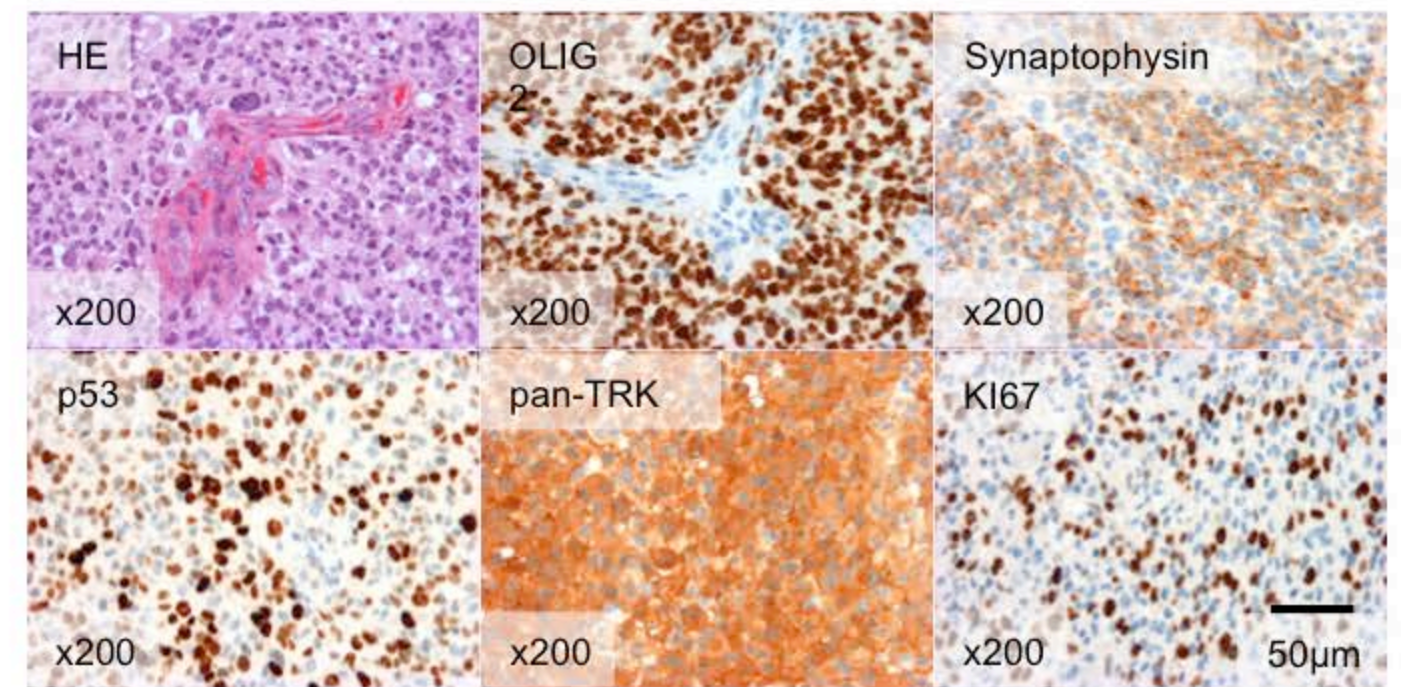
The research leading to these results has received funding from the program “Investissements d’avenir” ANR-10-IAIHU-06. Institut Universitaire de Cancérologie INCA-DGOS-Inserm\_12560 SiRIC CURAMUS is financially supported by the French National Cancer Institute, the French Ministry of Solidarity and Health and Inserm. Charlotte Bellamy for reviewing English.



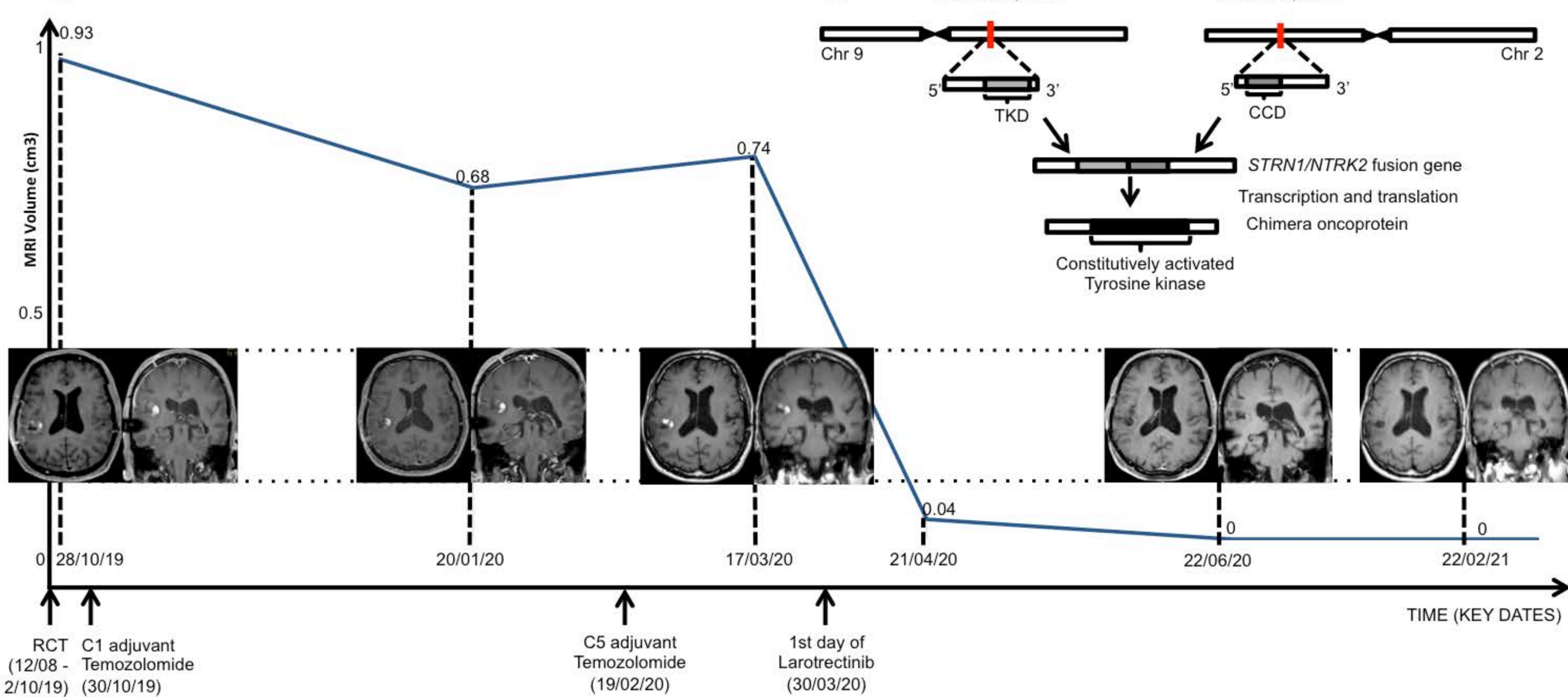
A.



B.



C.



D.

