



Endovascular aortic arch repair with a pre-cannulated double-fenestrated physician-modified stent graft: a benchtop experiment

Youcef Lounes, Lucien Chassin-Trubert, Thomas Gandet, Baris Ata Ozdemir, Antoine Peyron, Mariama Akodad, Pierre Alric, Ludovic Canaud

► To cite this version:

Youcef Lounes, Lucien Chassin-Trubert, Thomas Gandet, Baris Ata Ozdemir, Antoine Peyron, et al.. Endovascular aortic arch repair with a pre-cannulated double-fenestrated physician-modified stent graft: a benchtop experiment. *Interactive Cardiovascular and Thoracic Surgery*, 2021, 32 (6), pp.942-949. 10.1093/icvts/ivab023 . hal-03258567

HAL Id: hal-03258567

<https://hal.science/hal-03258567>

Submitted on 19 Jun 2021

HAL is a multi-disciplinary open access archive for the deposit and dissemination of scientific research documents, whether they are published or not. The documents may come from teaching and research institutions in France or abroad, or from public or private research centers.

L'archive ouverte pluridisciplinaire **HAL**, est destinée au dépôt et à la diffusion de documents scientifiques de niveau recherche, publiés ou non, émanant des établissements d'enseignement et de recherche français ou étrangers, des laboratoires publics ou privés.

Endovascular aortic arch repair with a pre-cannulated double-fenestrated physician-modified stent graft: a benchtop experiment

Youcef Lounes^{a,b,*}, Lucien Chassin-Trubert^{a,b}, Thomas Gandet^c, Baris Ata Ozdemir^{a,b,d},
Antoine Peyron^e, Mariama Akodad^f, Pierre Alric^{a,b} and Ludovic Canaud^{a,b}

^a Department of Vascular and Thoracic Surgery, Arnaud de Villeneuve Hospital, Montpellier, France

^b Arnaud de Villeneuve Hospital, INSERM U1046, UM1, CHRU of Montpellier, Montpellier, France

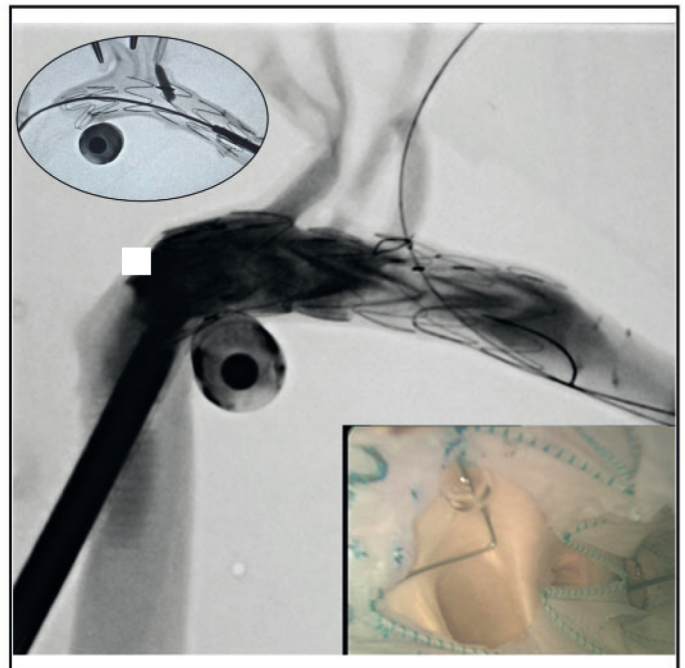
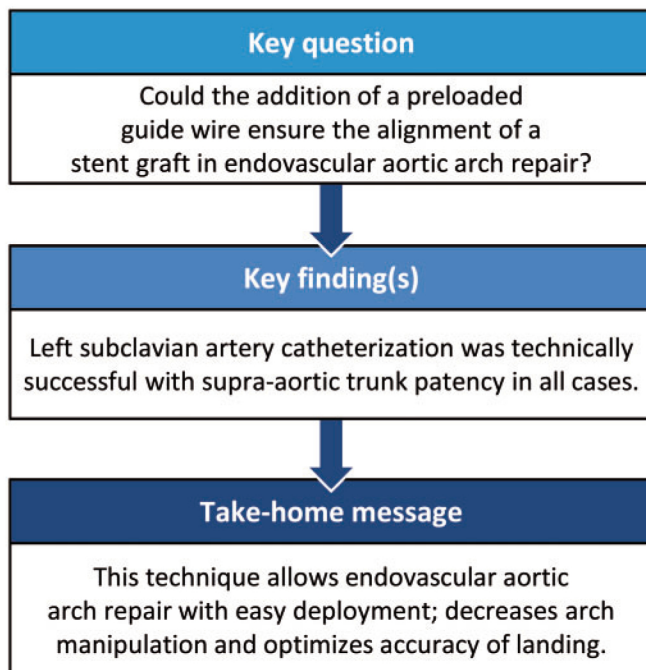
^c Department of Cardio-Vascular Surgery, Arnaud de Villeneuve Hospital, Montpellier, France

^d Arnaud de Villeneuve Hospital, University of Bristol, Bristol, UK

^e Legal Department, Lapeyronie Hospital, Montpellier, France

^f Cardiology Department, Montpellier University Hospital, Montpellier, France

* Corresponding author. Vascular Surgery Department, Montpellier University Hospital, 371 Av Doyen Gaston Giraud, 34090 Montpellier, France.
Tel: +33-467-336270; fax: +33-467-338558; e-mail: youcef.lounes@gmail.com (Y. Lounes).



Abstract

OBJECTIVES: The critical step in total endovascular aortic arch repair is to ensure alignment of fenestrations with, and thus maintenance of flow to, supra-aortic trunks. This experimental study evaluates the feasibility and accuracy of a double-fenestrated physician-modified endovascular graft [single common large fenestration for the brachiocephalic trunk and left common carotid artery and a distal small fenestration for left subclavian artery (LSA) with a preloaded guidewire for the LSA] for total endovascular aortic arch repair.

METHODS: Eight fresh human cadaveric thoracic aortas were harvested. Thoracic endografts with a physician-modified double fenestration were deployed for total endovascular aortic arch repair in a bench test model. A guidewire was preloaded through the distal fenestration for the LSA. All experiments were undertaken in a hybrid room under fluoroscopic guidance with subsequent angioscopy and open evaluation for assessment.

RESULTS: Mean aortic diameter in zone 0 was 31.3 ± 3.33 mm. Mean duration for stent graft modification was 20.1 ± 5.8 min. Mean duration of the procedure was 24 ± 8.6 min. The Medtronic Valiant Captivia stent graft was used in 6 and the Cook Alpha Zenith thoracic stent graft in 2 cases. LSA catheterization was technically successful with supra-aortic trunk patency in 100% of cases.

CONCLUSIONS: The use of a double-fenestrated stent graft with a preloaded guidewire appears to be a useful technical addition to facilitate easy and correct alignment of stent graft fenestrations with supra-aortic trunk origins.

Keywords: Aortic arch • Aorta • Physician modified stent grafts • Thoracic endovascular aortic repair • Experimental

ABBREVIATIONS

BT	Brachiocephalic trunk
LCCA	Left common carotid artery
LSA	Left subclavian artery
PGW	Preloaded guide wire
PMEG	Physician-modified endovascular graft
TEVAR	Thoracic endovascular aneurysm repair

INTRODUCTION

Thoracic endovascular aneurysm repair (TEVAR) enables treatment of patients with complex comorbidities unable to tolerate open surgical repair. Initially, TEVAR was limited to deployment distal to the left subclavian artery (LSA). However, with adjunctive revascularization or debranching, even a zone 0 deployment within the ascending aorta is technically feasible. Recently, custom-made branched and fenestrated stent grafts are emerging as less invasive alternatives for zone 0 TEVAR [1]. The main disadvantage of this new custom-made stent graft technology is the time required for graft preparation, taking generally between 4 and 6 weeks, effectively limiting use in the emergency setting. In this context, the use of physician-modified endovascular grafts (PMEGs) with fenestrations has the advantage of rapid preparation, allowing its utilization in urgent situations. Adequate planning, stent graft modification, correct alignment of fenestrations and branch vessel catheterization are required for successful execution and ensure procedural safety. The authors have previously published their experience with PMEGs with double fenestrations for zone 0 TEVAR with encouraging results [2, 3]. A proximal common large fenestration was used for the brachiocephalic trunk (BT) and the left common carotid artery (LCCA) and a distal small fenestration for the LSA. With this approach, only the LSA fenestration is cannulated and stented. The critical and challenging step during these procedures is catheterization of the LSA through the distal stent graft fenestration. The catheterization requires perfect alignment between the fenestration and the target vessel and can be difficult if there is an acute angle of departure of the LSA from the aortic arch, LSA tortuosity or lack of apposition between the stent graft fenestration and the aortic wall. In those with smaller aortic diameters, limited space for guidewire movement can also make the catheterization challenging. A recent study [4] has demonstrated the use of preloaded guide wires (PGWs) in fenestrated stent grafts in the aortic arch. Taking all these into considerations, it was hypothesized that a preloaded guidewire may facilitate LSA cannulation.




Figure 1: Benchtop closed system pulsatile flow model connected to a human cadaveric aorta in the hybrid room for the experimental study.

This experimental study using human cadaveric aortas was carried out to primarily evaluate the feasibility and accuracy of PMEGs with a preload guidewire through the LSA fenestration to assist catheterization during zone 0 TEVAR.

METHODS

The study was approved by the authors’ institutional review committee and the ethics committee.

Harvesting and preparation of cadaveric aortas

With the permission of the department and in accordance with French regulations, from November 2018 to January 2020, fresh human aortas were harvested at autopsy from adult subjects who had died up to a maximum of 4 days previously. The aortas were harvested from above the aortic valve up to the distal part of the descending thoracic aorta. The BT, LCCA and LSA were harvested to their maximum length (from 4 cm to >7 cm). The aortas were immediately placed on ice and maintained at 4°C. Experiments were performed within 2 h of harvesting.

Bench test model

A previously described benchtop closed pulsatile flow model (Fig. 1) was used to mimic flow and pressure in the aorta allowing the deployment of the stent grafts to be as close as possible to physiological conditions [5, 6]. The pump rate was maintained at

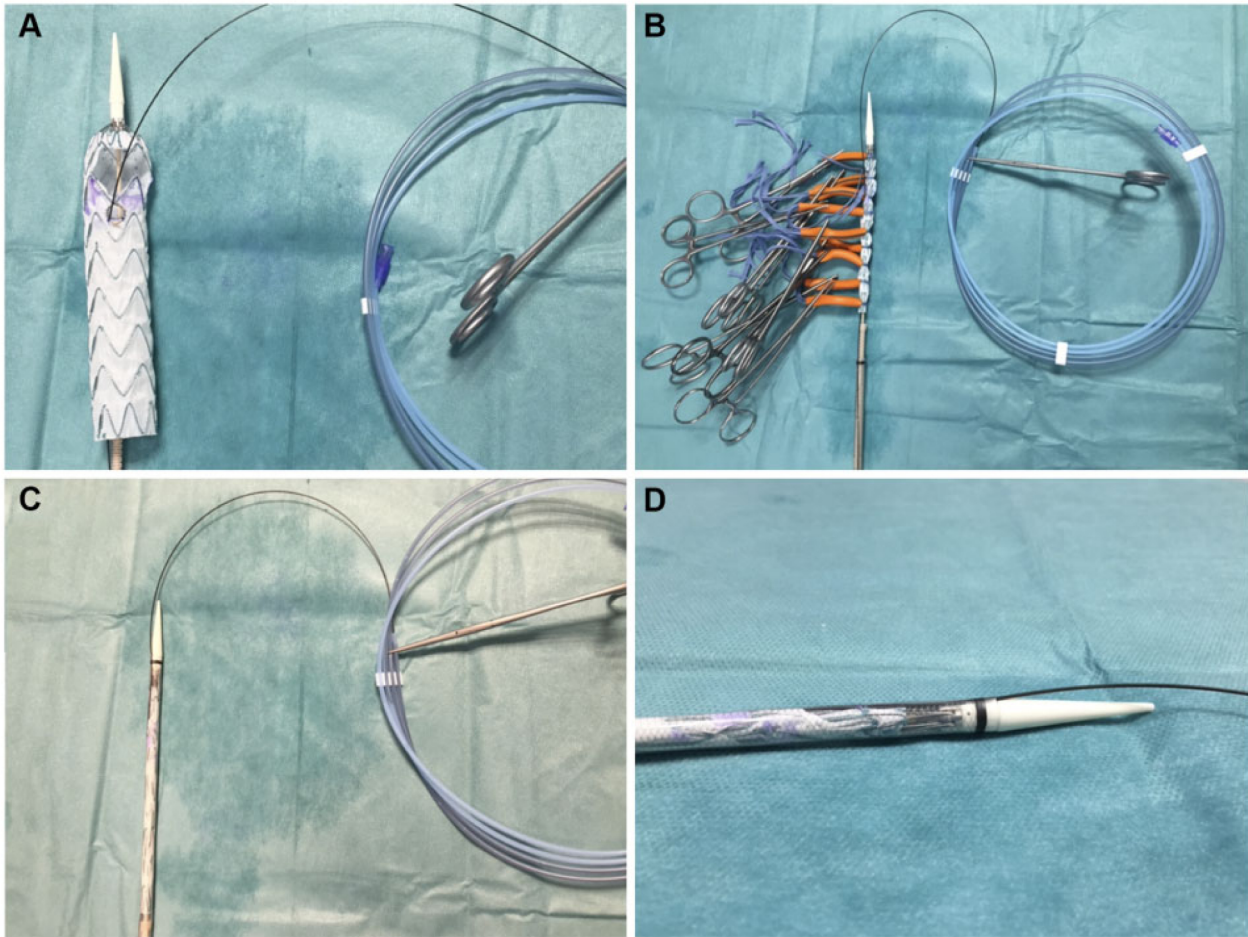


Figure 2: Physician-modified endovascular graft 34 × 150 Valiant Captivia thoracic stent graft back table preparation. (A) Thoracic stent graft is fully unsheathed and a proximal common fenestration for brachiocephalic trunk and left common carotid artery and a distal fenestration for left subclavian artery is created with a pre-loaded wire. (B) The physician-modified endovascular graft is constrained with the use of multiple nylon loops on snuggers maintaining the left subclavian artery pre-loaded guidewire. (C) The physician-modified endovascular graft is reloaded. (D) The preloaded guide wire in the correct position between the tapered tip and the introducer sheath after the completed re-sheathing of the stent graft.

60 beats/min and systolic/diastolic pressure at 100/60 mmHg. A single common angulation of the aortic arch of 90° was used to assess the deployment accuracy of the modified stent graft.

Experimental set-up

Aorta preparation. After aortic harvest, the BT, LCCA, and LSA diameters were directly measured with a ruler, as well as the distance between the edges of each supra-aortic branch vessel. Aortic diameters in zone 0–3 by the Ishimaru's classification were registered. The intercostal and lumbar arteries were clipped or ligatured. A 30-mm knitted Dacron tube graft was anastomosed end to end to the proximal ascending aorta and connected to the inflow segment of the bench model (Fig. 1).

The distal end of each supra-aortic truck was connected to an 8-Fr introducer sheath. The BT was then connected to a pressure line to measure the variations in the supra-aortic vessels during the experimental procedure. The system was directly cannulated to the distal end of the thoracic aorta to obtain a closed and hermetic circulation. A 24-Fr sheath (Dryseal; W. L. Gore & Associates, Newark, DE, USA) was introduced in the distal part of the aorta to allow introduction of the modified stent graft (Fig. 1).

Device preparation. Two models of stent grafts were used: Valiant Captivia (Medtronic, Minneapolis, MN, USA) and Zenith

Alpha Thoracic Endovascular Graft (Cook Medical, Bloomington, USA). The stent grafts were completely unsheathed on a back table without releasing the tip capture mechanism (Fig. 2). The sizing of the graft was based on direct measurements of the ascending aorta: 10–30% oversizing was selected according to available stent graft stock. The stent grafts had 2 fenestrations: 1 proximal large fenestration for the BT and the LCCA with a size laterally 2 mm larger than the BT and LCCA orifices and 1 distal fenestration for the LSA of appropriate size relative to the diameter of the LSA. Distance between both fenestrations was the distance between the LCCA and LSA. The site of the LSA fenestrations was selected such that it was not crossed by stent struts. For the proximal large fenestration, to avoid damage to the prosthesis, the fenestration was created using a size 11 blade. At least 10 mm of fabric seems to be required between the proximal fenestration and the proximal edge of the stent graft to avoid compromising integrity and stability. Using both the sizing measurements undertaken and the authors' previous experience [7], a large fenestration of height 25 mm and width 35 mm was fashioned. A cautery device was used to fashion the LSA fenestration. Thereafter, to mark position and to reinforce seal around the fenestration, a radiopaque nitinol wire (loop of a snare, EV3 Amplatz Goose Neck Snare, Medtronic, Santa Rosa, CA, USA) was sewn onto the edge of the LSA fenestration.

Subsequently, a needle hole was made in the distal part of the stent graft sheath to introduce a 260-cm 0.035 hydrophilic stiff angled guidewire (Terumo, Somerset, NJ, USA). Flushing the sheath helps to introduce the guidewire cephalad inside the endograft through the LSA fenestration (Fig. 2A). Careful attention is needed to avoid twisting the wire inside the sheath. The length of the PGW at each end was adjusted only keeping a short length on the side of the delivery system. The entire graft was then reloaded into the sheath using tourniquets (Fig. 2B). Particular attention is paid to ensure that the PGW does not become embedded within the folds of the constrained endograft during the reloading.

PMSG procedural details

The experimental procedures were performed in a hybrid room (Artis, Zeego, Siemens Healthcare GmbH Erlangen, Germany) (Fig. 1). Aortas were connected to the benchtop closed system pulsatile flow model (Video 1).

A double curved extra stiff wire (Lunderquist; Cook Medical Inc., Bloomington, IN, USA) was inserted into the distal aorta through the 24-Fr distal introducer. The tip of the wire was positioned into the first few centimetres of the proximal Dacron graft, previously sutured to the ascending aorta.

The long part of the hydrophilic angled PGW was introduced from the sheath, with a peelable straightener, and delivered to the LSA using a snare introduced through the LSA (Fig. 3). The PMEG was inserted into the aorta over the extra-stiff wire. Guidewire interlacing is eliminated by rotating the endograft delivery system when its tip is in the mid descending thoracic aorta. When the PMEG is advanced into the arch with the marker on the side of the outer curve of the aortic arch, the PGW emerges from the superior part of the delivery system (towards the outer curve of the aortic arch) (Fig. 3F). This position is mandatory to avoid interlacing and trapping of the PGW. As the stent graft tapered tip crosses the LSA, the PGW is allowed to prolapse into the arch then ascending aorta to allow the PMEG to cross the supra-aortic trunks, eventually positioning the marked small fenestration in front of the LSA (Fig. 3G). As the stent graft is progressively unsheathed under direct fluoroscopic visualization, the second operator progressively pulls the exteriorized PGW through the LSA sheath. This brings the LSA fenestration in direct opposition to the LSA origin. Upon completion of unsheathing of all stents, the 8-Fr sheath with its dilatator is pushed through the LSA fenestration over the PGW before the release of the proximal tip capture. Unlike in live cases, instead of deployment of a

balloon-expandable covered stent in the LSA fenestration, an angioplasty with a 10-mm balloon was performed (Fig. 3K).

The primary end-point was technical success, which was defined as successful deployment of the stent graft and angioplasty of the LSA with the PGW. The secondary end-point was deployment accuracy. Assessment of deployment accuracy of the fenestrations relative to the aortic arch branch ostia was performed by digital subtraction angiography on completion of each procedure (Fig. 3L). Deployment accuracy was defined as the distance between the actual and intended device implantation locations, and supra-aortic trunk patency as assessed by digital subtraction angiography images and by direct visual examination at the end of the procedure (Fig. 4). Partial ostial coverage by the stent graft was also assessed. If the covered part of the stent graft was visualized on the ostium, this was measured, and the percentage of coverage considered as stenosis. Branch stenosis of 30%, in addition to a distance of 4 mm from the end of the most distal branch included in the scallop to the end of the scallop, was considered inaccurate deployment. Attention was paid to the pressure line in the BCT and the LCCA during the procedure; a diminution of 20% of the mean pressure was considered a significant stenosis. In addition, any momentary falls in pressure and their duration were recorded.

Statistical analysis

Categorical data are presented as frequencies; continuous variables are expressed as median and range or standard deviation. All statistical analyses were performed using IBM SPSS Statistics 24 software (version 24.0.0.0).

RESULTS

Macroscopic analysis

During this period, 8 cadaveric aortas were harvested. Anatomical characteristics of the aortas are detailed in Table 1. Aortic wall disease was classified as grade I (non-atherosclerotic; $n=6$), grade II (soft intimal thickening; $n=2$) and grade III (calcified plaques engaging part of the aortic circumference; $n=0$) according to the scoring system of Malina *et al.* [8].


Mean diameter of the aorta in zone 0 was 31.3 ± 3.3 mm. Mean BT, LCCA, and LSA diameters were 13.1 ± 0.9 , 7.7 ± 1.3 and 10.1 ± 1.1 mm, respectively. The mean distance between BT and LCCA edges was 8.1 ± 1.2 mm, and 6.1 ± 0.9 mm between the LCCA and the LSA edges.

Device preparation

Seven stent grafts were modified. The graft diameters ranged from 28 to 40 mm. All stent grafts had the same double fenestration pattern with a preloaded wire. Mean duration for graft modification was 20.1 ± 5.8 min. The stent graft length was 157 mm for 4 aortas and 117 mm for 4 aortas. The mean stent graft diameter was 33.5 ± 4.1 mm.

Primary end-point

PMSG procedural details. Stent graft deployment was successfully completed in all human cadaveric aortas (Fig. 4).



Video 1: The experimentation study is summarized in this video. All steps are detailed in the Fig. 3 legend.

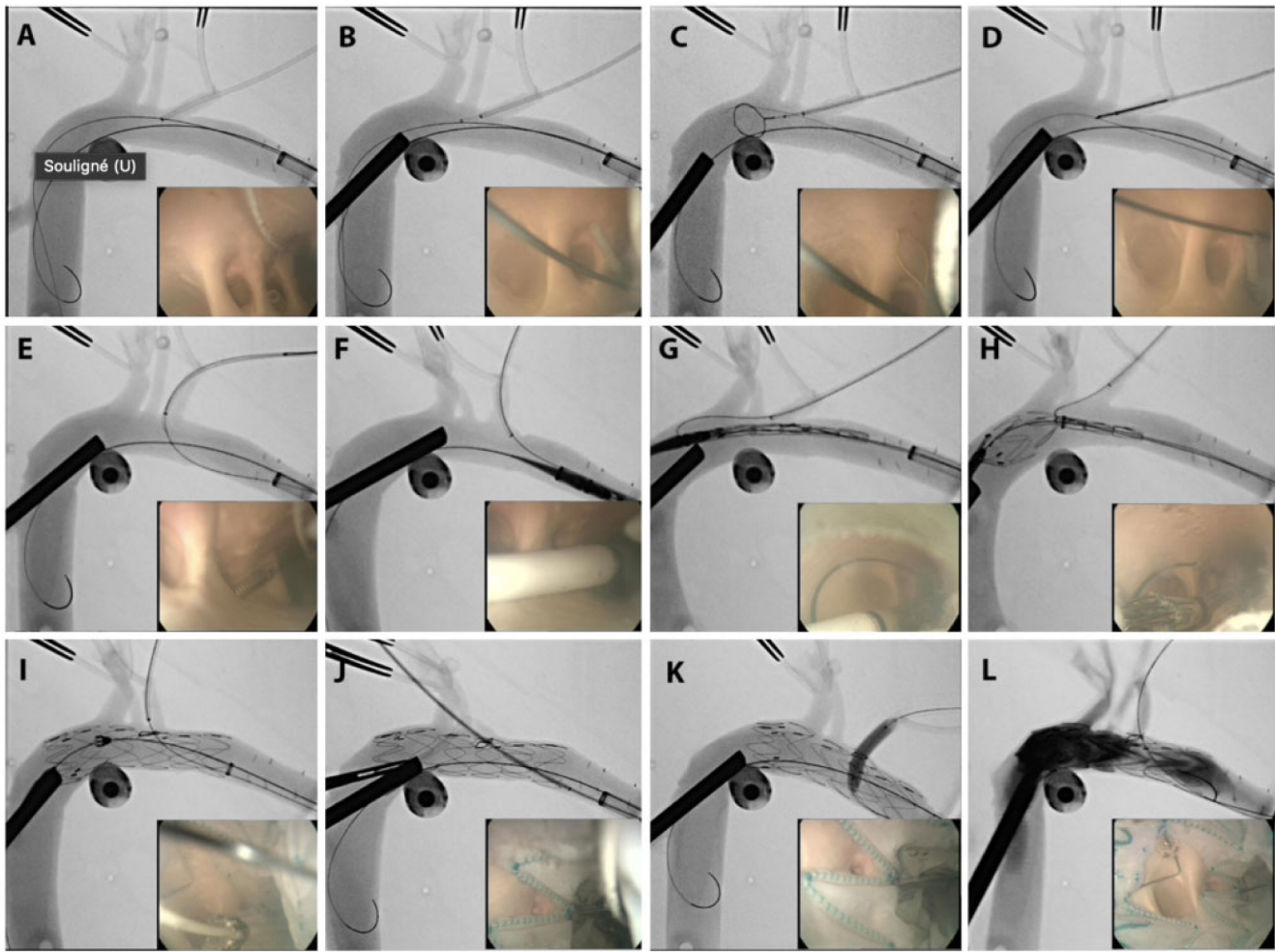


Figure 3: Procedure details as illustrated both by fluoroscopic and intraluminal angiography images. (A) The tips of the preload guidewire and the Lunderquist wire are positioned in the ascending aorta from the Dryseal sheath located in the distal aorta. An 8-Fr sheath is positioned in the left subclavian artery (LSA) ostium. (B) The sheath of a loop snare is advanced through the LSA. (C) The snare loop is opened in the aorta. (D) The preload guidewire is captured by the snare loop. (E) The preload guide wire is pulled back through the 8-Fr LSA sheath. (F) The physician-modified endovascular graft is advanced over the Lunderquist wire by the first surgeon. The second surgeon gently withdraws the preload guidewire. (G) As the stent graft is advanced over the LSA ostium, the second surgeon gently pushes the preload guidewire back to allow the further advancement of the stent graft. Note the LSA fenestration marker in the correct position aligned with the LSA ostium. (H) Stent graft is deployed. During the deployment, the second surgeon gently pulls back the through-and-through wire. (I) Stent graft deployed. (J) The 8-Fr LSA sheath is advanced through the LSA fenestration. (K) The angioplasty balloon secures the LSA fenestration positioning. (L) Angiography and final result. Note the angiography with the brachiocephalic trunk, left common carotid artery and LSA patent.

It was noted that snaring of the PGW was easiest in the arch just in front of LSA as compared to other positions in the ascending or descending aorta. In 100% of cases, the PGW was successfully captured with a mean of 4.5 ± 4.6 min. Twisting of the PGW was always corrected in the descending aorta.

The mean procedure time was 24.5 ± 9.1 min. Formation of the large fenestration effectively de-constrains the stents at this location. During the first implantation, it was noted that the PGW was trapped by the liberated stent. To resolve this, the long sheath was passed from the left subclavian access over the PGW wire and traction was applied. In all cases, accurate placement of the PMEG was observed with successful catheterization of the 8-Fr sheath through the LSA fenestration.

Secondary end-point

Angioscopy examination and direct visualization. Angioscopy and direct visualization confirmed satisfactory

positioning and alignment of the stent graft respecting the orifices of the SATs, in all aortic arch samples. No deterioration of the customized stent graft was identified, and markers did not move during the procedure (Fig. 4). Proximal anchoring was in the expected zone and there were no branch stenoses over 30% after explantation and direct analysis.

Pressure line. No deviations in the BCT pressures line were observed during the procedure. Some momentary reductions in pressure were noted in the LCCA during stent graft deployment, which always self-corrected at the end of the deployment.

DISCUSSION

Technical success was obtained for all double-fenestrated PMEGs for total endovascular aortic arch repair in this experimental model. Double-fenestrated PMEGs with one large fenestration for BT and LCCA and a small for LSA can ensure endovascular

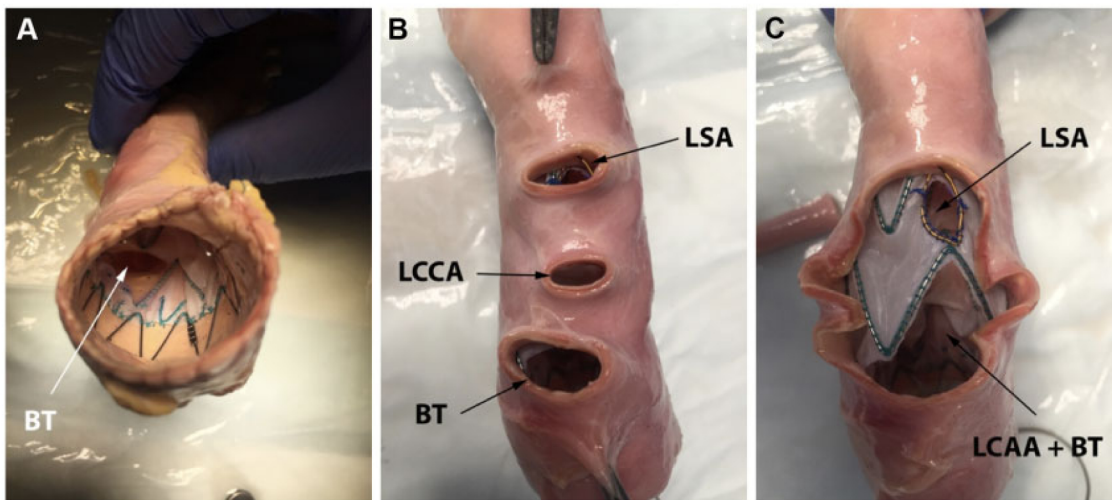


Figure 4: *In situ* post procedure examination. (A) Proximal stent graft is perfectly opposed with the bare stent in the proximal aorta. The BT patent ostium is observed inside the lumen. (B) Image from above the aortic arch with all supra-aortic branch vessels ostium permeable. (C) Same picture after opening the superior wall of the aortic arch to observe the stent graft fenestrations. BT: brachiocephalic trunk; LCCA: left common carotid artery; LSA: left subclavian artery.

treatment of the aortic arch with all SATs patent. The PGW might reduce the technical difficulty of what could be the most challenging step for this procedure, especially in challenging anatomical scenarios. The deployment algorithm actively steers the operator away from superfluous manipulations of the device within the arch and avoids guidewire manipulation in the BT and the LCCA. In this experimental model, the proximal fenestration is designed from direct measurements to perfectly accommodate the 2 proximal SATs. Using angioscopy during the experimental procedure, it was observed that there is early opening of the larger fenestration for the BT, even when the stent graft is partially deployed, allowing continuous flow in the BT during all the procedures. This observation was confirmed by the absence of significant deviations in the intraluminal BT pressure registered with the pressure line. In addition, it seems that the large fenestration decreases the risk of collapse or distal jump of the graft because of the windsock effect. This approach can be performed without rapid pacing with excellent accuracy. Angioscopic assessment confirmed the good apposition of the graft in the aortic arch and the absence of accidental coverage of the SATs.

In the authors' previous reported experience [2, 3], the overall mortality was 0% with all SATs patent and no type I endoleak was observed. When the pre-loaded guidewire is not used in clinical practice, the authors have observed a 9.4% failure of LSA catheterization leading to either carotid axillary bypass and coverage of the LSA fenestration by additional stent graft placement or use of a chimney stent graft as bailout. Misalignment of the stent graft was the cause of these failures. Misalignment can occur in small or tortuous aortas. Catheterization of the LSA can be difficult and stressful for the surgeon. Indeed, manipulations in the aortic arch may be associated with a higher risk of stroke, especially in atherosclerotic aortas. For all those reasons, the authors would now recommend the routine use of a preloaded guidewire even in subjectively non-challenging aortas.

Joseph *et al.* [4] have previously reported on PMEGs with several preloaded wires for total endovascular arch repair. They preloaded 2 fenestrations (LSA and LCCA) and catheterized separately the fenestration for the BT. This method would seem to be difficult to reproduce easily. With the approach used for the present study, the aim was to simplify the technique by using

only one preloaded wire and focusing on only one SAT. Therefore, this supplementary modification added only a few min (1–10 min) to the graft customization compared with the authors' initial clinical experience [2, 3], which could be further improved by a trained team. Despite the simplification of the technique, some technical tips need to be highlighted. Interweaving of the PGW with the Lunderquist wire is easy to deal with in the descending thoracic aorta near the LSA. The authors recommend 2 surgeons with experience in TEVAR to harmoniously coordinate the management of the PGW during the deployment of the stent graft. As the stent graft is progressively deployed, gentle traction in the through-and-through PGW is especially important to avoid trapping of the wire and ensure optimal positioning of the stent graft. In cases of trapping, it is necessary to apply greater traction on the PGW, or to pull the stent graft back and deployed the device in the descending aorta. This last bailout requires that another PMEG is later deployed in the arch.

There are several advantages to the choice of the preloading LSA fenestration: first, the LSA is the SAT contributing least to the cerebral circulation. Second, access is straightforward. Third, the LSA is more frequently involved in diseases of the arch. Some disadvantages exist such as vessel fragility and adverse angulation with the aortic dome, but the authors have not found these latter two considerations to be problematic because the PGW was exteriorized via a long sheath and the systematic use of a covered stent. Therefore, the LSA angulation is not a significant issue when using a snare and through-and-through guidewire. Another advantage of the technique described is that only 2 vascular access points are needed (femoral artery and left brachial artery) without additional surgical procedures like debranching of SATs, such that this technique is a truly minimally invasive approach for total endovascular aortic arch repair.

The study authors' institution has a large experience with complex thoracic endovascular repairs, which includes significant experience with homemade stent grafts [9]. The risk of technical failure with this approach may be increased if performed by inexperienced teams.

There are anatomic considerations for this technique. Zone 0 aortic arch lesions, except saccular aneurysms at the lesser

Table 1: Anatomic description of the cadaveric aortas and stent-grafts used

Sex	Age	Aorta ^a	Diameter (mm)						Length (mm)			Graft
			AA	Z0	Z1	Z2	Z3	Z4	LSA-LCCA	TSA	Total length	
F	49	1	34	28	27	24	24	22	8	34	250	Medtronic 30 × 157
M	56	1	35	32	28	28	28	28	6	35	240	Medtronic 34 × 157
M	53	1	37	36	32	31	28	25	5	35	250	Medtronic 34 × 157
M	58	2	40	32	30	26	26	26	7	37	240	Medtronic 38 × 117
M	x	1	40	35	35	31	31	31	5	37	220	Medtronic 40 × 117
M	53	2	39	32	30	31	28	26	6	35	260	Cook 34 × 117
M	49	1	26	26	25	24	24	22	6	32	220	Cook 28 × 117
F	62	1	35	30	31	28	28	28	6	35	220	Medtronic 30 × 157

^aMacroscopic classification of the cadaveric aortic wall.
AA: ascending aorta; F: female; LSA-LCCA: distance between left subclavian artery and left common carotid artery; M: male; Z: Ishimaru's classification.

curvature of the arch, are considered unsuitable because the size of the proximal fenestration would be proximally and laterally larger than the size of the BT and LCCA orifice, increasing the risk of endoleak. These aneurysms could be treated using a branched stent graft. The diameter of zone 1 must not be over 40 mm, to avoid retrograde dissection and endoleak. Several different alternatives allow zone 0 TEVAR. The hybrid procedure with debranching of supra-aortic branch vessels is a proven technique but with an important risk of death between 9% and 11% and of stroke between 5% and 12% [10–11].

There are currently 2 custom-made branched arch devices available in Europe both allowing a wider group of anatomies to be treated [2]. A 13% mortality, 16% stroke, 15.8% technical failure and 19.6% secondary procedure rate were reported in the initial world experience [12]. More recently, a study [13] with the Relay using 2 parallel inner branches (Bolton Medical, Barcelona, Spain) demonstrated 7% mortality and 7% disabling stroke rate. These results reflect the technical difficulty of side branch catheterization and the learning curve even in the hands of highly skilled practitioners and experienced units. Recently, Tsilimparis *et al.* [14] described 44 cases (12 of which zone 0) of fenestrated endovascular repair of the aortic arch with a rate of major stroke of 7%, 30-day mortality of 9% and a high technical success rate (95%).

Other factors such as the delay in device planning and manufacturing (1–3 months), anatomical and technical limitations and, furthermore, cost limit the widespread uptake of these technologies which is additionally unsuitable for emergent cases.

The fragility of homemade stent grafts is a crucial concern. Evaluation of fabric durability is ongoing. Modification of commercially available devices by physicians may void any guarantee of safety by the manufacturer, and systematic evaluation of such devices is better done within a protocol approved at the institutional and/or regulatory level. More data are required to confirm the applicability of this approach and to establish durability. The authors continue to report their results and update their registry. To date, no malfunction or rapid deterioration has been observed.

In this experimental study, we used the Medtronic and Cook stent grafts. Other devices could be used for the same approach, namely, the Bolton (Bolton Medical, Sunrise, FL, USA). The deployment system of the Gore device (WL Gore & Associates, Inc., Flagstaff, AZ, USA) prevents reloading of the stent graft into the sheath, thereby prohibiting the use of this technique.

Limitations

This was an experimental study and the PMEGs were deployed in non-pathological aortic arches with direct measurements. However, we already have clinical outcomes for double-fenestrated stent grafts for total arch repair in pathological aortas [2] and this experimental study confirms the precision of a supplemental technique to improve further the accuracy of deployment. Moreover, recreating pathological anatomical conditions for this type of study is challenging. The small numbers are explained by the difficulties in obtaining fresh cadaveric aorta and limited access to the hybrid room. Even within this small number, we observed a quick learning curve. This technique will be clinically assessed on pathological aortic arches.

CONCLUSIONS

The use of PMEGs with double fenestration for zone 0 TEVAR using a preloaded guidewire through the LSA fenestration is a feasible and novel technique that allows a simplification of endovascular aortic arch repair. The preloaded guidewire ensures the catheterization of the LSA fenestration and facilitates the positioning of the PMG in the aortic arch to achieve the proper alignment between the stent graft fenestrations and the aortic arch branch vessels. This technique could be used in selected cases of aortic arch disease.

Conflict of interest: Ludovic Canaud and Thomas Gandet are proctors for Medtronic.

Author contributions

Youcef Lounes: Conceptualization; Data curation; Funding acquisition; Investigation; Methodology; Project administration; Writing—original draft. **Lucien Chassin-Trubert:** Conceptualization; Data curation; Formal analysis; Funding acquisition. **Thomas Gandet:** Methodology; Validation; Visualization. **Baris Ata Ozdemir:** Visualization; Writing—review & editing. **Antoine Peyron:** Data curation; Formal analysis; Funding acquisition. **Mariam Akodad:** Writing—original draft; Writing—review & editing. **Pierre Alric:** Methodology; Validation. **Ludovic Canaud:** Conceptualization; Resources; Supervision; Validation; Visualization; Writing—original draft.

Reviewer information

Interactive CardioVascular and Thoracic Surgery thanks Luca Bertoglio, Mario Giovanni Gerardo D’Oria and Massimiliano M. Marrocco-Trischitta for their contribution to the peer-review process of this article.

REFERENCES

[1] Maurel B, Mastracci TM, Spear R, Hertault A, Azzaoui R, Sobocinski J *et al.* Branched and fenestrated options to treat aortic arch aneurysms. J Cardiovasc Surg (Torino) 2016;57:686–97.

[2] Canaud L, Ozdemir BA, Chassin-Trubert L, Sfeir J, Alric P, Gandet T. Double homemade fenestrated stent-graft for total endovascular aortic arch repair. J Vasc Surg 2019;70:1031–8.

[3] Canaud L, Ozdemir BA, Chassin-Trubert L, Sfeir J, Alric P, Gandet T. Homemade fenestrated stent-grafts for complete endovascular repair of aortic arch dissections. J Endovasc Ther 2019;26:645–51.

[4] Joseph G, Premkumar P, Thomson V, Varghese M, Selvaraj D, Sahajanandan R. Externalized guidewires to facilitate fenestrated endograft deployment in the aortic arch. J Endovasc Ther 2016;23:160–71.

[5] Canaud L, Alric P, Desgranges P, Marzelle J, Marty-Ané C, Becquemin J-P. Factors favoring stent-graft collapse after thoracic endovascular aortic repair. J Thorac Cardiovasc Surg 2010;139:1153–7.

[6] Canaud L, Cathala P, Joyeux F, Branchereau P, Marty-Ané C, Alric P. Improvement in conformability of the latest generation of thoracic stent-grafts. J Vasc Surg 2013;57:1084–9.

[7] Chassin-Trubert L, Gandet T, Ozdemir BA, Lounes Y, Alric P, Canaud L. Aortic arch anatomy pattern in patients treated using double homemade fenestrated stent-grafts for total endovascular aortic arch repair. J Endovasc Ther 2020;27:785–91.

[8] Malina M, Lindblad B, Ivancev K, Lindh M, Malina J, Brunkwall J. Endovascular AAA exclusion: will stents with hooks and barbs prevent stent-graft migration? J Endovasc Ther 1998;5:310–7.

[9] Canaud L, Gandet T, Khantalín I, Ozdemir BA, Marty-Ané C-H, Alric P. Homemade proximal scalloped stent-graft for thoracic endovascular aortic repair of zone 2 acute aortic syndrome. J Thorac Cardiovasc Surg 2016;152:1301–6.

[10] Cao P, De Rango P, Czerny M, Evangelista A, Fattori R, Nienaber C *et al.* Systematic review of clinical outcomes in hybrid procedures for aortic arch dissections and other arch diseases. J Thorac Cardiovasc Surg 2012; 144:1286–300, 1300.e1–2.

[11] Benedetto U, Melina G, Angeloni E, Codispoti M, Sinatra R. Current results of open total arch replacement versus hybrid thoracic endovascular aortic repair for aortic arch aneurysm: a meta-analysis of comparative studies. J Thorac Cardiovasc Surg 2013;145:305–6.

[12] Haulon S, Greenberg RK, Spear R, Eagleton M, Abraham C, Lioupis C *et al.* Global experience with an inner branched arch endograft. J Thorac Cardiovasc Surg 2014;148:1709–16.

[13] Czerny M, Ryłski B, Morlock J, Schröfel H, Beyersdorf F, Saint Lebes B *et al.* Orthotopic branched endovascular aortic arch repair in patients who cannot undergo classical surgery. Eur J Cardiothorac Surg 2018;53:1007–12.

[14] Tsilimparis N, Law Y, Rohlfes F, Spanos K, Debus ES, Kölbel T. Fenestrated endovascular repair for diseases involving the aortic arch. J Vasc Surg 2020;71:1464–71.