



Surgical treatment of hypothalamic hamartomas

Pierre Bourdillon, S. Ferrand-Sorbet, C. Apra, M. Chipaux, E. Raffo, S. Rosenberg, C. Bulteau, N. Dorison, O. Bekaert, V. Dinkelacker, et al.

► To cite this version:

Pierre Bourdillon, S. Ferrand-Sorbet, C. Apra, M. Chipaux, E. Raffo, et al.. Surgical treatment of hypothalamic hamartomas. *Neurosurgical Review*, 2021, 44 (2), pp.753-762. 10.1007/s10143-020-01298-z . hal-03265578

HAL Id: hal-03265578

<https://hal.sorbonne-universite.fr/hal-03265578>

Submitted on 21 Jun 2021

HAL is a multi-disciplinary open access archive for the deposit and dissemination of scientific research documents, whether they are published or not. The documents may come from teaching and research institutions in France or abroad, or from public or private research centers.

L'archive ouverte pluridisciplinaire **HAL**, est destinée au dépôt et à la diffusion de documents scientifiques de niveau recherche, publiés ou non, émanant des établissements d'enseignement et de recherche français ou étrangers, des laboratoires publics ou privés.

Surgical treatment of hypothalamic hamartomas

P. Bourdillon^{1,2,3,4*}, S. Ferrand-Sorbet^{2*}, C. Apra^{3,4,5}, M. Chipaux², E. Raffo^{2,6}, S. Rosenberg², C. Bulteau^{2,7}, N. Dorison², O. Bekaert², V. Dinkelacker⁸, C. Le Guérinel¹, M. Fohlen², G. Dorfmueller²

1. Department of neurosurgery, Adolphe de Rothschild Foundation, Paris, France.
2. Department of pediatric neurosurgery, Adolphe de Rothschild Foundation, Paris, France.
3. Sorbonne Université, Paris, France.
4. Brain and Spine Institute, INSERM U1127, CNRS, UMR7225, Paris, France.
5. Department of neurosurgery, Pitié-Salpêtrière Hospital, Paris, France.
6. Université de Lorraine, Nancy, France.
7. Université de Paris, Paris, France
8. Department of neurology, Adolphe de Rothschild Foundation, Paris, France.

* These authors equally contributed to this work

Keywords: epilepsy; gelastic ; LiTT ; laser ; radiofrequency ; coagulation ; disconnection ; stereotactic

Sources of financial and material support: No specific funding was received for this work. None of the authors declare disclosure

Corresponding author:

Pierre Bourdillon

Department of Neurosurgery, Fondation Adolphe de Rothschild , 29 Rue Manin, 75019, Paris, France

Phone: (+33) 1 48 03 65 65

pierre.bourdillon@neurochirurgie.fr

Abstract

Hypothalamic hamartomas are aberrant masses, composed of abnormally distributed neurons and glia. Along endocrine and cognitive symptoms, they may cause epileptic seizures, including the specific gelastic and dacrystic seizures. Surgery is the treatment of drug resistant hamartoma epilepsy, with associated positive results on endocrine, psychiatric and cognitive symptoms. Recently, alternatives to open microsurgical treatment have been proposed. We review these techniques and compare their efficacy and safety.

Open resection or disconnection of the hamartoma, either through pterional, transcallosal or transventricular approach, leads to good epileptological control but its high complication rate, up to 30%, limits its indications. The purely cisternal peduncular forms remain the only indication of open, pterional, approach, while other strategies have been developed to overcome the neurological, endocrine, behavioral or cognitive complications.

Laser and radiofrequency thermo-coagulation based disconnection through robot-guided stereo-endoscopy has been proposed as an alternative to open microsurgical resection and stereotactic destruction. The goal is to allow safe and complete disconnection of a possibly complex attachment zone, through a single intraparenchymal trajectory which allows multiple laser or radiofrequency probe trajectory inside the ventricle. The efficacy was high, with 78% of favorable outcome, and the overall complication rate was 8%. It was especially effective in patients with isolated gelastic seizures and pure intraventricular hamartomas.

Stereotactic radiosurgery has proved as efficacious and safer than open microsurgery, with around 60% of seizure control and a very low complication rate. Multiple stereotactic thermo-coagulation showed very interesting results with 71% of seizure freedom and 2% of permanent complications. Stereotactic laser interstitial thermotherapy (LiTT) seems as effective as open microsurgery (from 76% to 81% of seizure freedom) but causes up to 20% of permanent complications. This technique has however been highly improved by targeting only the epileptogenic onset zone in the hamartoma, as shown on preoperative functional MRI, leading to an improvement of epilepsy control by 45% (92% of seizure freedom) with no postoperative morbidity.

All these results suggest that the impact of the surgical procedure does not depend on purely technical matters (laser vs radiofrequency thermo-coagulation or stereotactic vs robot-guided stereo-endoscopy) but relies on the understanding of the epileptic network, including inside the

hamartoma, the aim being to plan an effective disconnection or lesion of the epileptogenic part while sparing the adjacent functional structures.

1
2
3
4
5
6
7
8
9
10
11
12
13
14
15
16
17
18
19
20
21
22
23
24
25
26
27
28
29
30
31
32
33
34
35
36
37
38
39
40
41
42
43
44
45
46
47
48
49
50
51
52
53
54
55
56
57
58
59
60
61
62
63
64
65

Introduction

Hypothalamic hamartomas (from ἀμαρτία, sin) are rare heterotopic masses resulting from an aberrant development of normal tissue that arise from the ventral hypothalamus⁴⁰. They are composed of abnormally distributed but cytologically normal neurons and glia, including fibrillary astrocytes and oligodendrocytes^{19,46}. Hypothalamic hamartomas can be isolated, associated with other brain lesions, or be part of malformative disorders, for instance the Pallister-Hall syndrome, a genetic disease caused by GLI3 frameshift mutations³⁸. These developmental malformations can be diagnosed incidentally¹⁶ or during investigation of neurological, psychiatric or endocrine disturbances⁴⁶ according to their anatomical location. When the lesion is in contact with the infundibulum or with the tuber cinereum, endocrine signs are frequently present, especially precocious puberty¹⁷. Epilepsy and behavioral or cognitive disorders are associated with hypothalamic hamartomas connected with the mamillary bodies^{55,76}. Epilepsy usually starts during the first year of life with the classical gelastic seizures⁴⁶ (from γέλως, laugh) or less frequently dacrytic (from δάκρυ, tear) seizures¹². These very specific seizures have first been reported during the late XIXth century by Armand Trousseau⁷⁵ as an “irrepressible pulsion to laugh”. The term “gelastic” was introduced in 1957²¹, and description of gelastic attacks defined in 1971 as “characterized by repeated short-lasting seizures with initial emotionless laughter or grimacing”^{30,46}. These seizures are difficult to identify as the symptoms can easily been misinterpreted and the diagnosis if often delayed when the child develops other types of seizures³² such as drop attacks, generalized tonic-clonic seizures, complex partial seizures, frequently associated with psychiatric disorders or cognitive impairment^{5,28,56}. This evolution strongly suggests a secondary epileptogenesis that involves mainly frontal and temporal structures, strongly connected with hypothalamic region^{29,49}. Since the first clinical description of a positive effect of hamartoma surgery on epilepsy⁵³, many evidence of the implication of the lesion in the epileptic network have been provided in stereoelectroencephalography (SEEG)^{35,36,50}. Beyond the strong evidence for the intrinsic epileptogenesis of the hamartomas strengthened by metabolic neuroimaging studies^{41,66}, non-gelastic seizures may indicate an implication of temporal and frontal regions in the epileptic network⁶⁷. These seizures can be independent from discharges from the hypothalamic hamartoma itself³². Alongside the description of the multiple aspects of the epileptic networks in hypothalamic hamartomas related epilepsy, many surgical techniques have been developed, including open, endoscopic and stereotactic techniques making it uneasy to have a clear overview of the available therapeutic possibilities.

We conducted a narrative review of the surgical treatments of hypothalamic hamartomas by conducting a Pubmed/MEDLINE literature search up to November 2019 with the terms: 'hypothalamic hamartoma', AND 'epilepsy', 'seizure', 'gelastic', 'precocious puberty', 'secondary epileptogenesis', 'epileptic network'. We selected original papers with patients data based on their importance in the field.

Focusing on the hamartoma

Hypothalamic hamartomas have a non-complex microarchitecture with many nodular groups of neurons of which 80% have an interneuron-like phenotype and express glutamic acid decarboxylase¹⁹. These neurons utilizing γ -aminobutyric acid as primary neurotransmitter have membrane features that make them have a spontaneous pacemaker-like firing activity. These predominant population of firing neurons is associated to large pleomorphic pyramidal neurons appearing to be excitatory projection having the functionally immature behavior of depolarizing and firing in response to GABA ligands⁴⁰. These characteristics fit well with the hypothesis of a key role of hypothalamic hamartomas in the ictogenesis and the triggering of seizures that spread to a larger and diffuse epileptic network. This hypothesis has been strengthened by SEEG data^{35,36,50}, and justifies the surgical development targeting directly the hypothalamic hamartoma.

However, hypothalamic hamartomas have also been considered as a model of human secondary epileptogenesis⁶⁷ at least for the two first stages according to the Morrel models : epileptiform discharges detected in the secondary focus were driven by the primary focus, whose destruction resulted in immediate cessation of epileptogenic discharges (first stage) ; independent seizures and interictal epileptiform discharges detected in the secondary focus that initially persist after removal of the primary focus, but eventually disappeared spontaneously later (second stage)⁷⁷. This secondary epileptogenesis justifies an early surgical treatment of hypothalamic hamartoma related epilepsy and fits with the better seizure control reported in literature when surgery is precocious in the natural history of the disease^{26,37}. Recent data suggested that the third stage, corresponding to a persistent long-term epileptiform activity in the secondary epileptogenic area after removal of the primary focus, may occur in hypothalamic hamartoma related epilepsy⁶⁷. Consequently, phase I investigation suggesting a cingulate, a frontal or a

temporal independent network should make consider, especially in case of long medical history of epilepsy, to additionally and actively look for another ictal onset zone^{29,49,67}.

Independently from epilepsy, hypothalamic hamartomas have endocrine comorbidities^{31,46}, the most common and frequently the only one being central precocious puberty. The main, but still unproven, physiopathology hypothesis is an ectopic generation and pulsatile release of gonadotropin-releasing hormone. This hypothesis relies on the possible production in the hypothalamic hamartoma of gonadotropin-releasing hormone regulators as transforming growth factor α and γ -aminobutyric acid³¹. This hypothesis is strengthened by the reported efficiency of hypothalamic hamartoma resection to treat central precocious puberty⁴⁷. Nevertheless, since GnRH agonists are widely available and effective, surgery should not be any more considered to treat isolated endocrine disturbances caused by hypothalamic hamartomas. That is why this review will focus on the epileptic control as objective of surgical treatment.

Surgical techniques

Several surgical classifications have been proposed to orientate the best surgical approach and to predict the functional and epileptic outcome after the surgery. The original classification of 1991 distinguishing the peduncular from the sessile hypothalamic hamartomas¹¹ was refined in two sub categories each by Valdueza (1a and 1b for peduncular and 2a and 2b for sessile hamartomas)⁷⁶. Arita proposed a close classification that separates the parahypothalamic (usually the peduncular ones) from the intrahypothalamic (usually the sessile ones) hypothalamic hamartomas³. More complex classifications have been proposed, especially by Regis⁶⁰ and Shim⁷⁰, but Delalande's classification into four subtypes²² remains the most used⁴⁶ (Figure 1). Type I are small peduncular lesions characterized by an horizontal plane of attachment to the tuber cinereum ; Type II are mainly intraventricular lesions having a vertical plane of insertion ; Type III lesions are a combination of Types I and II having both an horizontal and a vertical insertion plane ; Type IV lesions are generally very large tumors with broad attachment to both the mammillary bodies and the hypothalamus and have an extension into the interpeduncular cistern.

Open disconnection and resection surgery

Since the first description of a surgical treatment of an hypothalamic hamartoma in 1969⁵³, the discussion has been dominated by the opposition between two micro-neurosurgical techniques: one aiming to reach the lesion from below (pterional and transtemporal-transchoroidal approaches), versus another aiming to reach the lesion from above (transcallosal and transventricular)^{7,46,64}. Whatever the technique (Figure 2), the possibility of complete removal is correlated to the importance of the attachment to the mamillary bodies (neuropsychological risk) and to the tuber cinereum (endocrine risk)⁶².

The pterional approach is the shortest and most direct route to the suprasellar cistern but the access to the third ventricle and the intraventricular component of the hypothalamic hamartoma is limited by the narrowness of the surgical corridor constituted by the carotid artery, optic nerve and chiasm, third cranial nerve, and infundibulum⁴⁷. Although the reported seizure control is higher than 90% in some series, the morbidity is important, including transient third nerve palsy, thalamo-capsular infarcts, postoperative central diabetes insipidus, and hyperphagia.⁴⁷ These limits lead to the development of alternative surgical approaches reaching the lesion from above^{7,46,64}. This technique was associated with good resection results for intraventricular lesions (Delalande Type II and IV) but remained limited in case of cisternal expansion of the lesion. In the review by Mittal and al. The complication rate reported was still high, the risk of memory impairment was increased⁴⁷. Although new technologic advances have been used, including per-operative MRI, and succeeded in increasing the seizure free rate above 80%, the complication rate remains high, greater than 30%⁷⁸. Concomitantly and with the similar objective to reach the lesion from above, a transcallosal transeptal interfornical approach has been introduced in 2001⁶³ offering a wide exposition of the hypothalamic hamartoma. While the risk of cerebral infarction and oculomotor nerve palsy is reduced by avoiding manipulation of the vessels in the suprasellar and interpeduncular cistern, as well as the risk of injury to the mammillary bodies, pituitary stalk, the inherent risk is a fornical damage causing memory deficit^{48,52}. Three large series totalizing 92 patients have been reported. Seizure frequency reduction was achieved in more than 90% and seizure freedom in between 50 to 55% of them. The most common complications were thalamic infarction and memory impairment (which was permanent in less than 10% of patients) but were counterbalanced by both cognitive and behavioral improvements (respectively 88% and 60% of patients). A correlation between completeness of excision of the hypothalamic hamartoma and seizure freedom have been demonstrated. Interestingly the memory impairment was higher in older patient, possibly as a

consequence from forniceal injury because the leaves of the septum pellucidum are not as easily separated^{47,52,78,83}. In this context endoscopic approach has been introduced by Akai in 2002 and then popularized by the Barrow Neurological Institute group from ~~2006~~²⁰⁰⁶⁴⁵. Between 48% and 58% of patients of the two largest published series were seizure free^{18,51} but major complications remain high⁵¹ in one of them. To overcome this issue, the Cappabianca group proposed through a comprehensive review¹⁴ to limit the endoscopic resection to the small hypothalamic hamartoma with a unilateral attachment to the hypothalamic wall with at least 6 mm between the top of the lesion and the roof of the third ventricle.

Stereotactic radiosurgery

Stereotactic radiosurgery by Gamma Knife as a treatment of hypothalamic hamartomas was first reported in 1998 for a single young patient having a long history of hypothalamic hamartoma related drug resistant epilepsy⁴. The encouraging functional results of the treatment have been promptly followed by a series reported by Regis⁵⁷ and a prospective multicentric study in which 25Gy was delivered to the 50% isodose line⁵⁸. Despite the usual delayed action of the radiosurgery, the results were very promising as only a minor complication happened (5 months long hyperthermia) and 26% of patients were seizure free. The median number of seizures per month was reduce from 6.2 to 0.3. The median marginal dose was 17Gy (range, 14 to 20). The long-term outcome on the study, in which 60 patients were enrolled, was published in 2006 and reported 31 patients with a minimum of three years follow up after the radiosurgery. The marginal isodose was 17Gy(range, 13 to 26) and beam blocking strategies was used to minimize the dose delivered to the frail structures surrounding the hypothalamic hamartoma (mammillary bodies, fornices, visual pathways, tuber cinereum and pituitary stalk)⁶⁰. None of the patients presented permanent complications but 15% of them experienced a temporary worsening of seizures. 37% of patients were seizure free and another 22% had a significant reduction of seizures frequency. The best result was obtained in a patient having a small type II hypothalamic hamartoma.

Among the increasing literature evaluating radiosurgery since this first promising studies^{1,15,43,59-61}, two level 2 prospective studies reported respectively 60%⁶⁰ and 66%⁴³ of seizure control following radiosurgery. Furthermore, a progressive positive effect on behavior during the 6 following months, co-occurring with sleep patterns and EEG normalization was described⁶¹. No major adverse event was reported, especially concerning the endocrine function¹⁵, except transient seizure control worsening and poikilothermia. More recently, these results

were strengthened by the publication of long term follow up of the study from the Marseille group⁵⁹. Among the 57 patients investigated, 48 had a more than 3 years follow-up with a median follow-up of 71 months (range, 36 to 153). According to Delalande's classification, a single patient had a type I hypothalamic hamartoma, 26 a type II, 18 a type III and 3 a type IV. The median marginal dose was 17 Gy (range, 14 to 25) and the median target volume was 398 mm³ (range, 28 to 1600 mm³). 28 patients (58.3%) required a second treatment due to partial results. The rate of Engel class I outcome was 39.6%, Engel class II was 29.2%, and Engel class III was 20%. This result was associated with a cure of psychiatric comorbidity in 28% of patients, an improvement in 56%, a stable disease in 8% and a worsening in 8%. No permanent neurological side effect was reported especially with regard to memory deficit. 16.6% had a transient increase of the seizures frequency and transient poikilothermia was observed in 6.2%. 14.5% required an additional open microsurgical treatment due to an insufficient efficacy.

The high level of endocrine safety of Gamma Knife radiosurgery has specifically been studied and reported a complication in only 1 of 34 treated patients (thyrotropin-stimulating hormone deficiency 2 years after the procedure)¹⁵.

These results, when compared to equivalent studies related to surgical approaches⁴⁶, indicate comparable or better results for radiosurgery, with a reduced rate of adverse effects^{7,44}. Nevertheless, no comparison has been conducted with the endoscopic or stereotactic approach recently developed to overcome the open microsurgery limits.

Stereotactic laser interstitial thermotherapy

Laser interstitial thermotherapy (LiTT) consists in stereotactic placement of a laser probe through which a thermal lesion can be performed (Figure 3). The technique has initially been introduced in neuro-oncology as an alternative to open surgery^{45,69} but has been adapted to epilepsy surgery as early as 1978^{33,39}. Commercialization of LiTT coupled to MRI monitoring through the Visualase®⁸¹ and the NeuroBlate®⁸⁰ system causes a growing interest for the technique and the multiplication of the publication of series.

As the technique requires a small diameter trephination through a tiny skin incision and a short stay at hospital, the technique is frequently presented as a minimally invasive technique. However, the complication rate in literature review, 3.4% of severe complications and 23.5% of overall complications³⁴, does not differ from the reported rate in open epilepsy surgery⁶⁵.

1 The recent introduction of this technique makes possible that this complication rate could be
2 the result of a learning curve and could be expected to decrease in time. In the context of a high
3 potential of this technique in epilepsy surgery, specific series on hypothalamic hamartomas
4 have been published (Figure 4).
5
6

7 The University of California in San Francisco group introduced the technique and reported a
8 seizure free rate of 60% associated to 20% of adverse effects on a series of 5 patients⁷³. A first
9 large literature review⁸¹ on 22 procedures with a mean follow-up of 17.4 months revealed that
10 80% of patients having gelastic seizures were seizure free after treatment and 56% of other
11 patients had the same results. Immediate complication rate was 39% and 22% of patients had a
12 permanent deficit, including hypothyroidism, short-term memory loss and weight gain. More
13 recently, very experienced teams started publishing their results on large single center series.
14 The series of the Texas Children's Hospital reported 71 patients. Among patients having more
15 than one year follow-up, 78% were free of gelastic seizures and 12% were seizure free. 20% of
16 patients needed a repeated treatment. The complication rate was 5.4%²⁰. The Northwell
17 Hospital group in New York reported a series of 8 patients and obtained a seizure free rate of
18 75% and a permanent complication rate of 12.5%²⁴.
19
20

21 Interestingly, the Barrow Neurological Institute group at Phoenix Children's Hospital
22 developed a strategy going further than anatomical targeting for the LiTT in hypothalamic
23 hamartomas (Figure 4)⁶. Although all neurons within the lesion are abnormal, some of them do
24 not communicate outside of the hypothalamic hamartoma, so it was suggested that a lesioning
25 of the whole hypothalamic hamartoma may be unnecessary. In addition to the anatomical
26 localization of the lesion, data obtained by functional fMRI were taken into account. These data
27 corresponded to the whole-brain functional connectivity of every individual hypothalamic
28 hamartoma voxel. Images that showed connectivity between the hypothalamic hamartoma and
29 any portion of the rest of the brain were considered as a part of the epileptic network.
30 Subcentimeter targets obtained by resting state fMRI were then defined. The results of this
31 approach have been reported through a 51 patients controlled study including 15 control
32 patients and 36 patients undergoing the above described procedure. Results were significantly
33 better in the fMRI targeted group (overall seizure reduction 85%, Engel I 92%) than in the
34 control group (overall seizure reduction 49%, Engel I 45%). No postoperative morbidity or
35 mortality occurred in the fMRI targeted group.
36
37
38
39
40
41
42
43
44
45
46
47
48
49
50
51
52
53
54
55
56
57
58
59
60
61
62
63
64
65

1 This approach improved freedom from seizures by 45% compared to conventional ablation,
2 regardless of hamartoma size, and reduced morbidity compared to other recent studies which
3 reach 20% permanent significant morbidity.
4
5
6
7

8 *Stereotactic radiofrequency coagulation* 9

10 Stereotactic radiofrequency thermocoagulation in epilepsy surgery has been introduced during
11 the second half of the XXth century⁶⁸ originally for the treatment of temporal lobe epilepsy. The
12 extension of this technique to the specific indication of hypothalamic hamartomas is more
13 recent^{37,42,54}.
14
15
16
17

18 The most important contribution in this area comes from the Nishi-Niigata group in Japan³⁷
19 who reported 140 consecutive procedures of MRI-guided stereotactic radiofrequency
20 thermocoagulation for hypothalamic hamartomas over 100 patients (Figure 4). The median
21 follow-up was 3 years (range, 1 to 17) and only 10% of patients had pure gelastic seizures. 86%
22 of patients were free of gelastic seizures and the overall seizure freedom rate was 71%. This
23 result was obtained with a median of 4 trajectories (range, 1 to 10) and 6 lesions (range, 1-36)
24 per procedure. Permanent endocrine deficit concerned 2% of patients and required replacement
25 therapy for hypocortisolism, hypothyroidism or diabetes insipidus. The rate of transient
26 complications was high with 60.0% of Horner's syndrome, 27.9% of hyperphagia, 22.1% of
27 hyponatremia, 22.1% of hyperthermia, 8.6% of short-term memory disturbance, 0.7% of
28 disturbance of consciousness. 32% of patients required multiple procedures. It is worth noticing
29 that the cognitive outcome has been specifically studied and was improved after stereotactic
30 radiofrequency coagulation of the hamartoma⁷². Similar results were reported in 2003 in a series
31 of 12 children⁴² (but 6 patients underwent simultaneously an endoscopic treatment making the
32 results hardly comparable) and in a series of 5 patients⁷⁴.
33
34
35
36
37
38
39
40
41
42
43
44
45
46

47 More recently and similarly to the functional connectivity approach developed for the super-
48 selective LiTT treatment⁶, SEEG-guided radiofrequency-thermocoagulation (SEEG-guided
49 RF-TC) has been proposed for the hypothalamic hamartoma treatment⁷⁹. SEEG-guided RF-TC
50 consists of coupling SEEG investigation with RF-TC stereotactic lesioning directly through the
51 recording electrodes¹⁰ and is valuable in epilepsy surgery⁹, especially to treat periventricular
52 nodular heterotopia⁸, a pathology sharing a lot of similarities with hypothalamic hamartoma.
53 Over a series of 9 patients, results were in the same range than conventional stereotactic
54 radiofrequency coagulation⁷⁹. However, such an indication requires to be carefully justified, as
55
56
57
58
59
60
61
62
63
64
65

1 phase II investigations can be unnecessary to investigate hypothalamic hamartoma related
2 seizures.
3
4
5

6 *Endoscopic laser and radiofrequency coagulation treatment*

7
8
9 Robot assisted endoscopy to perform hypothalamic hamartomas disconnection as an alternative
10 to the microsurgical removal and stereotactic destruction of the lesions was introduced in 2003
11 by Delalande^{22,27}. Surgical excision of the lesion has indeed no interest from an oncological
12 point of view and a disconnection, except for type I hypothalamic hamartoma, can be achieved
13 less invasively by an endoscopic trans-ventricular approach²³. Stereotactic lesions, either by
14 LiTT or RF-TC, are also less invasive than open microsurgical technique but a probe can only
15 produce a spherical or an oblong lesion. Hypothalamic hamartomas are not always a perfect fit
16 with this volume and the attachment to the functional adjacent hypothalamic structure is usually
17 planar. It could be difficult to obtain a safe and complete disconnection of such planar insertion
18 by performing a curved lesion with a single trajectory. That is why multiple probe stereotactic
19 placement have been proposed⁷¹. To overcome the necessity to perform multiple stereotactic
20 trajectory, the endoscopic robot assisted approach, allow to perform a single intraparenchymal
21 trajectory, known to be functionally safe, and to perform multiple intraventricular placements
22 of a RF-TC²² or laser¹³ probe. Such flexibility in probe placement make it possible to perform
23 multiple small volume lesions of the attachment plan of the hamartoma, which make
24 conceptually this technique safer regarding the function of the adjacent structure (Figure 4,
25 Video 1 & 2).
26
27
28
29
30
31
32
33
34
35
36
37
38
39
40

41 Efficacy and safety of this original approach has recently been reported through a large series
42 reporting long term outcome^{25,26}. Over the 136 patients reported²⁵, 112 were children²⁶ among
43 whom 2 were type I, 67 were type II, 31 were type III and 12 were type IV, according to
44 Delalande's classification. The median follow-up was 4 years. For all hypothalamic hamartoma
45 types, 77.6% of the patients had a favorable outcome (Engel 1+2 outcome score) with 57.1%
46 seizure-free (Engel 1). The best outcome was obtained in patients with type 2 hypothalamic
47 hamartomas, (68.7% Engel 1 and 85.1% Engel 1+2), which is in line with previous series.
48 Patients with isolated gelastic seizures had a better outcome (Engel 1+2 in 90%), as compared
49 to those with other seizure types. Unsurprisingly, a short delay between hamartoma diagnosis
50 and surgery was a factor for a good outcome. Similarly to stereotactic techniques, multiple
51 procedures were frequently needed to achieve good results. The mean number of procedures
52
53
54
55
56
57
58
59
60
61
62
63
64
65

required depended on the Delalande type: 1.50 for type I ; 1.52 for type II ; 1.84 for type III ; 2.46 for type IV.

The overall complication rate was 8.3%, which is similar to available literature.

Conclusion

Surgery is the most effective treatment for drug resistant hypothalamic hamartoma related epilepsy and has to be as precocious as possible, regardless the technique^{20,26,37}. Although open microsurgical resection leads to good epileptological outcomes, its high complication rate limits indications. Only Delalande's type I purely cisternal peduncular forms, when associated with drug-resistant epilepsy, remain a good indications to perform pterional approach^{23,47}. Laser and radiofrequency coagulation procedures (Figure 4) are significant advances compared to the historical microsurgical procedures. Concerning the approaches making a lesion to the whole hypothalamic hamartoma, literature review suggests that multiple radiofrequency small lesions³⁷ have a better efficacy and safety than LiTT^{20,34}, probably due to the difficulty of the latter technique to target the whole lesion while sparing the adjacent structures (Figure 4). Nevertheless, these statement is based on single center results and will probably be counterbalanced by the recent advances of super-selective lesions performed with LiTT⁸². Disconnection approach by laser and radiofrequency coagulation in robot guided stereo-endoscopy provides very good results in term of seizure control and safety, probably due to possibility to fully disconnect the lesion and to spare the adjacent structures by a planar section (Figure 4)^{25,26}.

Going beyond the surgical technique, the analysis of the pathological functional connectivity of the hypothalamic hamartoma by resting state MRI made it possible to target a subpart of the lesion⁶. This approach coupled with LiTT procedures showed excellent results in term of seizure control and safety (Figure 4)⁶. These findings suggest that the true impact on the surgical results does not come from purely surgical technique (laser vs radiofrequency coagulation or stereotactic vs robot-guided stereo-endoscopy) but relies on the understanding of the epileptic network, including inside the epileptic hamartoma, that makes possible to plan a disconnection or a lesioning that spare the adjacent functional structures.

Ethical statement:

- Funding: The authors have received no funding for this article
- Conflict of Interest: The authors declare no conflict of interest
- Ethical approval: This article does not contain any studies with human participant or animals and complies with French ethical standards
- Informed consent: This article does not contain any studies with human participants performed by any of the authors.

References

1. Abila AA, Shetter AG, Chang SW, Wait SD, Brachman DG, Ng Y-T, et al: Gamma Knife surgery for hypothalamic hamartomas and epilepsy: patient selection and outcomes. **J Neurosurg** **113 Suppl**:207–14, 2010
2. Akai T, Okamoto K, Iizuka H, Kakinuma H, Nojima T: Treatments of hamartoma with neuroendoscopic surgery and stereotactic radiosurgery: a case report. **Minim Invasive Neurosurg** **45**:235–9, 2002
3. Arita K, Ikawa F, Kurisu K, Sumida M, Harada K, Uozumi T, et al: The relationship between magnetic resonance imaging findings and clinical manifestations of hypothalamic hamartoma. **J Neurosurg** **91**:212–20, 1999
4. Arita K, Kurisu K, Iida K, Hanaya R, Akimitsu T, Hibino S, et al: Subsidence of seizure induced by stereotactic radiation in a patient with hypothalamic hamartoma. Case report. **J Neurosurg** **89**:645–8, 1998
5. Berkovic SF, Andermann F, Melanson D, Ethier RE, Feindel W, Gloor P: Hypothalamic hamartomas and ictal laughter: evolution of a characteristic epileptic syndrome and diagnostic value of magnetic resonance imaging. **Ann Neurol** **23**:429–39, 1988
6. Boerwinkle VL, Foldes ST, Torrisi SJ, Temkit H, Gaillard WD, Kerrigan JF, et al: Subcentimeter epilepsy surgery targets by resting state functional magnetic resonance imaging can improve outcomes in hypothalamic hamartoma. **Epilepsia** **59**:2284–2295, 2018

- 1
2
3
4
5
6
7
8
9
10
11
12
13
14
15
16
17
18
19
20
21
22
23
24
25
26
27
28
29
30
31
32
33
34
35
36
37
38
39
40
41
42
43
44
45
46
47
48
49
50
51
52
53
54
55
56
57
58
59
60
61
62
63
64
65
7. Bourdillon P, Rheims S, Catenioix H, Montavont A, Ostrowsky-Coste K, Isnard J, et al: Malformations of cortical development: New surgical advances. **Rev Neurol (Paris)** **175**:183–188, 2019
8. Bourdillon P, Cucherat M, Isnard J, Ostrowsky-Coste K, Catenioix H, Guénot M, et al: SEEG-guided radiofrequency thermo-coagulations in patients with focal epilepsy: A systematic review and meta-analysis. **Epilepsia** **59**:00:1–9., 2018
9. Bourdillon P, Isnard J, Catenioix H, Montavont A, Rheims S, Ryvlin P, et al: Stereo electroencephalography-guided radiofrequency thermocoagulation (SEEG-guided RF-TC) in drug-resistant focal epilepsy: Results from a 10-year experience. **Epilepsia** **58**:85–93, 2017
10. Bourdillon P, Rheims S, Catenioix H, Montavont A, Ostrowsky-Coste K, Isnard J, et al: Surgical techniques: Stereoelectroencephalography-guided radiofrequency-thermocoagulation (SEEG-guided RF-TC). **Seizure**:2019
11. Boyko OB, Curnes JT, Oakes WJ, Burger PC: Hamartomas of the tuber cinereum: CT, MR, and pathologic findings. **Am J Neuroradiol** **12**:309–314, 1991
12. Burghardt T, Basha MM, Fuerst D, Mittal S: Crying with sorrow evoked by electrocortical stimulation. **Epileptic Disord** **15**:72–5, 2013
13. Calisto A, Dorfmueller G, Fohlen M, Bulteau C, Conti A, Delalande O: Endoscopic disconnection of hypothalamic hamartomas: Safety and feasibility of robot-assisted, thulium laser-based procedures. **J Neurosurg Pediatr** **14**:563–572, 2014
14. Cappabianca P, Cinalli G, Gangemi M, Brunori A, Cavallo LM, De Divitiis E, et al: Application of neuroendoscopy to intraventricular lesions. **Neurosurgery** **62**:2008
15. Castinetti F, Brue T, Morange I, Carron R, Régis J: Gamma Knife radiosurgery for hypothalamic hamartoma preserves endocrine functions. **Epilepsia** **58**:72–76, 2017
16. Celedin S, Kau T, Gasser J, Kraschl R, Sinzig M: Fetal MRI of a hypothalamic hamartoma in Pallister-Hall syndrome. **Pediatr Neurol** **42**:59–60, 2010
17. Chan YM, Fenoglio-Simeone KA, Paraschos S, Muhammad L, Troester MM, Ng YT, et al: Central precocious puberty due to hypothalamic hamartomas correlates with anatomic features but not with expression of GnRH, TGF α , or KISS1. **Horm Res Paediatr** **73**:312–319, 2010

18. Chibbaro S, Cebula H, Scholly J, Todeschi J, Ollivier I, Timofeev A, et al: Pure endoscopic management of epileptogenic hypothalamic hamartomas. **Neurosurg Rev** **40**:647–653, 2017
19. Coons SW, Rekate HL, Prenger EC, Wang N, Drees C, Ng Y, et al: The histopathology of hypothalamic hamartomas: study of 57 cases. **J Neuropathol Exp Neurol** **66**:131–41, 2007
20. Curry DJ, Raskin J, Ali I, Wilfong AA: MR-guided laser ablation for the treatment of hypothalamic hamartomas. **Epilepsy Res** **142**:131–134, 2018
21. Daly DD, Mulder DW: Gelastic epilepsy. **Neurology** **7**:189–92, 1957
22. Delalande O, Fohlen M: Disconnecting surgical treatment of hypothalamic hamartoma in children and adults with refractory epilepsy and proposal of a new classification. **Neurol Med Chir (Tokyo)** **43**:61–68, 2003
23. Dorfmueller G, Fohlen M, Bulteau C, Delalande O: Surgical disconnection of hypothalamic hamartomas. **Neurochirurgie** **54**:315–319, 2008
24. Du VX, Gandhi S V., Rekate HL, Mehta AD: Laser interstitial thermal therapy: A first line treatment for seizures due to hypothalamic hamartoma? **Epilepsia** **58**:77–84, 2017
25. Ferrand-Sorbets S, Fohlen M, Chipaux M, Nathalie D, Bekaert O, Taussig D, et al: Déconnexion endoscopique des hamartomes hypothalamiques chez les patients atteints d'épilepsie pharmacorésistante: population de 136 adultes et enfants, in **Journées Françaises d'épilepsie**. Lyon, 2018
26. Ferrand-sorbets S, Fohlen M, Delalande O, Zuber K, Chamard P, Taussig D, et al: Seizure outcome and prognostic factors for surgical management of hypothalamic hamartomas in children. **Seizure**:[in press.], 2020
27. Fohlen M, Lellouch A, Delalande O: Hypothalamic hamartoma with refractory epilepsy: surgical procedures and results in 18 patients. **Epileptic Disord** **5**:267–73, 2003
28. Frattali CM, Liow K, Craig GH, Korenman LM, Makhoul F, Sato S, et al: Cognitive deficits in children with gelastic seizures and hypothalamic hamartoma. **Neurology** **57**:43–46, 2001

29. Freeman JL, Coleman LT, Wellard RM, Kean MJ, Rosenfeld J V., Jackson GD, et al: MR Imaging and Spectroscopic Study of Epileptogenic Hypothalamic Hamartomas: Analysis of 72 Cases. **Am J Neuroradiol** **25**:450–462, 2004
30. Gascon GG, Lombroso CT: Epileptic (gelastic) laughter. **Epilepsia** **12**:63–76, 1971
31. Harrison VS, Oatman O, Kerrigan JF: Hypothalamic hamartoma with epilepsy: Review of endocrine comorbidity. **Epilepsia** **58**:50–59, 2017
32. Harvey AS, Freeman JL: Epilepsy in Hypothalamic Hamartoma: Clinical and EEG Features. **Semin Pediatr Neurol** **14**:60–64, 2007
33. Heppner F: [Experiences with the CO2 laser in surgery of the nervous system]. **Zentralbl Neurochir** **40**:297–301, 303–4, 1979
34. Hoppe C, Helmstaedter C: Laser interstitial thermotherapy (LiTT) in pediatric epilepsy surgery. **Seizure**:2018
35. Jung H, Probst EN, Hauffa BP, Partsch CJ, Dammann O: Association of Morphological Characteristics with Precocious Puberty and/ or Gelastic Seizures in Hypothalamic Hamartoma. **J Clin Endocrinol Metab** **88**:4590–4595, 2003
36. Kahane P, Ryvlin P, Hoffmann D, Minotti L, Benabid AL: From hypothalamic hamartoma to cortex: What can be learnt from depth recordings and stimulation? **Epileptic Disord** **5**:205–217, 2003
37. Kameyama S, Shirozu H, Masuda H, Ito Y, Sonoda M, Akazawa K: MRI-guided stereotactic radiofrequency thermocoagulation for 100 hypothalamic hamartomas. **J Neurosurg** **124**:1503–12, 2016
38. Kang S, Graham JM, Olney AH, Biesecker LG: GLI3 frameshift mutations cause autosomal dominant Pallister-Hall syndrome. **Nat Genet** **15**:266–268, 1997
39. Kelly PJ, Sharbrough FW, Kall BA, Goerss SJ: Magnetic Resonance Imaging-Based Computer-Assisted Stereotactic Resection of the Hippocampus and Amygdala in Patients With Temporal Lobe Epilepsy. **Mayo Clin Proc** **62**:103–108, 1987
40. Kerrigan JF, Parsons A, Tsang C, Simeone K, Coons S, Wu J: Hypothalamic hamartoma: Neuropathology and epileptogenesis. **Epilepsia** **58**:22–31, 2017
41. Kuzniecky R, Guthrie B, Mountz J, Bebin M, Faught E, Gilliam F, et al: Intrinsic

epileptogenesis of hypothalamic hamartomas in gelastic epilepsy. **Ann Neurol** **42**:60–67, 1997

42. Kuzniecky RI, Guthrie BL: Stereotactic surgical approach to hypothalamic hamartomas. **Epileptic Disord** **5**:275–80, 2003
43. Mathieu D, Deacon C, Pinard C-A, Kenny B, Duval J: Gamma Knife surgery for hypothalamic hamartomas causing refractory epilepsy: preliminary results from a prospective observational study. **J Neurosurg** **113 Suppl**:215–21, 2010
44. McGonigal A, Sahgal A, De Salles A, Hayashi M, Levivier M, Ma L, et al: Radiosurgery for epilepsy: Systematic review and International Stereotactic Radiosurgery Society (ISRS) practice guideline. **Epilepsy Res** **137**:123–131, 2017
45. Medvid R, Ruiz A, Komotar RJ, Jagid JR, Ivan ME, Quencer RM, et al: Current applications of MRI-guided laser interstitial thermal therapy in the treatment of brain neoplasms and epilepsy: A radiologic and neurosurgical overview. **Am J Neuroradiol** **36**:1998–2006, 2015
46. Mittal S, Mittal M, Montes JL, Farmer J-P, Andermann F: Hypothalamic hamartomas. Part 1. Clinical, neuroimaging, and neurophysiological characteristics. **Neurosurg Focus** **34**:E6, 2013
47. Mittal S, Mittal M, Montes JL, Farmer J-P, Andermann F: Hypothalamic hamartomas. Part 2. Surgical considerations and outcome. **Neurosurg Focus** **34**:E7, 2013
48. Mittal S, Mittal M, Montes JL, Farmer JP, Andermann F: Hypothalamic hamartomas. part 2. surgical considerations and outcome. **Neurosurg Focus** **34**:2013
49. Mullatti N, Selway R, Nashef L, Elwes R, Honavar M, Chandler C, et al: The Clinical Spectrum of Epilepsy in Children and Adults with Hypothalamic Hamartoma. **Epilepsia** **44**:1310–1319, 2003
50. Munari C, Kahane P, Francione S, Hoffmann D, Tassi L, Cusmai R, et al: Role of the hypothalamic hamartoma in the genesis of gelastic fits (a video-stereo-EEG study). **Electroencephalogr Clin Neurophysiol** **95**:154–60, 1995
51. Ng YT, Rekate HL, Prenger EC, Wang NC, Chung SS, Feiz-Erfan I, et al: Endoscopic resection of hypothalamic hamartomas for refractory symptomatic epilepsy. **Neurology** **70**:1543–1548, 2008

52. Ng YT, Rekate HL, Prenger EC, Chung SS, Feiz-Erfan I, Wang NC, et al:
Transcallosal resection of hypothalamic hamartoma for intractable epilepsy. **Epilepsia**
47:1192–1202, 2006
53. Paillas JE, Roger J, Toga M, Soulayrol R, Salamon G, Dravet C, et al: [Hamartoma of
the hypothalamus. Clinical, radiological and histological study. Results of excision].
Rev Neurol (Paris) **120**:177–94, 1969
54. Parrent AG, Blume WT: Stereotactic amygdalohippocampotomy for the treatment of
medial temporal lobe epilepsy. **Epilepsia** **40**:1408–16, 1999
55. Parvizi J, Le S, Foster BL, Bourgeois B, Riviello JJ, Prenger E, et al: Gelastic epilepsy
and hypothalamic hamartomas: neuroanatomical analysis of brain lesions in 100
patients. **Brain** **134**:2960–8, 2011
56. Quiske A, Frings L, Wagner K, Unterrainer J, Schulze-Bonhage A: Cognitive functions
in juvenile and adult patients with gelastic epilepsy due to hypothalamic hamartoma.
Epilepsia **47**:153–8, 2006
57. Régis J, Bartolomei F, de Toffol B, Genton P, Kobayashi T, Mori Y, et al: Gamma
knife surgery for epilepsy related to hypothalamic hamartomas. **Neurosurgery**
47:1343–51; discussion 1351-2, 2000
58. Régis J, Hayashi M, Eupierre LP, Villeneuve N, Bartolomei F, Brue T, et al: Gamma
knife surgery for epilepsy related to hypothalamic hamartomas. **Acta Neurochir Suppl**
91:33–50, 2004
59. Régis J, Lagmari M, Carron R, Hayashi M, McGonigal A, Daquin G, et al: Safety and
efficacy of Gamma Knife radiosurgery in hypothalamic hamartomas with severe
epilepsies: A prospective trial in 48 patients and review of the literature. **Epilepsia**
58:60–71, 2017
60. Régis J, Scavarda D, Tamura M, Nagayi M, Villeneuve N, Bartolomei F, et al:
Epilepsy related to hypothalamic hamartomas: surgical management with special
reference to gamma knife surgery. **Childs Nerv Syst** **22**:881–95, 2006
61. Régis J, Scavarda D, Tamura M, Villeneuve N, Bartolomei F, Brue T, et al: Gamma
knife surgery for epilepsy related to hypothalamic hamartomas. **Semin Pediatr Neurol**
14:73–9, 2007

62. Rosenfeld J V., Feiz-Erfan I: Hypothalamic Hamartoma Treatment: Surgical Resection With the Transcallosal Approach. **Semin Pediatr Neurol** **14**:88–98, 2007
63. Rosenfeld J V., Harvey AS, Wrennall J, Zacharin M, Berkovic SF: Transcallosal Resection of Hypothalamic Hamartomas, with Control of Seizures, in Children with Gelastic Epilepsy. **Neurosurgery** **48**:108–118, 2001
64. Rosenfeld J V: The evolution of treatment for hypothalamic hamartoma: a personal odyssey. **Neurosurg Focus** **30**:E1, 2011
65. Ryvlin P, Cross JH, Rheims S: Epilepsy surgery in children and adults. **Lancet Neurol** **13**:1114–1126, 2014
66. Ryvlin P, Ravier C, Bouvard S, Mauguire F, Le Bars D, Arzimanoglou A, et al: Positron emission tomography in epileptogenic hypothalamic hamartomas. **Epileptic Disord** **5**:219–27, 2003
67. Scholly J, Staack AM, Kahane P, Scavarda D, Régis J, Hirsch E, et al: Hypothalamic hamartoma: Epileptogenesis beyond the lesion? **Epilepsia** **58**:32–40, 2017
68. Schwab RS, Sweet WH, Mark VH, Kjellberg RN, Ervin FR: Treatment of intractable temporal lobe epilepsy by stereotactic amygdala lesions. **Trans Am Neurol Assoc** **90**:12–9, 1965
69. Schwarzmaier H-J, Eickmeyer F, von Tempelhoff W, Fiedler VU, Niehoff H, Ulrich SD, et al: MR-guided laser-induced interstitial thermotherapy of recurrent glioblastoma multiforme: preliminary results in 16 patients. **Eur J Radiol** **59**:208–15, 2006
70. Shim KW, Park EK, Kim DS: Endoscopic treatment of hypothalamic hamartomas. **J Korean Neurosurg Soc** **60**:294–300, 2017
71. Shirozu H, Masuda H, Ito Y, Sonoda M, Kameyama S: Stereotactic radiofrequency thermocoagulation for giant hypothalamic hamartoma. **J Neurosurg** **125**:812–821, 2016
72. Sonoda M, Masuda H, Shirozu H, Ito Y, Akazawa K, Asano E, et al: Predictors of cognitive function in patients with hypothalamic hamartoma following stereotactic radiofrequency thermocoagulation surgery. **Epilepsia** **58**:1556–1565, 2017
73. Southwell DG, Birk HS, Larson PS, Starr PA, Sugrue LP, Augustine KI: Laser ablative

therapy of sessile hypothalamic hamartomas in children using interventional MRI:
report of 5 cases. **J Neurosurg Pediatr** 21:460–465, 2018

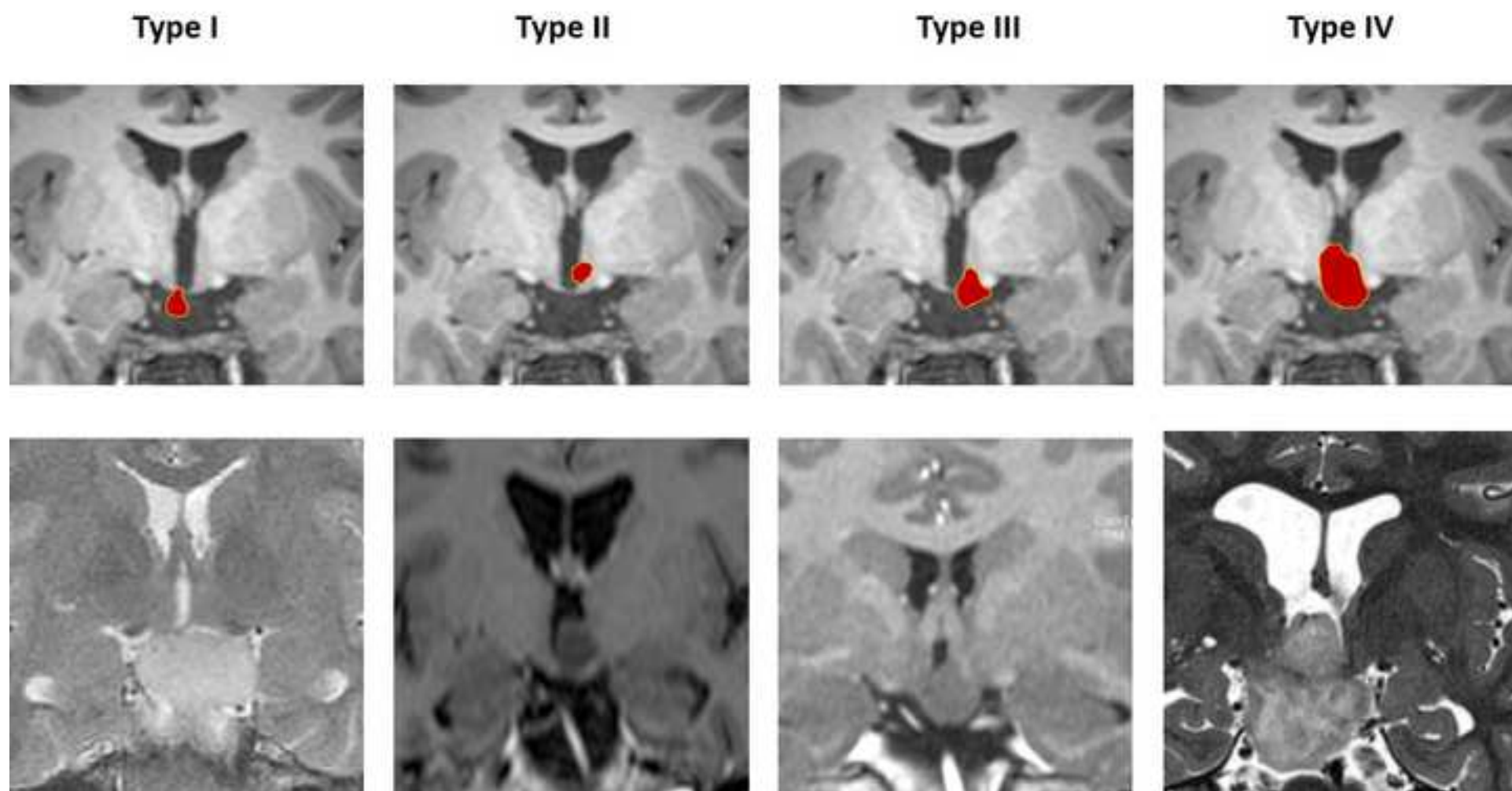
74. Tandon V, Chandra PS, Doddamani RS, Subianto H, Bajaj J, Garg A, et al: Stereotactic Radiofrequency Thermocoagulation of Hypothalamic Hamartoma Using Robotic Guidance (ROSA) Coregistered with O-arm Guidance—Preliminary Technical Note. **World Neurosurg** 112:267–274, 2018
75. Trousseau A: **Clinique Médicale de l'Hôtel-Dieu de Paris**. Paris: J-B Bailière, 1873
76. Valdueza JM, Cristante L, Dammann O, Bentele K, Vortmeyer A, Saeger W, et al: Hypothalamic hamartomas: with special reference to gelastic epilepsy and surgery. **Neurosurgery** 34:949–58; discussion 958, 1994
77. Valentin A, Lazaro M, Mullatti N, Cervantes S, Malik I, Selway RP, et al: Cingulate epileptogenesis in hypothalamic hamartoma. **Epilepsia** 52:2011
78. van Tonder L, Burn S, Iyer A, Blair J, Didi M, Carter M, et al: Open resection of hypothalamic hamartomas for intractable epilepsy revisited, using intraoperative MRI. **Child's Nerv Syst** 34:1663–1673, 2018
79. Wei PH, An Y, Fan XT, Wang YH, Yang YF, Ren LK, et al: Stereoelectroencephalography-Guided Radiofrequency Thermocoagulation for Hypothalamic Hamartomas: Preliminary Evidence. **World Neurosurg** 114:e1073–e1078, 2018
80. Wright JM, Staudt MD, Alonso A, Miller JP, Sloan AE: A novel use of the NeuroBlate SideFire probe for minimally invasive disconnection of a hypothalamic hamartoma in a child with gelastic seizures. **J Neurosurg Pediatr** 21:302–307, 2018
81. Xu DS, Chen T, Hlubek RJ, Bristol RE, Smith KA, Ponce FA, et al: Magnetic resonance imaging-guided laser interstitial thermal therapy for the treatment of hypothalamic hamartomas: A retrospective review. **Clin Neurosurg** 83:1183–1191, 2018
82. Xu DS, Chen T, Hlubek RJ, Bristol RE, Smith KA, Ponce FA, et al: Magnetic Resonance Imaging-Guided Laser Interstitial Thermal Therapy for the Treatment of Hypothalamic Hamartomas: A Retrospective Review. **Neurosurgery**:2018
83. Yao H, Luo S, Ma Z, Zhang Y, Jia G: [Complications after transcallosal transseptal

interforniceal resection of hypothalamic hamartoma: analysis of 37 cases]. **Zhonghua Yi Xue Za Zhi** 89:898–900, 2009

1
2
3
4
5
6
7
8
9
10
11
12
13
14
15
16
17
18
19
20
21
22
23
24
25
26
27
28
29
30
31
32
33
34
35
36
37
38
39
40
41
42
43
44
45
46
47
48
49
50
51
52
53
54
55
56
57
58
59
60
61
62
63
64
65

	Rounded seizure control rate	Rounded seizure free rate	Rounded complication rate	Rounded number of patients reported	Main type of complication
Pterional approach ^{51,67}	90%	55%	50%	30	Third nerve palsy Hemiplegia Diabetes insipidus Hyperphagia Memory impairment
Transcallosal approach ^{51,55,65}	90%	50-55%	10%	70	Memory impairment Thalamic infarction
Endoscopic resection ^{2,19,45,54}	80%	45-50%	8%	25	Memory impairment Hemiparesis
Stereotactic radiosurgery ^{16,47,60}	65%	25%	0%	80	-
LiTT (standard) ^{21,22,85}	80%	45%	25%	115	Memory impairment Hyperphagia
LiTT (fMRI targeted) ⁶	90%	90%	0%	35	-
Stereotactic RF-TC ³⁹	80%	70%	2%	100	Diabetes insipidus
Endoscopic laser and RF-TC ²⁸	80%	60%	8%	135	Diabetes insipidus Hemiplegia Third nerve palsy

Table 1: overview of the different surgical approaches for the treatment of hypothalamic hamartomas. Rates and numbers are rounded based on the literature. Exact rates are described in the respective sections. RF-TC: radiofrequency thermocoagulation; LiTT: laser interstitial thermotherapy.



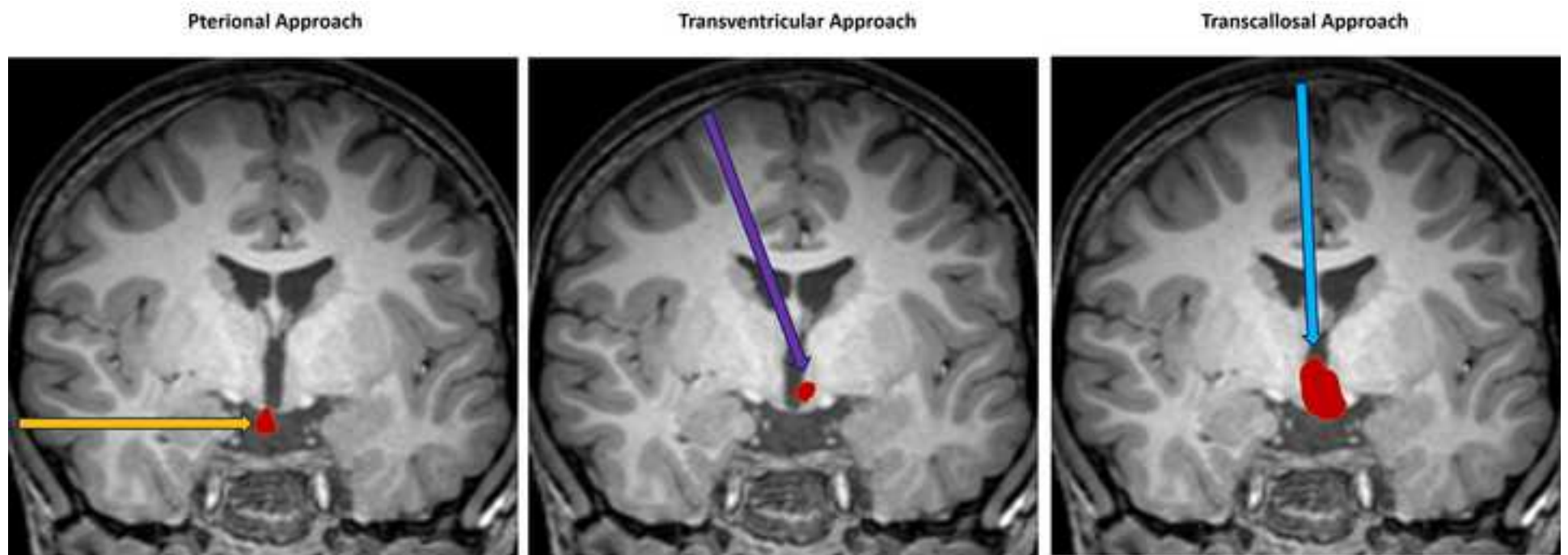
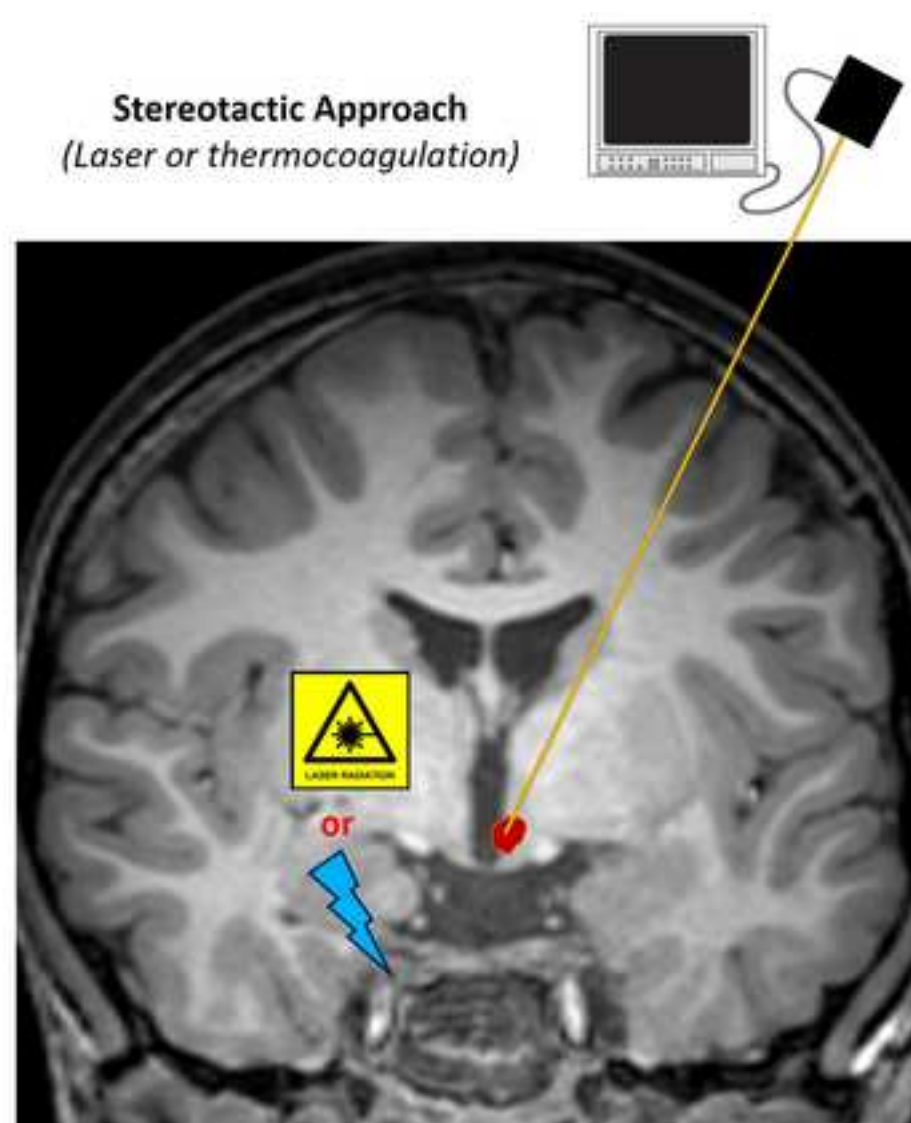
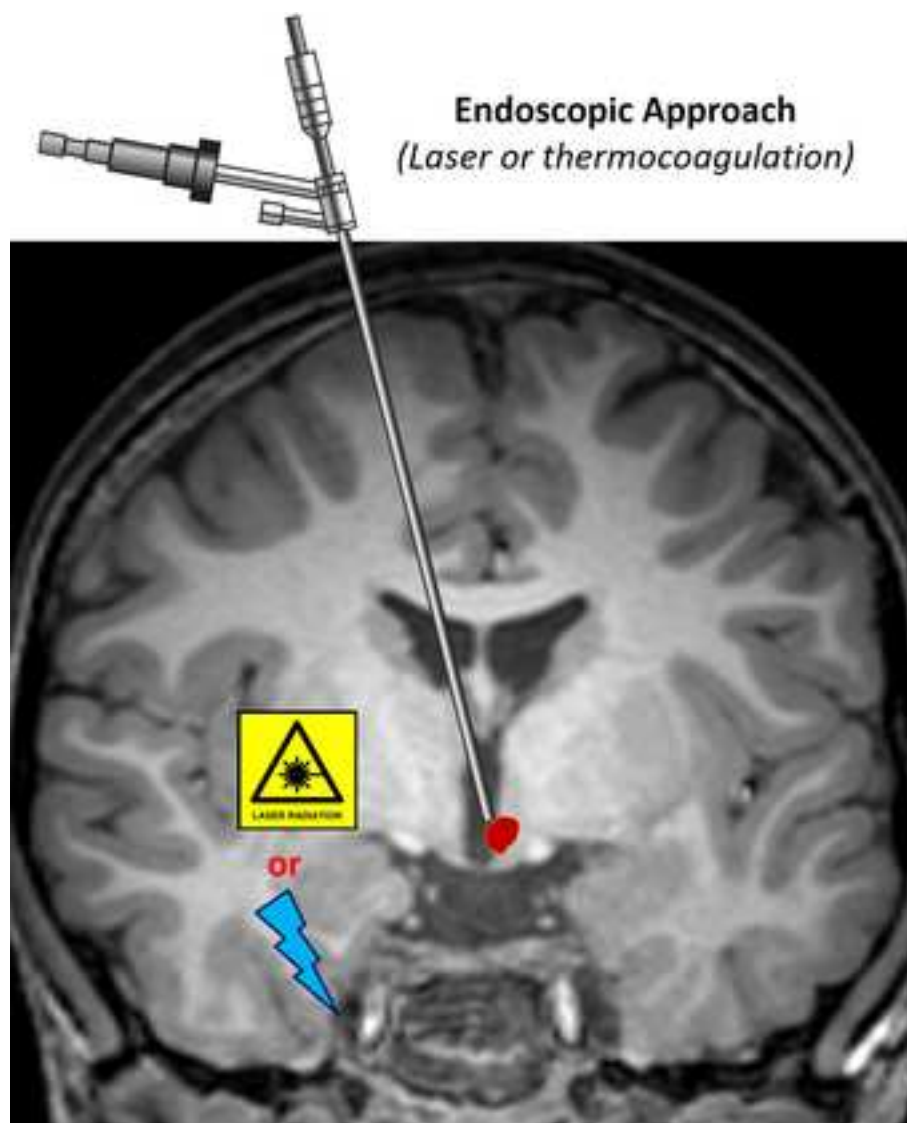
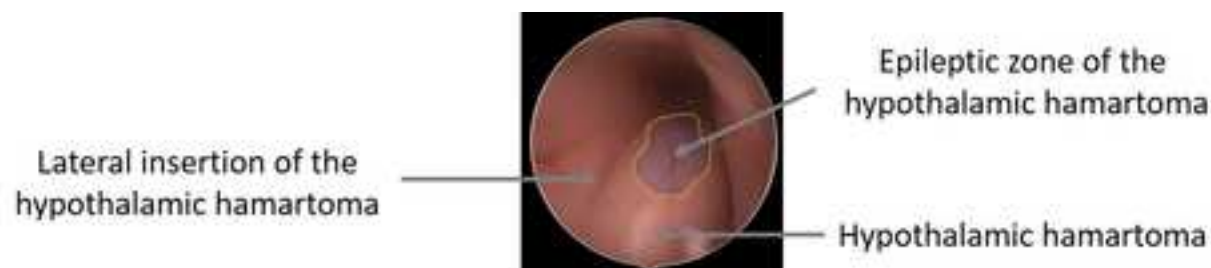


Figure 2.jpg






	<p>Single lesion (Laser - stereotactic)</p>	<p>A stereotactic lesion is performed through a single trajectory. The shape of the lesion (red) make hardly avoidable to spare adjacent structures (dark red) when the whole hamartoma is targeted.</p>	<p>Xu & al. 2018 Curry & al. 2018 Hoppe & al. 2018</p>
	<p>Multiple lesions (Radiofrequency coagulation - stereotactic)</p>	<p>Multiple stereotactic lesions are preformed through multiple trajectories making easier to spare the adjacent structures bur requiring multiple electrode insertions.</p>	<p>Kameyama & al. 2016</p>
	<p>Disconnection (Laser / Radiofrequency coagulation – robot guided stereo-endoscopy)</p>	<p>A planar disconnection is performed along the insertion of the hamartoma. Endoscopy allow to perform multiple/linear lesions trough a single intraparenchymal robot guided trajectory.</p>	<p>Ferrand-Sorbet & al. 2020</p>
	<p>Single lesion with epileptic zone targeting (Laser- stereotactic)</p>	<p>The epileptic zone within the hamartoma (yellow circled blue zone) is identified by resting state connectivity fMRI. A stereotactic lesion is performed through a single trajectory. The limited volume of the lesion make possible to spare the adjacent structures.</p>	<p>Boerwinkle & al. 2018</p>



[Click here to access/download](#)

Video

Thermocoag Hamartomas.mov





Click here to access/download
Video
Laser Hamartomas.mov

