



HAL
open science

Involvement of the cerebellum in EMDR efficiency: a metabolic connectivity PET study in PTSD

A Verger, P F Rousseau, E Malbos, M B Chawki, F Nicolas, C Lançon, S Khalfa, E Guedj

► To cite this version:

A Verger, P F Rousseau, E Malbos, M B Chawki, F Nicolas, et al.. Involvement of the cerebellum in EMDR efficiency: a metabolic connectivity PET study in PTSD. *European Journal of Psychotraumatology*, 2020, 11 (1), 10.1080/20008198.2020.1767986. hal-03451401

HAL Id: hal-03451401

<https://cnrs.hal.science/hal-03451401v1>

Submitted on 26 Nov 2021

HAL is a multi-disciplinary open access archive for the deposit and dissemination of scientific research documents, whether they are published or not. The documents may come from teaching and research institutions in France or abroad, or from public or private research centers.

L'archive ouverte pluridisciplinaire **HAL**, est destinée au dépôt et à la diffusion de documents scientifiques de niveau recherche, publiés ou non, émanant des établissements d'enseignement et de recherche français ou étrangers, des laboratoires publics ou privés.

Involvement of the cerebellum in EMDR efficiency: a metabolic connectivity PET study in PTSD

A. Verger^{a,b}, P. F. Rousseau^c, E. Malbos^{d,f}, M. B. Chawki^a, F. Nicolas^e, C. Lançon^d, S. Khalifa^c and E. Guedj^{f,g,h}

^aDepartment of Nuclear Medicine & Nancytoteop Imaging Platform, CHRU Nancy, Lorraine University, Nancy, France; ^bIadi, Inserm, Umr 1254, Lorraine University, Nancy, France; ^cLaboratoire de Neurosciences Sensorielles et Cognitives, Aix-Marseille Université CNRS, Marseille, France; ^dDepartment of Psychiatry, La Conception University Hospital, Marseille, France; ^eService de Psychiatrie, Hôpital d'Instruction des Armées Sainte-Anne, Toulon, France; ^fCNRS, Ecole Centrale de Marseille, UMR 7249, Institut Fresnel, Aix-Marseille Université, Marseille, France; ^gDepartment of Nuclear Medicine, Assistance Publique Hôpitaux de Marseille, Timone University Hospital, Marseille, France; ^hCERIMED, Aix-Marseille University, Marseille, France

ABSTRACT

Background: We recently reported an improvement of precuneus PET metabolism after EMDR therapy in military participants suffering from PTSD.

Objective: The aim of the present study was to investigate the metabolic changes of precuneus connectivity in these participants after such treatment.

Method: Fifteen participants with PTSD performed a brain 18F-FDG-PET sensitized by virtual reality exposure to war scenes, before and after EMDR treatment. Inter-regional correlation analysis was performed to study metabolic changes of precuneus connectivity through SPMT maps at whole-brain level ($p < 0.005$ for the voxel, $p < 0.05$ for the cluster).

Results: A decrease of connectivity was observed after EMDR between the precuneus and two significant bilateral clusters of the cerebellum (bilateral Crus I and VI cerebellar lobules, Tmax voxel of 5.8 and 5.3, and cluster size of 343 and 314 voxels, respectively). Moreover, higher cerebellar metabolism before treatment was associated with reduced clinical PTSD scores after EMDR ($p = 0.03$).

Conclusions: The posterior cerebellum and its metabolic connectivity with the precuneus are involved in the clinical efficiency of EMDR in PTSD.

Implicación del cerebelo en la eficiencia emdr: un estudio PET de conectividad metabólica en TEPT

Antecedentes: Recientemente informamos una mejora del metabolismo de PET precuneus después de la terapia EMDR en participantes militares que padecen TEPT.

Objetivo: El objetivo del presente estudio fue investigar los cambios metabólicos en la conectividad precuneus en estos participantes después de dicho tratamiento.

Métodos: Quince participantes con trastorno de estrés postraumático se sometieron a 18F-FDG-PET cerebral sensibilizado por la exposición de realidad virtual a escenas de guerra antes y después del tratamiento con EMDR. El análisis de correlación interregional se realizó para estudiar los cambios metabólicos en la conectividad precuneus a través de mapas SPM-T a nivel de todo el cerebro ($p < 0.005$ para el vóxel, $p < 0.05$ para el grupo).

Resultados: Se observó una disminución en la conectividad después de la terapia EMDR entre el precuneo y dos grupos bilaterales significativos del cerebelo (vóxeles Tmax de 5.8 y 5.3 y tamaños de racimo de 343 y 314 vóxeles, respectivamente). Además, un metabolismo cerebeloso más alto antes del tratamiento se asoció con puntuaciones clínicas de TEPT reducidas después de EMDR ($p = 0.03$).

Conclusión: el cerebelo y su conectividad metabólica con el precuneus están involucrados en la eficiencia clínica de EMDR en TEPT.

小脑参与EMDR疗效: PTSD中的代谢连接PET研究

年龄和分娩方式在STEPS干预中的作用: 一项对丹麦性侵幸存者创伤后应激症状治疗的纵向试点研究

引言: 本研究考查了针对青少年性侵幸存者的团体干预计划“STEPS”改编版的益处。该计划由荷兰语翻译成丹麦语, 并且在2011年至2014年期间, 在丹麦强奸受害者中心从青少年扩展到成年人受众, 从团体干预扩展到个体干预形式。

方法: 进行了一项前瞻性非对照研究, 在治疗前后及六个月、十二个月后对103例患者进行随访时, 对其创伤后应激症状和其他创伤相关症状进行了监测。根据ICD-11将参与者初步诊断为创伤后应激障碍(PTSD)和复杂性PTSD, 以观察不同时间段诊断状态的发展, 并使用多层模型来评估症状严重性的发展以及年龄段和分娩方式的调节作用。

结果: 对数线性函数反映出症状随时间的推移出现大幅且统计显著的下降, 且对于所有创伤相关症状测量都是最佳拟合。此效应并不被年龄段或干预类型调节。辍学率与干预类型和年龄无关。

ARTICLE HISTORY

Received 18 December 2019

Revised 26 March 2020

Accepted 4 May 2020

KEYWORDS

PTSD; EMDR; PET; connectivity; cerebellum

PALABRAS CLAVES

TEPT; EMDR; PET; conectividad; cerebelo

关键词

PTSD; EMDR; PET; 连接; 小脑

HIGHLIGHTS

- The connectivity between the precuneus and the posterior cerebellum is decreased in PTSD after EMDR.
- Higher cerebellar metabolism before EMDR is associated with reduced PTSD scores after EMDR.
- The posterior cerebellum and its metabolic connectivity with the precuneus are involved in the clinical efficiency of EMDR in PTSD.

讨论: 将STEPS程序应用于成人以及作为个体干预是可行的, 且效果保持了与原始干预中观察到的效果大小相当。需要使用随机对照试验进行进一步研究, 以确保观察到的效果可归因于STEPS计划。

关键词: 性侵犯; 强奸; 创伤后应激障碍; 复杂性PTSD; ICD-11; 治疗; 干预措施; STEPS

1. Introduction

Post-traumatic stress disorder (PTSD) is the re-experiencing of specific aspects of the traumatic memory in cases of exposure to traumatic events (Hoppen & Morina, 2019). This psychiatric condition is related to a fail in extinguishing a fear-conditioned process (“DSM-5,” 2013). This leads to several symptoms involving both emotional under- and over-modulation (Lanius, Frewen, Vermetten, & Yehuda, 2010). Emotional under-modulation refers to decreased regulation of prefrontal regions resulting from a hyperactivity in limbic regions associated to re-experiencing of the traumatic moment with intrusive thoughts, flashbacks, and nightmares, avoidance of situations related to the trauma and hyperarousal. By contrast, over-modulation of these same prefrontal areas leads to diminished limbic activity and is consequently responsible for negative alterations in cognition and mood, with also attempts to restrict unwanted emotional experiences including in dissociation, numbing, and analgesia (Kolk, Burbridge, & Suzuki, 1997; Lanius et al., 2010; Van Der Kolk, 1998). In fact, PTSD could be the consequence of a different way to encode events of a traumatic memory as compared to ordinary events (Van Der Kolk, 1998).

Eye movement desensitization and reprocessing (EMDR) is now a well-established treatment for PTSD (Chen et al., 2014). EMDR, which consists in alternate bilateral stimulations (ABS) while the patient is asked to maintain their attention on traumatic memories, aims at re-elaborating memory from traumatic events in order to lead them to an adaptive resolution (Landin-Romero, Moreno-Alcazar, Pagani, & Amann, 2018; Shapiro Francine, 2001). The exact physiological mechanism for reaching therapeutic efficiency in EMDR is nonetheless still unknown (Sara Carletto, Borsato, & Pagani, 2017).

¹⁸F-FDG PET is a functional imaging technique that could help to better understanding this efficiency. Indeed, it allows for studying neuronal glucose metabolism. In the framework of military PTSD, it can be sensitized by virtual reality exposure to investigate metabolic changes during stressful tasks (Verger et al., 2018) involving war-related visual, auditory, and proprioceptive stimuli. We recently showed an increased precuneus metabolism upon virtual reality exposure of war scenes after EMDR treatment in military participants suffering from PTSD (Rousseau et al., 2019). The metabolic connectivity can be explored through the interregional correlation analysis (IRCA) developed by Lee et al. (Lee et al., 2008), to underline the networks resulting from

EMDR treatment in these participants. Briefly, it pivots on the fact that different brain areas are metabolically connected when they share similar spatial variance in radiotracer uptake. The precuneus is, in fact, a key region for the well-known ‘default mode network’ in resting-state brain, and it has important functions for self-related mental representations and integration of past and present information. The DMN involves core hub areas including the posterior cingulate, the precuneus, the medial prefrontal cortex, and the bilateral inferior parietal lobes. These hub areas are connected to other regions of the DMN including among others the temporal cortex and the medial temporal lobe (Fransson & Marrelec, 2008). A relative decreased of precuneus activation in PTSD patients has been shown in resting-state MRI studies, as well as a negative correlation between precuneal activity and PTSD severity, similarly to what was reported in our PET study (Rousseau et al., 2019), suggesting disruptions in self-referential thought (Geuze, Vermetten, de Kloet, & Westenberg, 2008; Ke et al., 2016). By studying functional connectivity of the precuneus, a decreased of connectivity has been found in key regions of the DMN, particularly prefrontal areas. (Akiki et al., 2018). By contrast, in a real-time fMRI study after amygdala neurofeedback treatment, an increased connectivity between the precuneus and the left dorsolateral prefrontal cortex was associated with a decrease in hyperarousal symptoms of PTSD (Misaki et al., 2018).

Therefore, the aim of the present study was to investigate the precuneus metabolic PET connectivity changes in military participants suffering from PTSD before and after EMDR.

2. Methods

2.1. Sample

Fifteen military male participants (36.8 ± 8.9 years old) suffering from PTSD since their returns from the Afghanistan or Mali wars were included. The mean disease duration was 5.8 ± 0.8 years. These participants were recruited in the military hospital Sainte-Anne at Toulon, France. Diagnosis of PTSD was established according to the DSM-IV TR (American Psychiatric Association, 2000). Patients with present and/or past neurological or psychiatric conditions, with the exception of anxiety and depressive disorders if their occurrence was connected with PTSD, and with an addictive disorder were excluded. Detailed characteristics of these patients are available in a previous study involving the same sample of patients (Table 1 in Rousseau et al.,

2019). For patient's selection, the Posttraumatic Stress Checklist Scale (PCLS) (Ventureyra, Yao, Cottraux, Note, & De Mey-Guillard, 2002), which is a brief and self-report questionnaire for evaluating the severity of the three main syndromes of PTSD, and the Clinician-Administered PTSD Scale (CAPS) (Blake et al., 1995), which is a structured interview providing a categorical diagnosis, were used as defined by the DSM. The mean scores for the previous tests at inclusion were 62.1 ± 8.2 for the PCLS and 78.1 ± 12.3 for the CAPS, respectively. All these participants performed a brain ^{18}F -FDG PET sensitized by virtual reality interactive exposure of war scenes before and after EMDR therapy. The second ^{18}F -FDG PET was performed during the month following the end of the EMDR therapy. Subjects gave written informed consent for their participation in accordance with the Declaration of Helsinki. The study was approved by the Institutional Review Board CPP Sud Méditerranée (Ref: 2014-002126-12).

2.2. EMDR

None of the participant had received formal exposure or cognitive-behavioural therapy before the EMDR procedure. EMDR therapy was performed according to the standard protocol (Landin-Romero et al., 2018). All participants were symptom-free and no longer diagnosed with PTSD after EMDR therapy, as assessed by a psychiatric diagnosis according to DSM-IV criteria and clinical PTSD scales.

2.3. ^{18}F -FDG-PET acquisition and analysis

^{18}F -FDG PET sensitized by virtual reality exposure was performed using an integrated PET/CT camera (Discovery 710, GE Healthcare, Waukesha, WI) with parameters previously described (Verger et al., 2018). Briefly, each subject was confronted with intense trauma cues, consisting of the attack on their group by insurgents during a patrol in an artificially created village in Afghanistan, with several virtual soldiers wounded. Patients were exposed to the environment approximately 10 min before the injection. ^{18}F -FDG (150 MBq) was injected intravenously 1 min before their unit was assaulted, and the virtual exposure immersion was maintained after injection for approximately 7 min. Thereafter, patients were placed in a quiet environment with their eyes closed but continued to feel the stress of the VRE. PET images, acquired in a lying position as recommended in standard practice, started 30 min after the injection and ended 15 min later.

Whole-brain statistical analysis was performed at the voxel level using SPM8 software (Wellcome Department of Cognitive Neurology, University College, London, UK). PET images were spatially normalized onto the PET template of the Montreal National Institute (MNI) space, smoothed with a Gaussian filter (8 mm full-width

at half-maximum), resulting in $2 \times 2 \times 2$ mm voxel images. Proportional scaling was applied. The bilateral precuneus was selected since it was shown to be the sole area to be involved in PTSD participants responsive to EMDR after SPM T-maps comparison before and after EMDR therapy using paired *t*-tests ($p < 0.005$, uncorrected, $k > 180$) (Rousseau et al., 2019). Its mask was derived from PickAtlas (https://www.nitrc.org/projects/wfu_pickatlas/) using the Automated Anatomical Labelling (AAL) atlas (Tzourio-Mazoyer et al., 2002), and volumes of interest values were individually extracted with Marsbar software (<http://marsbar.sourceforge.net/>). To evaluate metabolic connectivity from the precuneus mask in the intergroup comparison, IRCA was performed as previously described (Lee et al., 2008). Briefly, mean values of precuneus cerebral metabolic rate of glucose were used as interacted covariates to find regions showing significant voxel-wise negative/positive correlations for the direct comparison between PTSD patients before and after EMDR therapy. Results were expressed as an increase of positive or negative connectivity. A threshold of $p < 0.005$ uncorrected for the voxel, and $p < 0.05$ uncorrected for the cluster was applied for SPM (T) maps. These thresholds of significance lead to a cluster volume of more than 300 voxels, well beyond the 'expected voxels per cluster' volume provided by SPM ($k > 51$), used to calculate the probability density function for cluster size based on random field theory to avoid type I and II errors (Lieberman & Cunningham, 2009). The precise identification of each structure located by its MNI coordinates, its respective volume, and T-max intensity were extracted by using the report provided by the SPM xjView toolbox (<http://www.alivelearn.net/xjview>). Mean values of metabolism were extracted at the individual level for precuneus and significant cluster(s) to calculate correlations with Clinician-Administered PTSD Scale CAPS, and Posttraumatic Stress Checklist Scale, PCLS. A canonical analysis correlating cerebellar metabolic values before EMDR to the combination of CAPS and PCLS after therapy was performed. A p -value < 0.05 was considered as significant.

3. Results

All the participants were free of PTSD symptoms at the end of the EMDR therapy (Table 1 in Rousseau et al., 2019). The mean PCLS and CAPS scores after EMDR were respectively at 24.4 ± 8.1 and 13.9 ± 12.7 ($p < 0.001$ for the comparison between scores before and after EMDR).

As shown in Figure 1 and as compared to ^{18}F -FDG PET scans before EMDR, a decrease of connectivity was noticed after EMDR between the precuneus and the cerebellum in two bilateral significant clusters (343 voxels, MNI coordinates of x: 40; y: -66; z: -20, and T_{\max} voxel of 5.8 for the right cerebellar cluster involving the Crus I and VI lobules, 314 voxels, MNI

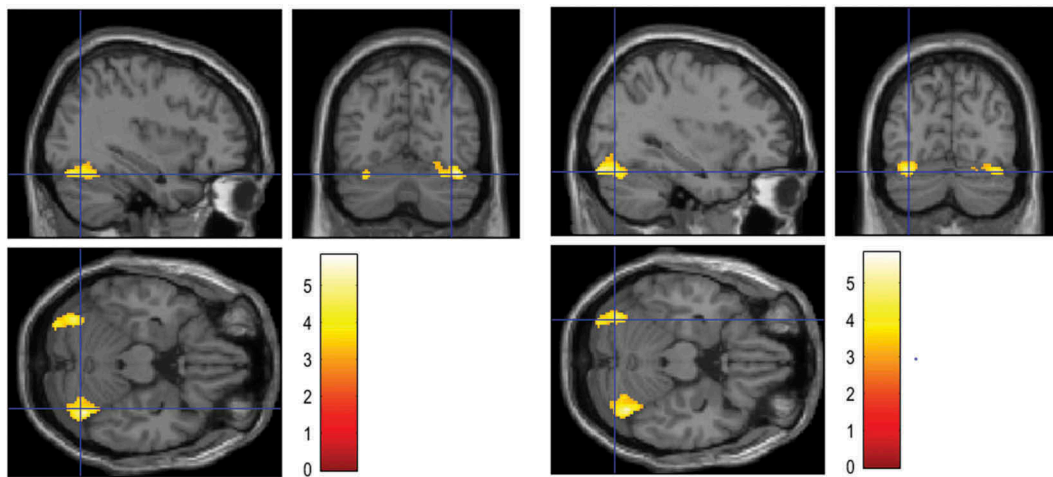


Figure 1. Significant right (left panel) and left (right panel) cerebellar clusters showing decreased ^{18}F -FDG PET metabolic connectivity with precuneus after EMDR, projected onto MRI slices, spatially normalized into the standard SPM template. The right and left cerebellar cluster involve both the Crus I and VI cerebellar lobules at respective T_{\max} voxel of 5.8 and 5.3.

coordinates of x : -30; y : -86; z : -20, and T_{\max} voxel of 5.3 for the left cerebellar cluster involving Crus I and VI lobules).

Moreover, higher cerebellar metabolic values before EMDR were correlated with better responses to clinical PTSD scales after EMDR (canonical analysis correlating cerebellar metabolic values before EMDR to the combination of CAPS and PCLS after therapy; $\rho = 0.67$; $p = 0.03$)

4. Discussion

The current study shows that PTSD remission after EMDR therapy is reflected by a decrease of connectivity between the precuneus and the posterior cerebellum (Crus I and lobule VI). In addition, higher cerebellar metabolism before treatment was correlated to the significantly reduced clinical PTSD scores after EMDR.

Previous studies exploring the physiological mechanisms involved in PTSD were based on the top-down theory (Nicholson et al., 2017). This theory states that in patients with PTSD, the mesial prefrontal cortex, a structure implicated in emotion regulation, is not able to correctly play its role of normalizing the excess of activity of limbic structures (Nicholson et al., 2017), and especially an hyperactivation of amygdalae (Harper, Rasolkhani-Kalhorn, & Drozd, 2009). This insufficiency leads to an incorrect encoding of traumatic memory events and thus to clinical symptoms of the PTSD (Van Der Kolk, 1998). In this line, EMDR efficiency has been shown of resulting from a shift of sub-cortical to neo-cortical transfer information in an EEG study (Pagani et al., 2012), with the reactivation of the mesial prefrontal cortex to correctly encode the traumatic events.

However, a bottom-up theory, involving the cerebellum, has been recently proposed in PTSD (S. Carletto & Borsato, 2017). The cerebellum is a structure implicated in fear emotional regulation (Schmahmann, 2010) and is strongly connected to the whole brain (Zhu, Yung, Kwok-Chong Chow, Chan, & Wang, 2006). The cerebellum presents altered functions in patients with PTSD in a perfusion PET study (Pissiotta et al., 2002). Our results support the role of the cerebellum in PTSD.

Our participants with PTSD exhibited a decrease of connectivity between the precuneus and the posterior cerebellum after clinical response to EMDR. This result shows that the posterior cerebellum and its metabolic connectivity with the precuneus is likely involved in PTSD symptoms and traumatic memory evolution after EMDR therapy. The precuneus, which has already been shown to be the sole structure with increased metabolism after EMDR (Rousseau et al., 2019), is implicated in fear-conditioning and extinction regulation, a mechanism that would be disrupted in PTSD (Fullana et al., 2018). The precuneus and the cerebellum have also been described together as two brain areas involved in PTSD in an fMRI study, as their activation at baseline was correlated with improvement of PTSD symptoms (Ke et al., 2016). The posterior cerebellum (Crus I and II, lobules VI and VII) is devoted to cognitive functions, including working memory, language, visuospatial, and executive functions (Rabellino, Densmore, Théberge, McKinnon, & Lanius, 2018). This area is associated to the Cerebellar Cognitive Affective Syndrome, characterized by affect in emotion regulation associated with either passivity, blunted affect, and withdrawal, or disinhibition, irritability, emotional lability (Schmahmann, 2004; Stoodley & Schmahmann, 2010). Interestingly, these symptoms are those also

exhibited by individuals with PTSD (“DSM-5,” 2013). The posterior cerebellum has already been found to be involved in PTSD as an increased activity in this area has been shown in PTSD as compared to healthy controls in MRI at rest (Wang et al., 2016), and an increased regional cerebral blood flow (rCBF) has been reported in lobule VI and Crus I in PTSD as compared to healthy controls (Bonne et al., 2003). In addition, the posterior cerebellum was shown to participate in the DMN in resting-state fMRI study (Kucyi, Hove, Biederman, Van Dijk, & Valera, 2015). Indeed, lateral cerebellar areas including Crus I/II were shown to be functionally connected with the DMN, and neurostimulation of these cerebellar areas was shown to modulate functional connectivity specifically with and between core DMN hubs (Kucyi et al., 2015). Interestingly, the DMN is known to count for the long-term clinical outcome of PTSD since it is associated with PTSD symptom severity (Reuveni et al., 2016). Regards to the posterior cerebellum, a decreased functional connectivity between this cerebellar part and the central autonomic network was found to correlate positively with PTSD symptomatology in a resting-state fMRI (Thome et al., 2017), this decrease of cerebellar connectivity associated to better PTSD symptomatology being in line with our PET results. These findings suggest that in PTSD, as state anxiety symptoms increase, the posterior cerebellum demonstrates increased connectivity with other cortical areas (Remington & Remington, 2012). By contrast, in a resting-state fMRI study comparing PTSD to healthy controls, Rabellino et al. found a decreased functional connectivity between the posterior cerebellum and prefrontal regions involved in PTSD (Rabellino et al., 2018). This observation strengthens nevertheless that the posterior cerebellum is involved in emotional dysregulation. It should be kept in mind that PTSD is a complex physio-pathological entity exceeding the top-down and bottom-up theories by implementing notions of emotion under- or over-modulation (Lanius et al., 2010). In line with these previous observations, we hypothesize that the decreased of connectivity between the precuneus, an area involved in emotion regulation through self-referential thought and participating in the DMN, and the posterior cerebellum, the cognitive entity part of the cerebellum could explain the better outcome of PTSD patients after EMDR. These connectivity changes are part of the DMN connectivity which is known to be involved in PTSD (Reuveni et al., 2016).

Interestingly, in MRI studies, the volume of the cerebellum is inversely correlated to the clinical PTSD symptoms (Baldaçara et al., 2011), but is also positively correlated to the ability to experience positive affect in such patients (Frewen, Dozois, & Lanius, 2012). In addition, it has been postulated that its activation was

a potential explanation of EMDR therapy (Calancie, Khalid-Khan, Booij, & Munoz, 2018). This is also in line with our results showing that higher cerebellar metabolism before treatment was correlated with better clinical response to EMDR therapy.

Further studies should include waitlist and more larger PTSD participant groups with other treatments to verify that our results are reproducible and specifically related to EMDR therapy (Rousseau et al., 2019). Moreover, this metabolic connectivity analysis has not been performed for the whole brain but by using an a priori hypothesis based on previous reported results (Rousseau et al., 2019). Further analyses exploring the whole-brain connectivity should be set up to better apprehending physiological mechanisms implicated in EMDR efficiency.

Altogether, the present study highlights the involvement of the posterior cerebellum in participants with PTSD evolution. Its metabolic connectivity with the precuneus underlines networks related to EMDR therapy efficiency.

Disclosure statement

No potential conflict of interest was reported by the authors.

Funding

This work has been carried out in the framework of DHUImaging thanks to the support of the A*MIDEX project (no. ANR-11-IDEX-0001-02) (‘Investissements d’Avenir’ French Government program, managed by the French National Research Agency (ANR)).

References

- Akiki, T. J., Averill, C. L., Wrocklage, K. M., Scott, J. C., Averill, L. A., Schweinsburg, B., ... Abdallah, C. G. (2018). Default mode network abnormalities in posttraumatic stress disorder: A novel network-restricted topology approach. *NeuroImage*, 176, 489–498.
- American Psychiatric Association. (2000). *Diagnostic and statistical manual of mental disorders* (4th ed., Text Revision). Washington, DC: Author.
- American Psychiatric Association. (2013). *Diagnostic and statistical manual of mental disorders* (5th ed.). Arlington, VA: Author.
- Baldaçara, L., Jackowski, A. P., Schoedl, A., Pupo, M., Andreoli, S. B., Mello, M. F., ... Bressan, R. A. (2011). Reduced cerebellar left hemisphere and vermal volume in adults with PTSD from a community sample. *Journal of Psychiatric Research*, 45(12), 1627–1633.
- Blake, D. D., Weathers, F. W., Nagy, L. M., Kaloupek, D. G., Gusman, F. D., Charney, D. S., & Keane, T. M. (1995). The development of a Clinician-Administered PTSD Scale. *Journal of Traumatic Stress*, 8(1), 75–90.
- Bonne, O., Gilboa, A., Louzoun, Y., Brandes, D., Yona, I., Lester, H., ... Shalev, A. Y. (2003). Resting regional

- cerebral perfusion in recent posttraumatic stress disorder. *Biological Psychiatry*, 54(10), 1077–1086.
- Calancie, O. G., Khalid-Khan, S., Booij, L., & Munoz, D. P. (2018). Eye movement desensitization and reprocessing as a treatment for PTSD: Current neurobiological theories and a new hypothesis. *Annals of the New York Academy of Sciences*, 1426(1), 127–145.
- Carletto, S., & Borsato, T. (2017). Neurobiological correlates of post-traumatic stress disorder: A focus on cerebellum role. *European Journal of Trauma & Dissociation*, 1(3), 153–157.
- Carletto, S., Borsato, T., & Pagani, M. (2017). The role of slow wave sleep in memory pathophysiology: Focus on post-traumatic stress disorder and eye movement desensitization and reprocessing. *Frontiers in Psychology*, 8, 2050.
- Chen, Y.-R., Hung, K.-W., Tsai, J.-C., Chu, H., Chung, M.-H., Chen, S.-R., ... Chou, K.-R. (2014). Efficacy of eye-movement desensitization and reprocessing for patients with posttraumatic-stress disorder: A meta-analysis of randomized controlled trials. *PLoS One*, 9(8), e103676.
- Fransson, P., & Marrelec, G. (2008). The precuneus/posterior cingulate cortex plays a pivotal role in the default mode network: Evidence from a partial correlation network analysis. *NeuroImage*, 42(3), 1178–1184.
- Frewen, P. A., Dozois, D. J. A., & Lanius, R. A. (2012). Assessment of anhedonia in psychological trauma: Psychometric and neuroimaging perspectives. *European Journal of Psychotraumatology*, 3(1), 8587.
- Fullana, M. A., Albajes-Eizagirre, A., Soriano-Mas, C., Vervliet, B., Cardoner, N., Benet, O., ... Harrison, B. J. (2018). Fear extinction in the human brain: A meta-analysis of fMRI studies in healthy participants. *Neuroscience and Biobehavioral Reviews*, 88, 16–25.
- Geuze, E., Vermetten, E., de Kloet, C. S., & Westenberg, H. G. M. (2008). Precuneal activity during encoding in veterans with posttraumatic stress disorder. *Progress in Brain Research*, 167, 293–297.
- Harper, M. L., Rasolkhani-Kalhorn, T., & Drozd, J. F. (2009). On the neural basis of EMDR therapy: Insights from qEEG studies. *Traumatology*, 15(2), 81–95.
- Hoppen, T. H., & Morina, N. (2019). The prevalence of PTSD and major depression in the global population of adult war survivors: A meta-analytically informed estimate in absolute numbers. *European Journal of Psychotraumatology*, 10(1), 1578637.
- Ke, J., Zhang, L., Qi, R., Li, W., Hou, C., Zhong, Y., ... Lu, G. (2016). A longitudinal fMRI investigation in acute post-traumatic stress disorder (PTSD). *Acta Radiologica*, 57(11), 1387–1395.
- Kolk, B. A., Burbridge, J. A., & Suzuki, J. (1997). The psychobiology of traumatic memory.: Clinical implications of neuroimaging studies. *Annals of the New York Academy of Sciences*, 821(1 Psychobiology), 99–113.
- Kucyi, A., Hove, M. J., Biederman, J., Van Dijk, K. R. A., & Valera, E. M. (2015). Disrupted functional connectivity of cerebellar default network areas in attention-deficit/hyperactivity disorder. *Human Brain Mapping*, 36(9), 3373–3386.
- Landin-Romero, R., Moreno-Alcazar, A., Pagani, M., & Amann, B. L. (2018). How does eye movement desensitization and reprocessing therapy work? A systematic review on suggested mechanisms of action. *Frontiers in Psychology*, 9, 1395.
- Lanius, R. A., Frewen, P. A., Vermetten, E., & Yehuda, R. (2010). Fear conditioning and early life vulnerabilities: Two distinct pathways of emotional dysregulation and brain dysfunction in PTSD. *European Journal of Psychotraumatology*, 1(1), 5467.
- Lee, D. S., Kang, H., Kim, H., Park, H., Oh, J. S., Lee, J. S., & Lee, M. C. (2008). Metabolic connectivity by interregional correlation analysis using statistical parametric mapping (SPM) and FDG brain PET; methodological development and patterns of metabolic connectivity in adults. *European Journal of Nuclear Medicine and Molecular Imaging*, 35(9), 1681–1691.
- Lieberman, M. D., & Cunningham, W. A. (2009). Type I and Type II error concerns in fMRI research: Re-balancing the scale. *Social Cognitive and Affective Neuroscience*, 4(4), 423–428.
- Misaki, M., Phillips, R., Zotev, V., Wong, C.-K., Wurfel, B. E., Krueger, F., ... Bodurka, J. (2018). Real-time fMRI amygdala neurofeedback positive emotional training normalized resting-state functional connectivity in combat veterans with and without PTSD: A connectome-wide investigation. *NeuroImage: Clinical*, 20, 543–555.
- Nicholson, A. A., Rabellino, D., Densmore, M., Frewen, P. A., Paret, C., Kluetsch, R., ... Lanius, R. A. (2017). The neurobiology of emotion regulation in posttraumatic stress disorder: Amygdala downregulation via real-time fMRI neurofeedback: Amygdala Down-Regulation in PTSD. *Human Brain Mapping*, 38(1), 541–560.
- Pagani, M., Di Lorenzo, G., Verardo, A. R., Nicolais, G., Monaco, L., Lauretti, G., ... Siracusano, A. (2012). Neurobiological correlates of EMDR monitoring – An EEG study. *PLoS ONE*, 7(9), e45753.
- Pissioti, A., Frans, Ö., Fernandez, M., von Knorring, L., Fischer, H., & Fredrikson, M. (2002). Neurofunctional correlates of posttraumatic stress disorder: A PET symptom provocation study. *European Archives of Psychiatry and Clinical Neuroscience*, 252(2), 68–75.
- Rabellino, D., Densmore, M., Théberge, J., McKinnon, M. C., & Lanius, R. A. (2018). The cerebellum after trauma: Resting-state functional connectivity of the cerebellum in posttraumatic stress disorder and its dissociative subtype. *Human Brain Mapping*, 39(8), 3354–3374.
- Remington, L. A., & Remington, L. A. (2012). *Clinical anatomy and physiology of the visual system* (3rd ed.). St. Louis, MO: Elsevier/Butterworth Heinemann.
- Reuveni, I., Bonne, O., Giesser, R., Shragai, T., Lazarovits, G., Isserles, M., ... Levin, N. (2016). Anatomical and functional connectivity in the default mode network of post-traumatic stress disorder patients after civilian and military-related trauma. *Human Brain Mapping*, 37(2), 589–599.
- Rousseau, P. F., Malbos, E., Verger, A., Nicolas, F., Lançon, C., Khalfa, S., & Guedj, E. (2019). Increase of precuneus metabolism correlates with reduction of PTSD symptoms after EMDR therapy in military veterans: An 18F-FDG PET study during virtual reality exposure to war. *European Journal of Nuclear Medicine and Molecular Imaging*, 46(9), 1817–1821.
- Schmahmann, J. D. (2004). Disorders of the cerebellum: Ataxia, dysmetria of thought, and the cerebellar cognitive affective syndrome. *The Journal of Neuropsychiatry and Clinical Neurosciences*, 16(3), 367–378.
- Schmahmann, J. D. (2010). The role of the cerebellum in cognition and emotion: Personal reflections since 1982 on the dysmetria of thought hypothesis, and its historical evolution from theory to therapy. *Neuropsychology Review*, 20(3), 236–260.
- Shapiro Francine. (2001). *Eye Movement Desensitization and Reprocessing (EMDR): Basic principles, protocols, and procedures* (2nd ed.). New York: Guilford Press.

- Stoodley, C. J., & Schmahmann, J. D. (2010). Evidence for topographic organization in the cerebellum of motor control versus cognitive and affective processing. *Cortex*, 46(7), 831–844.
- Thome, J., Densmore, M., Frewen, P. A., McKinnon, M. C., Théberge, J., Nicholson, A. A., ... Lanius, R. A. (2017). Desynchronization of autonomic response and central autonomic network connectivity in posttraumatic stress disorder. *Human Brain Mapping*, 38(1), 27–40.
- Tzourio-Mazoyer, N., Landeau, B., Papathanassiou, D., Crivello, F., Etard, O., Delcroix, N., ... Joliot, M. (2002). Automated anatomical labeling of activations in SPM using a macroscopic anatomical parcellation of the MNI MRI single-subject brain. *NeuroImage*, 15(1), 273–289.
- Van Der Kolk, B. A. (1998). Trauma and memory: Trauma and memory. *Psychiatry and Clinical Neurosciences*, 52(S1), S57–S69.
- Ventureyra, V. A. G., Yao, S.-N., Cottraux, J., Note, I., & De Mey-Guillard, C. (2002). The validation of the Posttraumatic Stress Disorder Checklist Scale in posttraumatic stress disorder and nonclinical subjects. *Psychotherapy and Psychosomatics*, 71(1), 47–53.
- Verger, A., Malbos, E., Reynaud, E., Mallet, P., Mestre, D., Pergandi, J.-M., ... Guedj, E. (2018). Brain metabolism and related connectivity in patients with acrophobia treated by virtual reality therapy: An 18F-FDG PET pilot study sensitized by virtual exposure. *EJNMMI Research*, 8(1), 93.
- Wang, T., Liu, J., Zhang, J., Zhan, W., Li, L., Wu, M., ... Gong, Q. (2016). Altered resting-state functional activity in posttraumatic stress disorder: A quantitative meta-analysis. *Scientific Reports*, 6(1), 27131.
- Zhu, J.-N., Yung, W.-H., Kwok-Chong Chow, B., Chan, Y.-S., & Wang, -J.-J. (2006). The cerebellar-hypothalamic circuits: Potential pathways underlying cerebellar involvement in somatic-visceral integration. *Brain Research Reviews*, 52(1), 93–106.