



# A ROD-CONE DYSTROPHY IS SYSTEMATICALLY ASSOCIATED TO THE RTN4IP1 RECESSIVE OPTIC ATROPHY

Isabelle Meunier, Béatrice Bocquet, Majida Charif, Claire-Marie Dhaenens, Gael Manes, Patrizia Amati-Bonneau, Agathe Roubertie, Xavier Zanlonghi, Guy Lenaers

## ► To cite this version:

Isabelle Meunier, Béatrice Bocquet, Majida Charif, Claire-Marie Dhaenens, Gael Manes, et al.. A ROD-CONE DYSTROPHY IS SYSTEMATICALLY ASSOCIATED TO THE RTN4IP1 RECESSIVE OPTIC ATROPHY. *RETINA. The Journal of Retinal and Vitreous Diseases*, 2021, 41 (8), pp.1771-1779. 10.1097/IAE.0000000000003054 . hal-03873036

**HAL Id: hal-03873036**

**<https://hal.science/hal-03873036>**

Submitted on 26 Nov 2022

**HAL** is a multi-disciplinary open access archive for the deposit and dissemination of scientific research documents, whether they are published or not. The documents may come from teaching and research institutions in France or abroad, or from public or private research centers.

L'archive ouverte pluridisciplinaire **HAL**, est destinée au dépôt et à la diffusion de documents scientifiques de niveau recherche, publiés ou non, émanant des établissements d'enseignement et de recherche français ou étrangers, des laboratoires publics ou privés.

# A ROD–CONE DYSTROPHY IS SYSTEMATICALLY ASSOCIATED TO THE *RTN4IP1* RECESSIVE OPTIC ATROPHY

ISABELLE MEUNIER, MD, PhD,\*† BÉATRICE BOCQUET, PhD,\*† MAJIDA CHARIF, PhD,‡  
CLAIRE-MARIE DHAENENS, PHARM.D, PhD,§ GAEL MANES, PhD,\* PATRIZIA AMATI-BONNEAU, MD,¶  
AGATHE ROUBERTIE, MD, PhD,\*† XAVIER ZANLONGHI, MD,\*\* GUY LENAERS, PhD††

**Purpose:** *RTN4IP1* biallelic mutations cause a recessive optic atrophy, sometimes associated to more severe neurological syndromes, but so far, no retinal phenotype has been reported in *RTN4IP1* patients, justifying their reappraisal.

**Methods:** Seven patients from four families carrying biallelic *RTN4IP1* variants were retrospectively reviewed, with emphasis on their age of onset, visual acuity, multimodal imaging including color and autofluorescence frames, spectral-domain optical coherence tomography with RNFL and macular analyses.

**Results:** Seven patients from four *RTN4IP1* families developed in their first decade of life a bilateral recessive optic atrophy with severe central visual loss, and primary nystagmus developed in 5 of 7 patients. Six patients were legally blind. In a second stage, the seven individuals developed a rod–cone dystrophy, sparing the macular zone and the far periphery. This retinal damage was identified by 55° field fundus autofluorescence frames and also by spectral-domain optical coherence tomography scans of the temporal part of the macular zone in five of the seven patients. Full-field electroretinography measurements disclosed reduced b-wave amplitude of the rod responses in all patients but two. Family 4 with the p.R103H and c.601A > T (p.K201\*) truncating mutation had further combined neurological signs with cerebellar ataxia, seizures, and intellectual disability.

**Conclusion:** *RTN4IP1* recessive optic atrophy is systematically associated to a rod–cone dystrophy, which suggests that both the retinal ganglion cells and the rods are affected as a result of a deficit in the mitochondrial respiratory chain. Thus, systematic widefield autofluorescence frames and temporal macular scans are recommended for the evaluation of patients with optic neuropathies.

RETINA 41:1771–1779, 2021

Among all mitochondrial rare diseases, the inherited optic neuropathies represent the most common abnormalities affecting specifically the retinal ganglion cells, leading to the optic nerve degeneration and often legal blindness. They are caused by mutations in the mitochondrial DNA, defining the Leber Hereditary Optic Neuropathy, or to mono or biallelic mutations in autosomal genes, defining the dominant optic atrophy or Kjer disease and the recessive optic atrophy (ROA). Although each inherited optic neuropathies affects specifically the retinal ganglion cells because of a mitochondrial defect, their natural histories are highly distinguishable. Leber hereditary optic neuropathy occurs most frequently in young man with an acute painless visual loss in one eye followed by the fellow eye, leading to legal blindness (visual acuity <20/200 in both

eyes) with a bilateral central scotoma.<sup>1,2</sup> Dominant optic atrophy, which is the most frequent inherited optic neuropathies, is a chronic disease, starting in general during the first two decades and slowly evolving to poor vision or to legal blindness in few syndromic cases.<sup>2–10</sup> Recessive optic atrophy are by far the less frequent IONs. They are proposed to be a congenital disease, leading to poor vision during childhood, sometimes to legal blindness during adulthood, although their rather recent identifications did not allow performing long examination follow-ups. They are related to biallelic variants in *TMEM126A*, *ACO2*, *NDUFS2*, and *RTN4IP1*, four genes encoding intramitochondrial proteins involved in the Krebs cycle and the assembly of the respiratory chain Complex I, thus affecting primarily the production of adenosine triphosphate by the oxidative phosphorylation.<sup>11–14</sup> Nota-

bly, mutations in the same four genes can lead to syndromic disorders, associating the optic atrophy to many other neurological symptoms, sometimes leading to premature death. This is the case for biallelic *ACO2* mutations leading to the infantile cerebellar and retinal dystrophy, a complex neurological debilitating condition associated to optic atrophy and retinal dystrophy.<sup>15</sup> This is also the case for biallelic *RTN4IP1* mutations, leading to severe encephalopathies, associated to seizures and poor vision because of the atrophy of the optic nerve.<sup>16</sup> In these latter cases, as well in other *RTN4IP1* cases of isolated ROA, no report has ever disclosed a retinal dystrophy. Nevertheless, by reappraising the ophthalmological data from our cohort of *RTN4IP1* individuals, we found systematically a rod-cone dystrophy that we describe hereafter.

## Methods

Informed consent for clinical examination was obtained and signed by all patients. All methods were performed in accordance with approved protocols of Montpellier University Hospital and in agreement with the Declaration of Helsinki. The Ministry of Public Health accorded approval for biomedical research under the authorization number 11018S.

### Clinical Examination

Age of onset, initial symptoms, best-corrected visual acuity with Snellen charts, 15-Hue desaturated color

From the \*Institute for Neurosciences of Montpellier U1051, University of Montpellier, Montpellier, France; †National Center in Rare Diseases, Genetics of Sensory Diseases, University Hospital, Montpellier, France; ‡Genetics, and Immuno-cell Therapy Team, Mohammed First University, Oujda, Morocco; §Biochemistry and Molecular Biology Department—UF Génopaths, Univ Lille, Lille, France; ¶Department of Biochemistry and Genetics, University Hospital Angers, Angers, France; \*\*Jules Verne Clinic, Nantes, France; and ††MitoLab Team, UMR CNRS 6015—INSERM U1083, Institut MitoVasc, Angers University and Hospital, Angers, France.

Supported by the National Centre for inherited rare sensory diseases of Montpellier University and by the Université d'Angers, CHU d'Angers, the Région Pays de la Loire, Angers Loire Métropole, the Fondation Maladies Rares, the Fondation VISIO, Kjer-France, Ouvrir Les Yeux, Retina France, UNADEV, Fondation de France.

None of the authors has any financial/conflicting interests to disclose.

This is an open-access article distributed under the terms of the Creative Commons Attribution-Non Commercial-No Derivatives License 4.0 (CCBY-NC-ND), where it is permissible to download and share the work provided it is properly cited. The work cannot be changed in any way or used commercially without permission from the journal.

Reprint requests: Guy Lenaers, PhD, MitoLab Team, Mitochondrial Medicine Research Centre, Institut MitoVasc, Université d'Angers, UMR CNRS 6015, INSERM U1083, CHU Bât IRIS/IBS, Rue des Capucins, 49933 Angers Cedex 9, France; e-mail: guy.lenaers@inserm.fr

vision test, Goldmann visual fields, fundus photography (Nidek nonmydriatic automated fundus camera, AFC 330, Nidek Inc, Japan), infrared and autofluorescence imaging (30 and 55° field, combined Heidelberg retina angiograph), and spectral-domain optical coherence tomography (SD-OCT) macular scans (Spectralis OCT device (Heidelberg Engineering, Dossenheim, Germany) were performed. Full-field electroretinography (Ff-ERG) was performed according to the guidelines of the International Society for Clinical Electrophysiology of Vision (ISCEV) using a Ganzfeld apparatus (Ophthalmologic Monitor, Métrovision, Pérenchies, France).

### Genetic Analysis

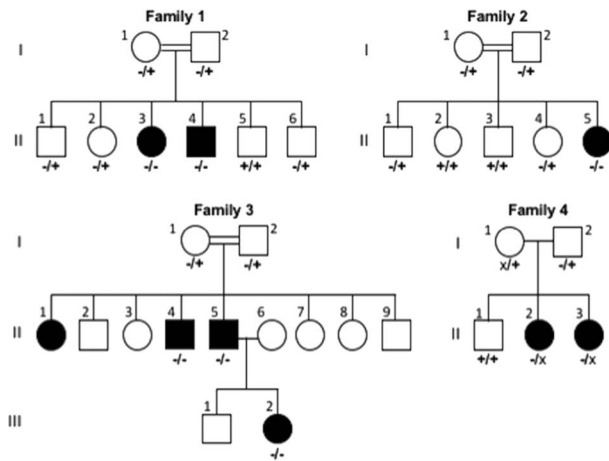
The seven individuals reported herein belong to four families. Neuro-ophthalmological and genetic data for the Families 1, 2, and 4 were already described in a previous work.<sup>13</sup> *RTN4IP1* mutations were identified by exome sequencing in the index case of Family 1 and in three affected individuals of Family 3 (II-4, II-5, and III-2), whereas they were identified by sequencing a panel of inherited optic neuropathies target genes in other affected individuals. Mutations were confirmed by Sanger sequencing on blood genomic DNA from affected individuals and their relatives. All parents were carrier of one of the two mutations, whereas unaffected brothers and sisters were heterozygous for one mutation or not carrier.

## Results

Three of the four *RTN4IP1* families described here are from consanguineous Roma origins (Figure 1). They carry the recurrent c.308 G > A (p.R103H) mutation at homozygous status on a conserved haplotype in all affected individuals. Notably, the Patient III-2 from Family 3 had an isodisomy transmission of the mutated allele from her father. In Family 4, the two affected sisters had one allele with the same c.308 G > A mutation, although on a different haplotype, and the second allele with the c.601A > T mutation (p.K201\*), resulting in a truncated protein. By screening the list of mutations generated by exome sequencing of the index case of Family 1, and of the three individuals from Family 3, we did not evidence any mono- or biallelic mutations responsible for a rod-cone dystrophy or related to an inherited retinal condition.

### Clinical Data of the Isolated Recessive Optic Atrophy Individuals With the Homozygous *RTN4IP1* c.308 G > A (p.R103H) Mutations

Among the five patients from Families 1, 2, and 3, none had additional symptom or ptosis or ophthalmoplegia (Table 1). Visual loss occurred before the age of 8



**Fig. 1.** Family pedigrees of the seven patients with *RTN4IP1* mutations. Black symbols = affected individuals with biallelic *RTN4IP1* mutations. The “-” represents the c.308 G > A missense mutation, whereas the “x” represents the c.601A > T nonsense mutation. All studied patients display a rod-cone dystrophy. The affected brother (II-4) from Family 1 and the affected sister (II-1) from the Family 3 were not examined in our ophthalmology department.

years, and all were legally blind except the proband of Family 2, who had a visual acuity of 20/63 in the right eye and 20/100 in the left eye, at the age of 23 years (Figure 2). All patients described a stationary far vision but worsening difficulties to read with the need of low vision systems, early in childhood, except the Family 2 proband. In Family 3, the three affected patients had a nystagmus that appeared during the first year of life. Unexpectedly, the proband II.5 of Family 3 reported low luminance and night vision abnormalities in his first decade of life and progressive peripheral visual field impairment in adulthood. Beyond the ROA causing his low vision state since early childhood, the visual field was severely impaired limited to the 15 central degrees at the age of 60 years. Multimodal imaging and Ff-ERG confirmed that this progressive symptom resulted from rod-cone dystrophy, combined to the optic atrophy (Figure 3).

By questioning the other four patients with the homozygous *RTN4IP1* c.308 G > A mutations, we disclosed that they had a mild to severe night blindness, progressing since their first decade of life. This last symptom was overlooked by the patients because their major difficulty was related to the severe central visual loss. We thus reevaluated all *RTN4IP1*-patients with Goldmann visual field, large field fundus autofluorescence frames (FAF), and SD-OCT scan on the temporal part of the macula and Ff-ERG evaluations, to substantiate the retinal dystrophy. All patients had a ring central scotoma, except the individual II.5 of Family 3 who had a tubular visual field and the proband II.3 of Family 1 who had a mild visual field impairment. Beyond the optic damage, the retinal vessels were narrowed in all cases on FAF examination and color photographs. There were atrophic

lesions or pigmentary changes in the periphery of the retina in three patients: the proband II.3 of the Family 1 and individuals II.5 and III.2 of Family 3 (Figure 3). Notably, widefield FAF disclosed a hyperautofluorescence ring in all cases, with peripheral areas of abnormal lower signal in the peripheral retina, in three of five patients. In patient II.4 of Family 3 (Figure 4), the ring of increased autofluorescence was tiny and subtle, while SD-OCT distinctly revealed the thinning of the outer nuclear layer and the loss of the ellipsoid and interdigitation lines at the temporal part of the posterior pole, resulting in the diagnosis of rod-cone dystrophy. Macular SD-OCT examination revealed a thinning of the central retina (mean foveal thickness: 232  $\mu$ m, minimal and maximal values of 201  $\mu$ m and 277  $\mu$ m, respectively) with a preservation of both ellipsoid line and foveal expansion of the outer nuclear layer. The individual II.5 of the Family 3 had a macular edema with cystic lesions and preserved macular ellipsoid line. Despite multimodal imaging pattern in line with a rod cone dystrophy, the probands of families 1 and 2 had preserved rod responses, but prolonged implicit times or reduced amplitudes on light-adapted 30 Hz Flicker ISCEV full-field ERG.

#### *Clinical Data of Syndromic Recessive Optic Atrophy Individuals With Compound Heterozygous RTN4IP1 Mutations*

The two patients from Family 4 are compound heterozygous for the previous c.308 G > A mutation, and the c.601A > T (p.K201\*) mutation leading to a truncated protein. Both had a severe syndromic phenotype, with combined generalized seizures, intellectual disability and mild cerebellar ataxia (Table 1). The two sisters present a nystagmus and are legally blind since the age of 6 months. They have major difficulties in near vision despite the use of low vision devices. They also have low luminance and night vision difficulties, noted before the age of 5 years. Goldmann visual fields were not done because of their intellectual disability. Color photographs revealed no pigmentary changes in the peripheral retina, while they revealed optic disk pallor and of retinal vessel narrowing. Their diagnosis of rod cone dystrophy was based on wide-field FAF pattern, on the loss of the ellipsoid line, the thinning of the outer nuclear layer in the temporal retina on SD-OCT (Figure 3), and the reduction by half of the rod and cone responses in Ff-ERG.

## Discussion

By revisiting the ocular phenotype of all our patients with biallelic *RTN4IP1* mutations, we found that, in addition to the ROA resulting in low visual acuity since

Table 1. Clinical Data of the Seven *RTN4IP1* Patients From the four Families, Characterized by an Early Childhood-Onset Recessive Optic Atrophy Associated to an Adult-Onset Rod Cone Dystrophy

Family, Patient, Gender	Age at Onset	Initial Visual Acuity RE/LE Age	Final Visual Acuity, RE/LE Age	Near Vision Aids	Nystagmus	Night Blindness	Initial GVF RE/LE, Final GVF RE/LE	Narrowed Vessels	Bone Spicules	Macular Edema, Foveal Thickness FAF Annular Ring FAF Hypo- or Hyperautofluorescence Peripheral Spots	Dark-Adapted 3 ERG a, b waves: Amplitudes in $\mu V$ , a, b waves: Implicit times in ms, RE-LE Light-Adapted 3 ERG a, b waves: Amplitudes in $\mu V$ , a, b waves: Implicit times in ms, RE-LE Light-Adapted 30Hz Flicker ERG Amplitude and Implicit time RE, LE
Family 1, II.3, F	6	20/200 20/200 37	20/200 20/200 45	Yes FD	No	No	60°N, 50°S, 70°T, 60°I 60°N, 50°S, 75°T, 65°I 45°N, 50°S, 70°T, 55°I 50°N, 50°S, 70°T, 60°I	Yes	No	No 226 $\mu$ -201 $\mu$ Yes	a: 93–78 $\mu V$ , b: 244–238 $\mu V$ , a: 35–35 ms, b: 62–62 ms a: 18–14 $\mu V$ , b: 84–78 $\mu V$ a: 27–26 ms, b: 53–52 ms Flicker: 104–104 $\mu V$ , 34–34 ms.
Family 2, II.5, F	6	20/50 20/100 10	20/63 20/100 23	No	No	Yes FD	50°N, 50°S, 85°T, 70°I 55°N, 50°S, 90°T, 70°I 50°N, 50°S, 80°T, 60°I 50°N, 50°S, 60°T, 60°I	Yes	No	No 231 $\mu$ -234 $\mu$ Yes	a: 95–82 $\mu V$ , b: 227–219 $\mu V$ , a: 35–35 ms, b: 66–66 ms a: 22–10 $\mu V$ , b: 58–61 $\mu V$ a: 27–27 ms, b: 51–51 ms Flicker: 64–65 $\mu V$ , 43–44 ms.

Table 1. (Continued)

Family, Patient, Gender	Age at Onset	Initial Visual Acuity RE/LE Age	Final Visual Acuity, RE/ LE Age	Near Vision Aids	Nystagmus	Night Blindness	Initial GVF RE/ LE, Final GVF RE/LE	Narrowed Vessels	Bone Spicules	Macular Edema, Foveal Thickness FAF Annular Ring FAF Hypo- or Hyperautofluorescence Peripheral Spots	Dark-Adapted 3 ERG a, b waves: Amplitudes in $\mu$ V, a, b waves: Implicit times in ms, RE-LE Light-Adapted 3 ERG a, b waves: Amplitudes in $\mu$ V, a, b waves: Implicit times in ms, RE-LE Light-Adapted 30Hz Flicker ERG Amplitude and Implicit time RE, LE
Family 3, II.4, M	8	HM HM 57	No Follow-up	Yes FD	Yes	Yes FD	40°N, 30°S, 50°T, 60°I 50°N, 50°S, 60°T, 50°I	Yes	No	No 247 $\mu$ -223 $\mu$ Yes Yes	a: 19-67 $\mu$ V, b: 92-131 $\mu$ V, a: 41-37 ms, b: 71-71 ms a: 28-5 $\mu$ V, b: 88-86 $\mu$ V a: 29-27 ms, b: 57-56 ms Flicker: 80-68 $\mu$ V, 34-34 ms. Not detectable Not detectable
II.5, M	5	LP LP 60	LP LP 64	Yes FD	Yes	Yes FD	Tubular 15° Tubular 8°	Yes	Yes	Edema RE 277 $\mu$ LE Yes Yes	
III.2, F	5	20/400 20/400 25	No Follow-up	Yes FD	Yes	Yes FD	50°N, 40°S, 60°T, 50°I 50°N, 40°S, 75°T, 60°I	Yes	Yes	No 228 $\mu$ -224 $\mu$ Yes Yes	a: 62-57 $\mu$ V, b: 89-69 $\mu$ V, a: 11-13 ms, b: 46-47 ms a: 7-26 $\mu$ V, b: 49-56 $\mu$ V a: 16-15 ms, b: 36-35 ms Flicker: 60-60 $\mu$ V, 34-35 ms.

(continued on next page)

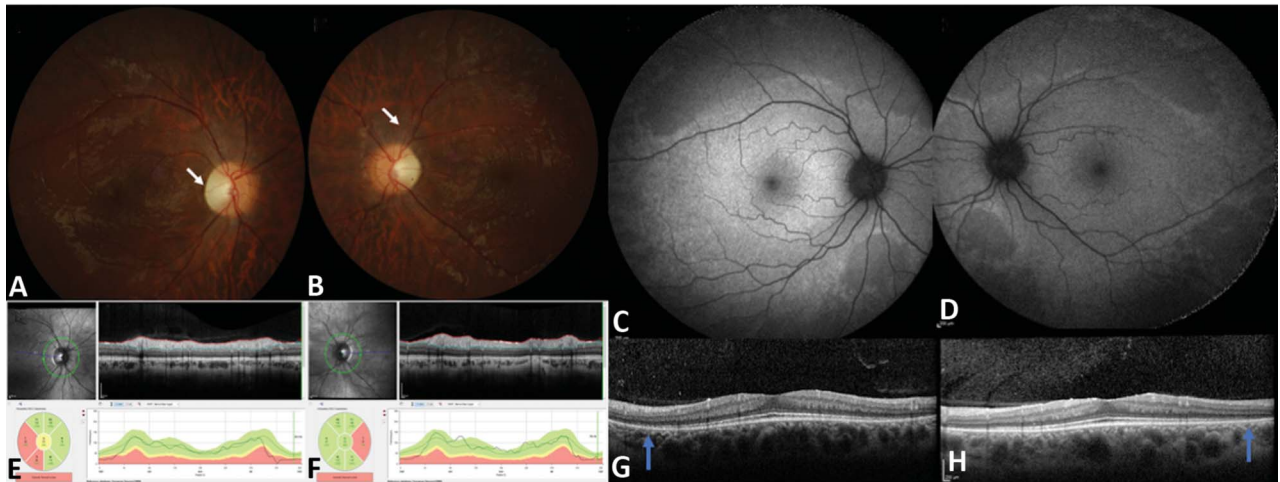


Table 1. (Continued)

Family, Patient, Gender	Age at Onset	Initial Visual Acuity RE/LE Age	Final Visual Acuity, RE/ LE Age	Near Vision Aids	Nystagmus	Night Blindness	Initial GVF RE/ LE, Final GVF RE/LE	Narrowed Vessels	Bone Spicules	Macular Edema, Foveal Thickness FAF Annular Ring FAF Hypo- or Hyperautofluorescence Peripheral Spots	Dark-Adapted 3 ERG a, b waves: Amplitudes in $\mu$ V, a, b waves: Implicit times in ms, RE-LE Light-Adapted 3 ERG a, b waves: Amplitudes in $\mu$ V, a, b waves: Implicit times in ms, RE-LE Light-Adapted 30Hz Flicker ERG Amplitude and Implicit time RE, LE
Family 4, II.2, F	0.5	20/400 20/400 12	20/400 20/400 14	Yes FD	Yes	Yes FD	ND	Yes	No	No 216 $\mu$ –222 $\mu$ Yes Yes	a: 49-ND $\mu$ V, b: 99-ND $\mu$ V a: 41-ND ms, b: 64-ND ms a: 1-ND $\mu$ V, b: 37-ND $\mu$ V a: 23-ND ms, b: 56-ND ms Flicker: 40- ND $\mu$ V, 34-ND ms.
II.3, F	0.5	20/200 20/400 10	20/200 20/400 12	Yes FD	Yes	Yes FD	ND	Yes	No	No 241 $\mu$ –248 $\mu$ Yes Yes	a: 44-ND $\mu$ V, b: 93-ND $\mu$ V a: 38-ND ms, b: 66-ND ms a: 9-ND $\mu$ V, b: 38-ND $\mu$ V a: 24-ND ms, b: 53-ND ms Flicker: 44- ND $\mu$ V, 35-ND ms.

Normal ISCEV Ff-ERG values in our clinical national center: Dark-adapted 3 ERG, b-wave > 200  $\mu$ V, median implicit time 58 milliseconds. Light-adapted 3 ERG, b-wave > 60  $\mu$ V, median implicit time 45 milliseconds. Light-adapted 30 Hz Flicker ERG amplitude > 80  $\mu$ V, implicit time 30 milliseconds.

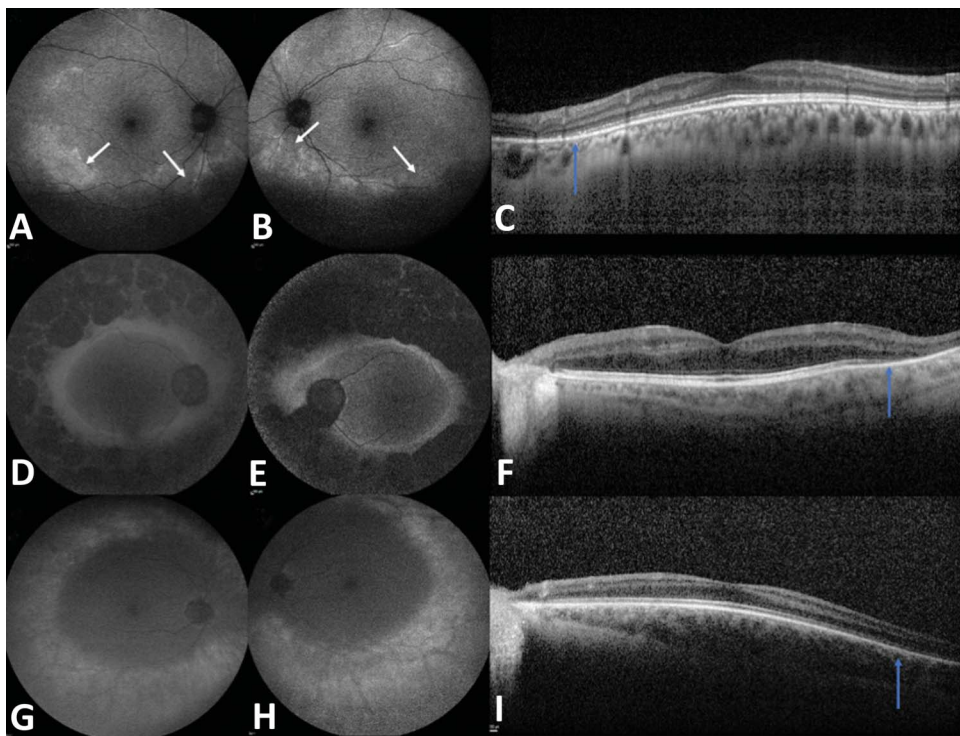
EZ, ellipsoid line; FD, first decade; GVF, Goldmann visual field; HM, hand motion; LE, left eye; LP, light perception; ND, not done; RE, right eye; ms, milliseconds.



**Fig. 2.** Combined optic atrophy and retinitis pigmentosa in a 23-year-old woman. This patient reported a visual loss since the age of 6 years because of the optic atrophy and night blindness since the first decade of life. Visual acuity is 20/63 in the right eye and 20/100 in the left eye. **A** and **B**. Color fundus imaging with temporal papillary pallor (**A**, white arrow) and narrow retinal vessels (**B**, white arrow). **C** and **D**. Fundus autofluorescence frames disclose an area of increased autofluorescence, affecting the entire posterior pole including the retina around the optic nerve head. **E** and **F**. SD-OCT examination disclose a severe decrease of the temporal RNFL thickness in both eyes (32 and 35  $\mu$ m). **G** and **H**. SD-OCT scan showing the loss of photoreceptors outside the fovea, with a thinning of the outer nuclear layer and the loss of the external limiting membrane and the ellipsoid line (blue arrows). These anomalies do not explain per se the severity of the visual loss, as the foveal retinal layers are preserved in both eyes.

early childhood, a progressive rod-cone dystrophy is systematically present. This phenotype was never described before, most probably because this retinal damage was not preminent in these visually impaired people. The *RTN4IP1* c.308 G > A (p.R103H) mutation is the most frequent variant causing ROA, with a founder

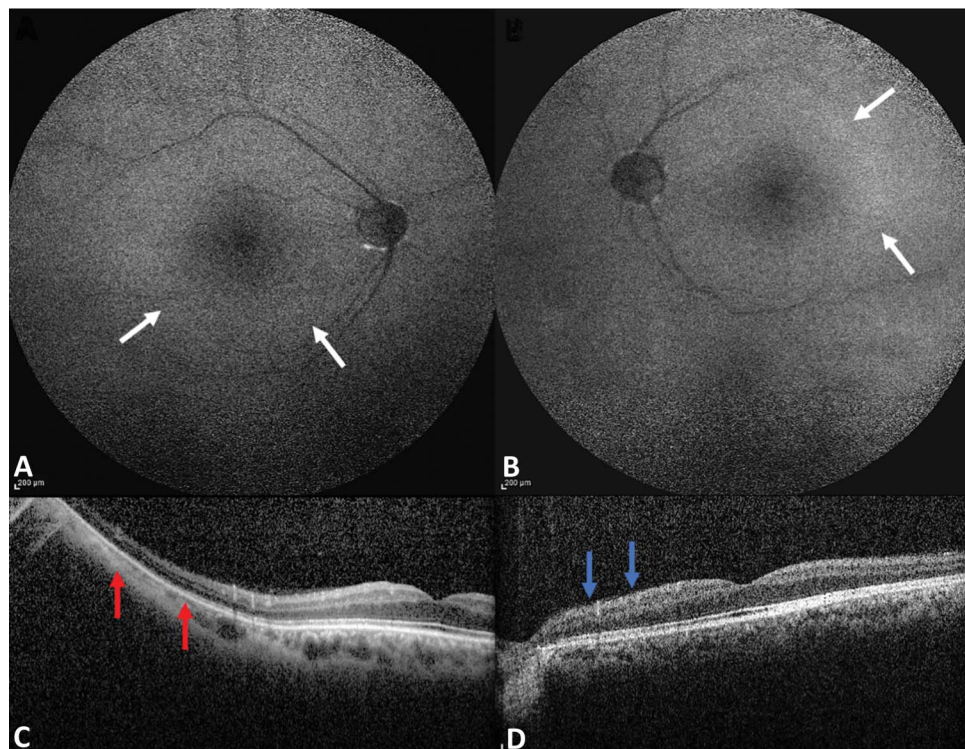
effect in the Roma population, and encountered here in the four families. Importantly, of the four individuals who had exome sequencing, none disclosed mutation in a gene responsible for a rod-cone dystrophy, thus excluding a coincidental fortuitous cosegregation of the two ophthalmological diseases. In addition, the fact that



**Fig. 3.** Rod-cone dystrophy associated to the ROA. Fundus autofluorescence imaging (**A** and **B**, **D** and **E**, **G** and **H**) and SD-OCT macular scans (**C**, **F**, and **I**) of three affected patients, II.3 Family 1 (**A**, **B**, and **C**), II.5 Family 3 (**D**, **E**, and **F**), and II.2 Family 4 (**G**, **H**, and **I**), illustrate the rod-cone dystrophy. All had a visual loss during the first decade caused by the ROA. FAF examination reveal peripheral areas of increased autofluorescence in Patient II.3 from Family 1 and Patient II.2 from Family 4, with a relatively preserved signal at the posterior pole. The Patient II.5 from Family 3 (**D** and **E**) has multiple patches of absent FAF outside the vascular arcades in both eyes. SD-OCT show preserved retinal layers within the fovea in all patients, but the loss of the ellipsoid and interdigitating lines, with severe thinning of the outer nuclear layers outside of the macular area. Blue arrows indicate the transition between the preserved foveal layers and the peripheral retinal segmentation anomalies (**C**, **F**, and **I**).



**Fig. 4.** Severe optic atrophy combined to retinitis pigmentosa in a 57-year-old man. This Patient II.4 from Family 3 had low vision (perception of hand motion) and a nystagmus since his first year of life, while visual difficulty in low luminance conditions was not a preeminent complain, far beyond the day-light poor vision. **A** and **B.** FAF reveals a circular and tinny region with moderate increased fluorescence (white arrows) and narrow retinal vessels. **C** and **D.** SD-OCT reveals a total disappearance of the papillomacular bundle in line with the severity of the optic atrophy (blue arrows) and on temporal retinal scans the complete loss of the external limiting membrane and the ellipsoid zone and interdigitation zone lines (red arrows), with an important thinning of the outer nuclear layer. Like in all affected cases, macular abnormalities cannot cause the central visual loss.



the neurological syndromic presentation of the two sisters from Family 4 is related to mutations involving haplotypes different from the first three families further exclude that the two ophthalmological diseases are related to different genes cosegregating in the seven patients described here. Thus, we can firmly propose that the ROA and the rod–cone dystrophy are related specifically to the *RTN4IP1* biallelic mutations.

#### *Combined Recessive Optic Atrophy and Rod Cone Dystrophy: A New Story*

Inherited optic atrophies sharing a mitochondrial impairment are all characterized by bilateral and symmetrical retinal ganglion cells loss, mainly those of the papillomacular bundle. This loss of central retinal ganglion cells explains why sometimes it is challenging to state if a loss of visual acuity is related to an inherited optic neuropathy or to a macular dystrophy, whereas in some very specific cases, as carriers of *NMNAT1* mutations affecting the NAD biosynthesis, both alterations can occur simultaneously during the first years of life, resulting to early blindness.<sup>17</sup> The association of an inherited optic neuropathy to a retinal dystrophy is also found in few other mitochondrial diseases, such as the infantile cerebellar retinal degeneration<sup>18</sup> related to biallelic *ACO2* mutations, in the mitochondrial myopathy, encephalopathy, lactic acidosis, and stroke-like episodes syndrome (MELAS), because of a respiratory chain

Complex I deficiency and in the Kearns–Sayre syndrome (KSS), because of the presence of large mitochondrial genome deletions.<sup>19</sup> In these syndromic diseases, the retina is entirely and severely affected, suggesting that dysfunction of the retinal pigmentary epithelium is the primary causative mechanism responsible for secondary rod and cone loss. This is distinguishable from the association of an early dominant optic atrophy to a late-onset rod–cone dystrophy, described recently in few individuals with a heterozygous *SSBP1* mutation,<sup>20</sup> where only photoreceptors appears to be affected. The chronology of retinal alterations is the same with the *RTN4IP1* patients, disclosing an early onset optic nerve atrophy responsible for the visual acuity loss, followed by the onset of a rod–cone dystrophy, although in Family 3, individuals II.5 and III.2 were referred initially with the diagnosis of a rod–cone dystrophy, with night blindness since early childhood, a tubular visual field for the father, a ring scotoma for the daughter, narrowed vessels, papillary pallor, typical peripheral pigmentary changes, and reduced rod and cone responses on full-field ERG. Nevertheless, it is quite unusual that in the natural history of an isolated rod–cone dystrophy, a visual loss occurs before the night blindness and the peripheral visual field abnormalities. In the same way, their visual loss could not be explained by the macular SD-OCT analysis with preserved ellipsoid line and expansion of the outer nuclear layer within the macula.

In summary, *RTN4IP1* ophthalmological presentation is at a first stage defined by an early onset and severe optic atrophy, with near vision difficulties worsening with time, leading in most cases to legal blindness. In a second stage, a rod-cone dystrophy will occur that can be easily identified in patients with peripheral pigmentary changes but eventually undiagnosed in others, despite an early night blindness and reduced b-wave amplitude of rod responses on ISCEV Ff-ERG. Taking into account that this rod-cone dystrophy has been undiagnosed in all previous published cases, we recommend that all patients with optic nerve atrophy should not only have RNFL analyses and macular scans but also systematically widefield FAF and OCT scans of the temporal part of the macular zone.

**Key words:** inherited optic neuropathy, recessive disease, rod-cone dystrophy, *RTN4IP1*.

### Acknowledgments

The authors thank all the family members who participated to this study.

### References

1. Yu-Wai-Man P, Griffiths PG, Chinnery PF. Mitochondrial optic neuropathies - disease mechanisms and therapeutic strategies. *Prog Retin Eye Res* 2011;30:81–114.
2. Yu-Wai-Man P, Newman NJ. Inherited eye-related disorders due to mitochondrial dysfunction. *Hum Mol Genet* 2017;26:R12–R20.
3. Lenaers G, Hamel C, Delettre C, et al. Dominant optic atrophy. *Orphanet J Rare Dis* 2012;7:46.
4. Kane MS, Alban J, Desquiret-Dumas V, et al. Autophagy controls the pathogenicity of OPA1 mutations in dominant optic atrophy. *J Cell Mol Med* 2017;21:2284–2297.
5. Cohn AC, Toomes C, Potter C, et al. Autosomal dominant optic atrophy: penetrance and expressivity in patients with OPA1 mutations. *Am J Ophthalmol* 2007;143:656–662.
6. Puomila A, Huoponen K, Mäntyjärvi M, et al. Dominant optic atrophy: correlation between clinical and molecular genetic studies. *Acta Ophthalmol Scand* 2005;83:337–346.
7. Chun BY, Rizzo JF. Dominant optic atrophy: updates on the pathophysiology and clinical manifestations of the optic atrophy 1 mutation. *Curr Opin Ophthalmol* 2016;27:475–480.
8. Ham M, Han J, Osann K, et al. Meta-analysis of genotype-phenotype analysis of OPA1 mutations in autosomal dominant optic atrophy. *Mitochondrion* 2019;46:262–269.
9. Nasca A, Rizza T, Doimo M, et al. Not only dominant, not only optic atrophy: expanding the clinical spectrum associated with OPA1 mutations. *Orphanet J Rare Dis* 2017;12:89.
10. Toomes C, Marchbank NJ, Mackey DA, et al. Spectrum, frequency and penetrance of OPA1 mutations in dominant optic atrophy. *Hum Mol Genet* 2001;10:1369–1378.
11. Gerber S, Ding MG, Gérard X, et al. Compound heterozygosity for severe and hypomorphic NDUFS2 mutations cause non-syndromic LHON-like optic neuropathy. *J Med Genet* 2017;54:346–356.
12. Metodiev MD, Gerber S, Hubert L, et al. Mutations in the tricarboxylic acid cycle enzyme, aconitase 2, cause either isolated or syndromic optic neuropathy with encephalopathy and cerebellar atrophy. *J Med Genet* 2014;51:834–838.
13. Angebault C, Guichet PO, Talmat-Amar Y, et al. Recessive mutations in *RTN4IP1* cause isolated and syndromic optic neuropathies. *Am J Hum Genet* 2015;97:754–760.
14. Hanein S, Perrault I, Roche O, et al. TMEM126A, encoding a mitochondrial protein, is mutated in autosomal-recessive nonsyndromic optic atrophy. *Am J Hum Genet* 2009;84:493–498.
15. Sharkia R, Wierenga KJ, Kessel A, et al. Clinical, radiological, and genetic characteristics of 16 patients with ACO2 gene defects: delineation of an emerging neurometabolic syndrome. *J Inherit Metab Dis* 2019;42:264–275.
16. Charif M, Nasca A, Thompson K, et al. Neurologic phenotypes associated with mutations in *RTN4IP1* (OPA10) in children and young adults. *JAMA Neurol* 2018;75:105–113.
17. Perrault I, Hanein S, Zanlonghi X, et al. Mutations in *NMNAT1* cause Leber congenital amaurosis with early-onset severe macular and optic atrophy. *Nat Genet* 2012;44:975–977.
18. Spiegel R, Pines O, Ta-Shma A, et al. Infantile cerebellar-retinal degeneration associated with a mutation in mitochondrial aconitase, ACO2. *Am J Hum Genet* 2012;90:518–523.
19. Kisilevsky E, Freund P, Margolin E. Mitochondrial disorders and the eye. *Surv Ophthalmol* 2020;65:294–311.
20. Jurkute N, Leu C, Pogoda HM, et al. SSBP1 mutations in dominant optic atrophy with variable retinal degeneration. *Ann Neurol* 2019;86:368–383.