



HAL
open science

Optic nerve involvement in CACNA1F-related disease: observations from a multicentric case series

Elisa Marziali, Filip van den Broeck, Sara Bargiacchi, Pina Fortunato,
Roberto Caputo, Andrea Sodi, Julie de Zaeytijd, Vittoria Murro, Dario
Pasquale Mucciolo, Dario Giorgio, et al.

► To cite this version:

Elisa Marziali, Filip van den Broeck, Sara Bargiacchi, Pina Fortunato, Roberto Caputo, et al.. Optic nerve involvement in CACNA1F-related disease: observations from a multicentric case series. *Ophthalmic Genetics*, 2022, pp.1 - 11. 10.1080/13816810.2022.2132514 . hal-03965321

HAL Id: hal-03965321

<https://cnrs.hal.science/hal-03965321>

Submitted on 31 Jan 2023

HAL is a multi-disciplinary open access archive for the deposit and dissemination of scientific research documents, whether they are published or not. The documents may come from teaching and research institutions in France or abroad, or from public or private research centers.

L'archive ouverte pluridisciplinaire **HAL**, est destinée au dépôt et à la diffusion de documents scientifiques de niveau recherche, publiés ou non, émanant des établissements d'enseignement et de recherche français ou étrangers, des laboratoires publics ou privés.

Public Domain

Optic nerve involvement in *CACNA1F*-related disease: observations from a multicentric case series

Elisa Marziali a†, Filip Van Den Broeckb†, Sara Bargiacchic, Pina Fortunatoa, Roberto Caputoa, Andrea Sodik, Julie De Zaeytjdb, Vittoria Murrod, Dario Pasquale Mucciolo d, Dario Giorgiod, Ilaria Passerinie, Viviana Palazzoc, Peluso Francescaf, Elfride de Baere g, Christina Zeitzh, Bart P. Leroy b,g,i, Jacopo Seccia, and Giacomo M. Baccia

aPediatric Ophthalmology Unit, Meyer Children's Hospital, University of Florence, Florence, Italy; bDepartment of Ophthalmology and Center for Medical Genetics Ghent, Ghent University Hospital, Ghent, Belgium; cMedical Genetics Unit, Meyer Children's Hospital, University of Florence, Florence, Italy; dDepartment of Neuroscience, Psychology, Drug Research and Child Health, University of Florence, Florence, Italy; eDepartment of Genetic Diagnosis, Careggi Teaching Hospital, Florence, Italy; fMedical Genetics Unit, Azienda USL-IRCCS di Reggio Emilia, Reggio Emilia, Italy; gCenter for Medical Genetics, Ghent University and Ghent University Hospital, Ghent, Belgium; hINSERM, CNRS, Institut de la Vision, Sorbonne Université, Paris, France; iDivision of Ophthalmology and Center for Cellular and Molecular Therapeutics, Inc, Children's Hospital of Philadelphia, Philadelphia, PA, USA

†These authors have contributed equally to this work.

INTRODUCTION

During the last few years, there has been an increased scientific interest in rare eye diseases¹ due to improvements in molecular diagnosis, advances in deep phenotyping and recent developments in gene therapy. Among these, inherited retinal disorders have been the focus of multiple studies that help shed light on pathogenesis and new phenotypic aspects. These phenotypical details are important to help physicians decide on the most appropriate diagnostic approach and development of future treatments^{2,3}.

The *CACNA1F* gene (MIM#300110) is located on the short arm of the X-chromosome at band Xp11.23 and consists of 48 exons. It encodes a multipass transmembrane protein that functions as the pore-forming $\alpha 1F$ subunit of a L-type voltage-gated calcium channel, Cav1.4, which mediates the influx of calcium ions into the cell, and is expressed within the rod and cone active zones in the outer plexiform layer⁴. Calcium influx via these channels mediates glutamate release at different luminance levels at the presynaptic terminals of the photoreceptor-bipolar cell synapse. Abnormalities of these channels due to mutations of *CACNA1F* generally lead to symptoms of night blindness and/or photophobia⁴. In addition, decreased scotopic and photopic b-wave amplitudes on the full-field flash electroretinogram (ERG) lead to an electronegative aspect of the scotopic combined rod-cone response known as a Schubert-Bornschein ERG⁵.

Pathogenic mutations in *CACNA1F* have been identified in patients with various X-linked eye disorders, including the Miyake incomplete type of Congenital Stationary Night Blindness (CSNB type 2A)⁵, Åland Island Eye Disease (AIED)⁶, cone-rod dystrophy 3 (CORDX3)⁷ and even X-linked retinitis pigmentosa (XLRP)⁸. These findings indicate a considerable phenotypic heterogeneity associated with *CACNA1F* mutations.

The spectrum of *CACNA1F* pathogenic variants reported in the literature comprises missense, nonsense, and splice- site variants (most affect canonical splice acceptor or donor sites), small insertions and deletions, large deletions, and complex rearrangements, with most patients carrying missense or nonsense variants.

Congenital stationary night blindness (CSNB) denotes a group of non-progressive retinal disorders characterized by vision disturbances at night and in dim light conditions or by a delayed adaptation to darkness, poor visual acuity (20/200 to 20/30), varying degrees of myopia, nystagmus, and/or strabismus, but normal color vision and no fundus abnormalities except for myopic changes in some. A subgroup of CSNB, namely CSNB2 or Myake incomplete CSNB (iCSNB)⁹, usually present with night vision troubles, low best corrected visual acuity (BCVA), varying degrees of refractive error, nystagmus, light sensitivity, and the characteristic electronegative waveform on the dark adapted responses to a 3.0 and 10.0 cd.s/m² stimulus on a full-field flash ERG (FF-ERG). Abnormalities at the presynaptic level of the rod ON- and cone ON- and OFF-pathways give rise to reduced scotopic and photopic b-waves and 30 Hz flicker responses. Photopic responses to a long-duration flash separates ON- from OFF-responses and helps making a correct diagnosis. CSNB2 can be particularly difficult to diagnose due to the heterogeneity of its phenotypic manifestations and the relatively low incidence⁵. Indeed, patients may complain more of photophobia than night blindness, making the correct diagnosis often challenging without an extended FF-ERG.

AIED is a very rare disease characterized by fundus hypopigmentation, foveal hypoplasia, decreased visual acuity, progressive axial myopia, latent nystagmus, astigmatism, night blindness and a possible defect in protan color vision. Hypopigmentation is usually more pronounced at the posterior pole and in the

peripapillary region. Female carriers may present with moderate color vision disturbances and mild nystagmus¹⁰.

Interestingly, although these diseases are typically non-progressive, progressive diseases, such as cone-rod dystrophies and rod-cone dystrophies (i.e. XLRP), have also been associated with the mutational spectrum of the *CACNA1F* gene⁸.

Herein, we describe a case series of 12 patients from 11 unrelated families with *CACNA1F*-related ocular disease with a peculiar phenotype. In addition to the more common retinal findings, we also characterize, for the first time, visual pathway abnormalities in a large series of patients with *CACNA1F*-related disease.

MATERIALS AND METHODS

The study was conducted in a multicentric fashion between the Pediatric Ophthalmology department of Meyer Children's Hospital, Florence, the Ophthalmology Department of Careggi University Hospital, Florence, and the Department of Ophthalmology of Ghent University Hospital, Belgium.

For Meyer Children's Hospital, all patients affected by pathogenic mutations in *CACNA1F* gene were included while for Ghent and Careggi University Hospitals only patients with pRNFL assessment were included. Molecular diagnostic testing was performed at the Department of Genetic Diagnosis at Careggi Teaching Hospital, Florence, Italy for the Italian patients and at the Center for Medical Genetics of Ghent University Hospital, Ghent, Belgium or at the Institut de la Vision, Sorbonne Université, Paris, France, for the Belgian patients. Diagnostic testing was performed only after genetic counselling by a certified clinical geneticist. Written informed consent was obtained from the parents and/or the patient before a blood sample for genetic testing was acquired. Genomic DNA was extracted from peripheral blood by standard methods.

Whole exome sequencing (WES, HiSeq 1000 or HiSeq 3000 or NovaSeq 6000, Illumina Inc., San Diego, CA, USA and SureSelectXT Low Input Human All Exon V7 kit, Agilent Technologies Inc., Santa Clara, CA, USA or SeqCap EZ Exome v3 Nimblegen, Roche, Basel, Switzerland) was performed on DNA from patients 1, 2, 3, 8 and 9 while patients 4, 5, 6 and 7 were analyzed using a targeted next generation sequencing (NGS) custom panel (NextSeq 500, Illumina Inc., San Diego, CA, USA and SureSelect Target Enrichment, Agilent Technologies Inc., Santa Clara, CA, USA) containing genes responsible for retinal dystrophies. The DNA of patients 10, 11 and 12 was analyzed extramurally in research context at the Institut de la Vision, Sorbonne Université, Paris, France. Variant filtering was performed as previously described¹¹. Variants identified by NGS/WES were validated by Sanger sequencing.

The data collected from the medical records consisted of the medical history and the ophthalmological assessments, including best-corrected visual acuity (BCVA) evaluations (using age appropriate ETDRS or Snellen charts), cycloplegic refraction, ocular motility assessment, color vision evaluation using the Ishihara and for some Hardy-Rand-Rittler pseudo-isochromatic (PIC) plates, in addition to the saturated Farnsworth Panel D-15 test, anterior segment biomicroscopy, and dilated fundus examination.

Spectral Domain Optical Coherence Tomography (SD-OCT) imaging was performed using either the Heidelberg OCT Spectralis system (Heidelberg Engineering GmbH, Heidelberg, Germany) or the hand-held iVue system (Optovue Inc., Fremont, CA, USA). The latter is a handheld device which allows one to obtain high quality scans of the retina and optic nerve head also in uncooperative patients in whom an evaluation under anesthesia (EUA) is required. As soon as patients reached an age at which they became

cooperative, the Heidelberg OCT Spectralis system was used. For Meyer Children's Hospital, due to the specific pediatric setting with serial examinations at early age points, only the most recent evaluation was performed with SD-OCT Spectralis. Different types of acquisitional modes were used, depending on the device, to assess the peripapillary nerve fiber layer (pRNFL) and ganglion cell complex/ganglion cell layer - inner plexiform layer (GCC/GCL-IPL) thickness.

Additional examinations included color fundus photography (TRC-NW400, TRC-IX50 and TRC-DX50, Topcon Medical System Inc., Oakland, NJ, USA) and Goldmann kinetic perimetry.

Full-field standard electroretinography (ff-ERG; Retimax; CSO, Florence, Italy & RETI-port/scan 21, Roland Consult, Brandenburg an der Havel, Germany) was performed according to the ISCEV (International Society for Clinical Electrophysiology of Vision) guidelines¹² with either extended protocols or abbreviated protocols under anesthesia for uncooperative patients.

Most patients underwent magnetic resonance imaging (MRI) of the brain which allowed for a detailed examination of the optic pathways.

This study adhered to the tenets of the Declaration of Helsinki and was approved by the local ethical committee of each participating center. Adult patients or the legal guardian(s) of minors provided written informed consent after explanation about the nature of the study. If patients have become adults, they have signed first-person consent to the study. In this paper, patients are identified using an anonymous ID number.

RESULTS

This series of patients had a mean follow-up of 11,63 years (range 6-18 years). All patients presented with bilateral, decreased, best-corrected visual acuities that remained stable from the first until the last visit. MRI scan was unremarkable for anatomic abnormalities along pre and post geniculate visual pathways. Spectral domain optical coherence tomography showed a low mean pRNFL thickness in both eyes of all patients (see Table 1). Structural macular OCT scans were unremarkable for all patients except for patients 1 and 2, in whom a degree of foveal hypoplasia was observed. Bilateral longitudinal pRNFL data (1,2 to 6 years follow up) were available for 7 patients and showed no substantial change in pRNFL thickness over the years. In all patients who underwent an electroretinography, it showed the negative configuration of the scotopic combined rod-cone responses. A summary of the clinical and molecular data of all patients is presented in Table 1 and 2 respectively. A detailed case description is provided for the pediatric patients for whom longitudinal assessment of the pRNFL thickness was available.

Case Description

Case 1 and 2

The first two cases are siblings with a history of uneventful pregnancy and delivery. The eldest (Case 1) was referred to the pediatric ophthalmology unit at age three because of difficulties with fixation and following. A high myopia of -10.00 D OU, intermittent exotropia and low best-corrected visual acuity were the main findings together with diffuse hypopigmentation of the retinal pigment epithelium (RPE) and myopic changes on fundus examination. Because of behavioral problems, additional testing was not possible, and he was followed up with periodic clinical assessments. Myopia increased progressively with age and reached a spherical equivalent of -21 D OU at age 15. BCVA

remained stable at 0.5 LogMAR and the family had been noticing signs of mild night blindness and severe photophobia since early childhood, the latter could be relieved with yellow tinted glasses. The youngest (Case 2) was then referred for pediatric ophthalmologic assessment at 8 months of age because of the severe phenotype of his elder brother. The first evaluation was unremarkable, but myopia set in rapidly when he was one year of age and increased to -6.00D at age three and a spherical equivalent (SE) of -17.00 D was found at age 14. The structural and functional phenotype of the younger brother ended up being very similar to the one of the older brother. Electroretinography was done under anesthesia for both siblings because of behavioral problems: low amplitude responses in both photopic and scotopic tests were recorded, and a clear electronegative waveform was evident in the combined rod-cone response. SD-OCT scan showed a degree of bilateral foveal hypoplasia and bilateral low pRNFL and GCC thickness (Figure 1, patient 1 and Figure 2, patient 2). Brain MRI with special attention to the optic pathways was unremarkable. Whole Exome Sequencing analysis was carried out and a pathogenic, hemizygous, germline *CACNA1F* variant (c.3470A>G, already reported in literature¹³) was identified in both brothers, while the mother was proven to be an unaffected carrier. Both phenotypes were recorded as atypical Åland Island Eye Disease due to the optic neuropathy signs.

Case 3

The patient was referred to the pediatric ophthalmology unit for bilateral, reduced visual acuity and intermittent exotropia at 7 years of age. A BCVA of 0.3 logMAR, mild myopic astigmatism of -2.50 D and a mild diffuse pallor of the optic nerve heads were the main findings. SD-OCT scan showed bilateral pRNFL and GCC thickness below normal, with an otherwise structurally normal retina (Figure 3). Color vision as assessed by Ishihara PIC plates and saturated Farnsworth Panel D-15 was normal. Goldmann visual

fields and a brain MRI scan were unremarkable. Since the family reported mild trouble in night vision since early childhood, an ISCEV-standard ERG was performed, and showed slightly preserved rod and cone function with an electronegative waveform of the scotopic, combined rod-cone response. Serial OCT scans showed stable pRNFL and GCC thickness values over five years of follow-up. Whole Exome Sequencing analysis was carried out and a pathogenic, hemizygous, germline *CACNA1F* variant (c.2071C>T, already reported in literature¹⁴) was found, with segregation confirmed in the unaffected carrier mother. The phenotype was recorded as atypical congenital stationary night blindness due to the presence of a stable optic neuropathy.

Case 4

The patient was referred for evaluation to the pediatric ophthalmology unit at 7 years of age because of high myopia and low visual acuity. Subnormal BCVA (0.5 logMAR in the right eye and 0.4 logMAR in the left eye), high myopia OU with a spherical equivalent of -10.00D and small angle esotropia were the main findings at first evaluation. Due to the presence of night blindness from an early age, a complete ophthalmic evaluation was required. The anterior segment assessment was unremarkable and indirect fundus examination showed only mild myopic changes. SD-OCT showed bilateral low pRNFL and GCC thickness with preserved structural macular segmentation (Figure 4). Goldmann visual field testing was unremarkable and color vision was normal as assessed by Ishihara PIC plates and saturated Farnsworth Panel D-15 test. Electrophysiology testing showed low amplitude rod- and cone-specific responses on ISCEV-standard ERG, with an electronegative aspect of combined DA 3.0 protocol.

Next Generation Sequencing analysis (retinal dystrophy panel) was carried out and a pathogenic, hemizygous germline *CACNA1F* variant (c.3975+2T>C, already reported in

literature¹⁵) was found, while the mother is an unaffected carrier. The phenotype was recorded as atypical congenital stationary night blindness due to the presence of stable optic neuropathy.

Case 5

The patient was referred for low bilateral visual acuity at the age of 8 years. He had already been followed up for 7 years at the time of data collection. Over time, BCVA remained stable at 20/50 and 20/40 in the right and left eye respectively. Anterior segment, IOP and fundus indirect examination were unremarkable since the first visit. Goldmann visual fields and MRI scan were unremarkable as were structural macular SD-OCT scans. Peripapillary nerve fiber layer and ganglion cells layer complex were markedly reduced in both eyes but no signs of progression were noticed throughout 6 years of follow-up. ISCEV-standard ERGs showed an electronegative combined DA 3.0 rod-cone response.

Next Generation Sequencing analysis showed a pathogenic, hemizygous, null variant in *CACNA1F*, c.2739del, also present in the healthy mother. This variant has not been previously described in literature, but it can be considered pathogenic following ACMG guidelines (PVS1, PM2, PP3) because it's absent from GnomAD (Genome Aggregation Database) and causes a frameshift likely resulting in a premature stop codon. The phenotype was coherent with atypical CSNB due to the presence of stable optic neuropathy.

Case 9

This patient was referred to the pediatric ophthalmology unit at age 9 because of a long history of reduced best-corrected visual acuity. A BCVA of 0.7 logMAR OD and 0.4 OS, myopia OU with a spherical equivalent of -3,00 D and small angle esotropia OD were the

main findings at first evaluation. At the time, this patient's clinical picture was suspicious for functional vision loss because BCVA was highly variable on repeat measurements in the context of behavioral problems. Remarkably, using the Thibaudet test a BCVA of 0 logMAR was recorded in the left eye while the right remained at 0.7 logMAR, which was considered due to amblyopia. Psychological and neurological examinations including an MRI of the brain were carried out and were normal. At age 18 he was referred to the ophthalmic genetics department because of optic disc pallor. SD-OCT assessment showed GCC thinning and bilateral temporal thinning of the pRNFL. Goldmann visual field showed slightly decreased pericentral sensitivity. Color vision testing showed a few red-green errors on Ishihara and Hardy Rand Ritter plates while the Panel D15 test was normal. FF-ERG showed the typical electronegativity in the left eye with artifacts precluding proper interpretation in the right eye. These findings were shown to be stable over three years of follow up. Autosomal dominant optic atrophy was considered first in the differential diagnosis. When OPA1 screening proved to be negative, subsequent WES revealed a hemizygous *CACNA1F* variant (c.1537C>T, already reported in the literature). The mother was shown to be an unaffected carrier.

Case 11

This patient was referred to the pediatric ophthalmology unit at age 13 because of subnormal BCVA present since childhood. A BCVA of 0.2 logMAR OD and of 0.4 logMAR OS and myopia of -6.5 D OU spherical equivalent were recorded. SD-OCT at this time showed a thinner than normal pRNFL and fundoscopy showed optic disc pallor. Color vision was normal and Goldmann visual field testing showed a slightly decreased pericentral sensitivity. The ERG showed possible electronegativity but was unclear due to artefacts. All these findings were shown to remain stable over the following 5 years of follow up. At age 15, an MRI of the brain was carried out and showed no abnormalities.

CACNAIF screening showed a hemizygous *CACNAIF* variant (c.2118+1G>A, already reported in the literature). The mother was confirmed to be an unaffected carrier.

DISCUSSION

Several reports on the clinical manifestations of *CACNAIF*-related diseases have been published during the last decade, but only a few papers have focused on the optic pathways. In 2003, Nakamura *et al.*¹⁶ described two brothers with a *CACNAIF* mutation (c.271_274del) and progressive decline in visual function in combination with retinal and optic nerve atrophy. In 2018, Pasutto¹⁷ reported a case of a young boy with signs of early-onset optic neuropathy and a *CACNAIF* truncating mutation (c.3895C>T). Evidence of the expression of *CACNAIF* gene in the retinal outer nuclear layer, inner nuclear layer and ganglion cell layer was reported in a murine orthologue by Naylor *et al.* in 2000¹⁸. Moreover, another murine model of a *CACNAIF*-related CSNB2 null phenotype, clearly demonstrated the presence of a disorganized intraretinal synaptic network characterized by ectopic bipolar and horizontal cell dendrites altering the response of retinal ganglion cells¹⁹. Finally, in 2005 Ung *et al.*²⁰ linked CSNB phenotypes to optic nerve misrouting, although they failed to correlate mutations in *CACNAIF* gene to this feature. Although we did not explore misrouting of optic nerve fibers in our CSNB2 patients, the findings mentioned above raise the question of how abnormal optic pathway development might either be part of or be related to the phenotype of CSNB.

Since the classical clinical diagnosis of *CACNAIF*-related ocular disease is based mainly on patient history and functional retinal findings, clinicians usually focus their attention only on identifying the retinal phenotype. In a clinical setting, the optic nerve head

generally does not attract the clinician's attention, unless a strikingly abnormal appearance of it leads to further assessment of the visual pathways.

Our case series suggests that childhood-onset optic nerve involvement could be a major finding in the *CACNA1F*-phenotypical spectrum, but it would be necessary to perform a thorough evaluation of the optic pathways in a larger number of patients to accurately correlate this abnormality to *CACNA1F* mutations. Our conviction is that *CACNA1F* could be involved in the development and maintenance of the optic pathways in direct or indirect ways that are not yet well understood.

Interestingly, all but two patients of this series bear *CACNA1F* mutations already described in literature as pathogenic (see Table 2)^{5,13,14}, but in the related papers no mention is made of any details of potential optic pathways involvement. The identified variants do not affect a specific exon or protein domain. Use of WES allowed us to exclude for cases 1, 2, 3, 4 and 5 the presence of pathogenic variants in genes associated with known optic nerve diseases.

One could argue that high myopia could be a confounding factor in the interpretation of pRNFL thinning in this series of patients since it is well known that pRNFL thickness is related to high myopia in normal population^{21,22}. Nevertheless, while six (6/11) patients are high myopes, five patients (5/11) clearly show signs of an optic neuropathy in combination with a phenotype of iCSNB, low visual acuity in the presence of either no or only a mild and stable myopic defect during long term follow-up.

We think it is important to underline the longitudinal follow-up of our pediatric patients: despite the variable progression of their myopic refractive error, the central visual function (BCVA) remained stable over the years in all pediatric cases, even with an early-

childhood presentation. In one of them, we were also able to demonstrate that pRNFL and GCC thinning remained stable.

It is entirely conceivable that the prevalence of optic neuropathy in *CACNA1F*-related phenotypes could be under-reported. Since these patients usually present with bilateral high myopia of childhood-onset, pRNFL-GCC abnormalities could be easily attributed to myopic shift during the phenotyping process at the eye genetics clinic. In fact, these findings are difficult to differentiate from a real optic neuropathy, unless clinical evidence of progressive disease is established.

According to the report by Nakamura, the progressive aspect of the disease could become evident only later in life since the authors describe their patients respectively at 56 and 64 years old¹⁵. Although the role of *CACNA1F* in optic pathway development and maintenance has yet to be explored, the severity of the visual pathway abnormalities ranges from a mild childhood presentation to a more severe presentation in later life. From our series, although we miss longitudinal data, only one elderly patient showed symmetrically decreased pRNFL at the age of 64, with slightly preserved BCVA and pRNFL values similar to the rest of the other patients.

Novel sequencing techniques have recently opened new avenues for establishing proper genotype-phenotype relationships, increasing the variability of the clinical manifestations of the diseases due to mutations in known genes. The *CACNA1F* gene confirms this trend because several reports state that the *CACNA1F* phenotypical spectrum can span from presentations similar to LCA in early life, to albinism-like forms such as Åland Island Eye Disease.

CONCLUSIONS

To the best of our knowledge, this is the first study, that reports a large case series of patients affected by *CACNA1F* mutations with clear involvement of the optic pathways. This involvement was present since childhood and remained stable over a very long period. These findings support the hypothesis that optic neuropathy could be an underreported manifestation of *CACNA1F*-related disease, indicating that optic nerve involvement should be considered as part of the phenotypical spectrum. Our findings support the idea that the nomenclature for inherited eye disease should change from being phenotype-based to being genotype-based, to take the next step towards precision medicine. Additional studies are mandatory to confirm our results.

ACKNOWLEDGEMENTS

Part of the results of this paper were presented for the first time at Ophthalmic Genetics Study Club Held virtually on November 14th, 2020.

This study was further supported by the Ghent University Special Research Fund (BOF15/GOA/011 to E.D.B. and BOF20/GOA/023 to E.D.B., F.V.D.B. and B.P.L.) and by the Ghent University Hospital Innovation Fund (NucleUZ to E.D.B.). E.D.B. (1802220N) and B.P.L. (1803821N) are Senior Clinical Investigators of the Fund for Scientific Research, Flanders.

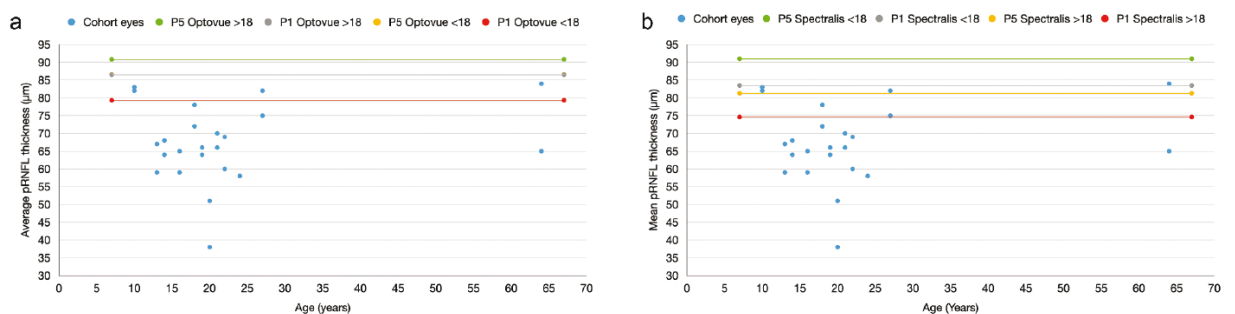
E.D.B., B.P.L., A.S, C.Z. & G.M.B. are members of ERN-EYE, which is co-funded by the Health Program of the European Union under the Framework Partnership Agreement No 739534 'ERN-EYE'.

REFERENCES

1. Petit L, Khanna H, Punzo C. Advances in Gene Therapy for Diseases of the Eye. *Hum Gene Ther.* 2016;27(8):563-579.
2. Bennett J. Taking Stock of Retinal Gene Therapy: Looking Back and Moving Forward. *Mol Ther.* 2017;25(5):1076-1094.
3. Petit L, Punzo C. Gene therapy approaches for the treatment of retinal disorders. *Discov Med.* 2016;22(121):221-229.
4. Bech-Hansen NT, Naylor MJ, Maybaum TA, et al. Loss-of-function mutations in a calcium-channel alpha1-subunit gene in Xp11.23 cause incomplete X-linked congenital stationary night blindness. *Nature genetics.* 1998;19(3):264-267.
5. Zeitz C, Robson AG, Audo I. Congenital stationary night blindness: an analysis and update of genotype-phenotype correlations and pathogenic mechanisms. *Progress in retinal and eye research.* 2015;45:58-110.
6. Weleber RG, Pillers DA, Powell BR, Hanna CE, Magenis RE, Buist NR. Aland Island eye disease (Forsius-Eriksson syndrome) associated with contiguous deletion syndrome at Xp21. Similarity to incomplete congenital stationary night blindness. *Archives of ophthalmology.* 1989;107(8):1170-1179.
7. Hauke J, Schild A, Neugebauer A, et al. A novel large in-frame deletion within the CACNA1F gene associates with a cone-rod dystrophy 3-like phenotype. *PloS one.* 2013;8(10):e76414.
8. Zhou Q, Cheng J, Yang W, et al. Identification of a novel heterozygous missense mutation in the CACNA1F gene in a chinese family with retinitis pigmentosa by next generation sequencing. *Biomed Res Int.* 2015;2015:907827.
9. Miyake Y, Yagasaki K, Horiguchi M, Kawase Y, Kanda T. Congenital stationary night blindness with negative electroretinogram. A new classification. *Archives of ophthalmology.* 1986;104(7):1013-1020.

10. Vincent A, Wright T, Day MA, Westall CA, Heon E. A novel p.Gly603Arg mutation in CACNA1F causes Aland island eye disease and incomplete congenital stationary night blindness phenotypes in a family. *Molecular vision*. 2011;17:3262-3270.
11. Provenzano A, La Barbera A, Scagnet M, et al. Chiari 1 malformation and exome sequencing in 51 trios: the emerging role of rare missense variants in chromatin-remodeling genes. *Human genetics*. 2020.
12. McCulloch DL, Marmor MF, Brigell MG, et al. ISCEV Standard for full-field clinical electroretinography (2015 update). *Documenta ophthalmologica Advances in ophthalmology*. 2015;130(1):1-12.
13. Zeitz C, Michiels C, Neuille M, et al. Where are the missing gene defects in inherited retinal disorders? Intronic and synonymous variants contribute at least to 4% of CACNA1F-mediated inherited retinal disorders. *Human mutation*. 2019;40(6):765-787.
14. Zeitz C, Minotti R, Feil S, et al. Novel mutations in CACNA1F and NYX in Dutch families with X-linked congenital stationary night blindness. *Molecular vision*. 2005;11:179-183.
15. Wutz K, Sauer C, Zrenner E, et al. Thirty distinct CACNA1F mutations in 33 families with incomplete type of XLCSNB and *Cacna1f* expression profiling in mouse retina. *Eur J Hum Genet*. 2002;10(8):449-456.
16. Nakamura M, Ito S, Piao CH, Terasaki H, Miyake Y. Retinal and optic disc atrophy associated with a CACNA1F mutation in a Japanese family. *Archives of ophthalmology*. 2003;121(7):1028-1033.

17. Pasutto F, Ekici A, Reis A, Kremers J, Huchzermeyer C. Novel truncating mutation in CACNA1F in a young male patient diagnosed with optic atrophy. *Ophthalmic genetics*. 2018;39(6):741-748.
18. Naylor MJ, Rancourt DE, Bech-Hansen NT. Isolation and characterization of a calcium channel gene, Cacna1f, the murine orthologue of the gene for incomplete X-linked congenital stationary night blindness. *Genomics*. 2000;66(3):324-327.
19. Chang B, Heckenlively JR, Bayley PR, et al. The nob2 mouse, a null mutation in Cacna1f: anatomical and functional abnormalities in the outer retina and their consequences on ganglion cell visual responses. *Vis Neurosci*. 2006;23(1):11-24.
20. Ung T, Allen LE, Moore AT, et al. Is optic nerve fibre mis-routing a feature of congenital stationary night blindness? *Documenta ophthalmologica Advances in ophthalmology*. 2005;111(3):169-178.
21. Biswas S, Lin C, Leung CK. Evaluation of a Myopic Normative Database for Analysis of Retinal Nerve Fiber Layer Thickness. *JAMA ophthalmology*. 2016;134(9):1032-1039.
22. Lee MW, Kim JM, Shin YI, Jo YJ, Kim JY. Longitudinal Changes in Peripapillary Retinal Nerve Fiber Layer Thickness in High Myopia: A Prospective, Observational Study. *Ophthalmology*. 2019;126(4):522-528.



Graph 1.

Scatter plot showing the cohort's mean pRNFL thickness for each eye in reference to the first and fifth percentiles for the different pediatric normative reference databases (28–31). For clarity, two separate graphs are shown: graph A indicating the percentiles for the iVue system and graph B for the Spectralis system.

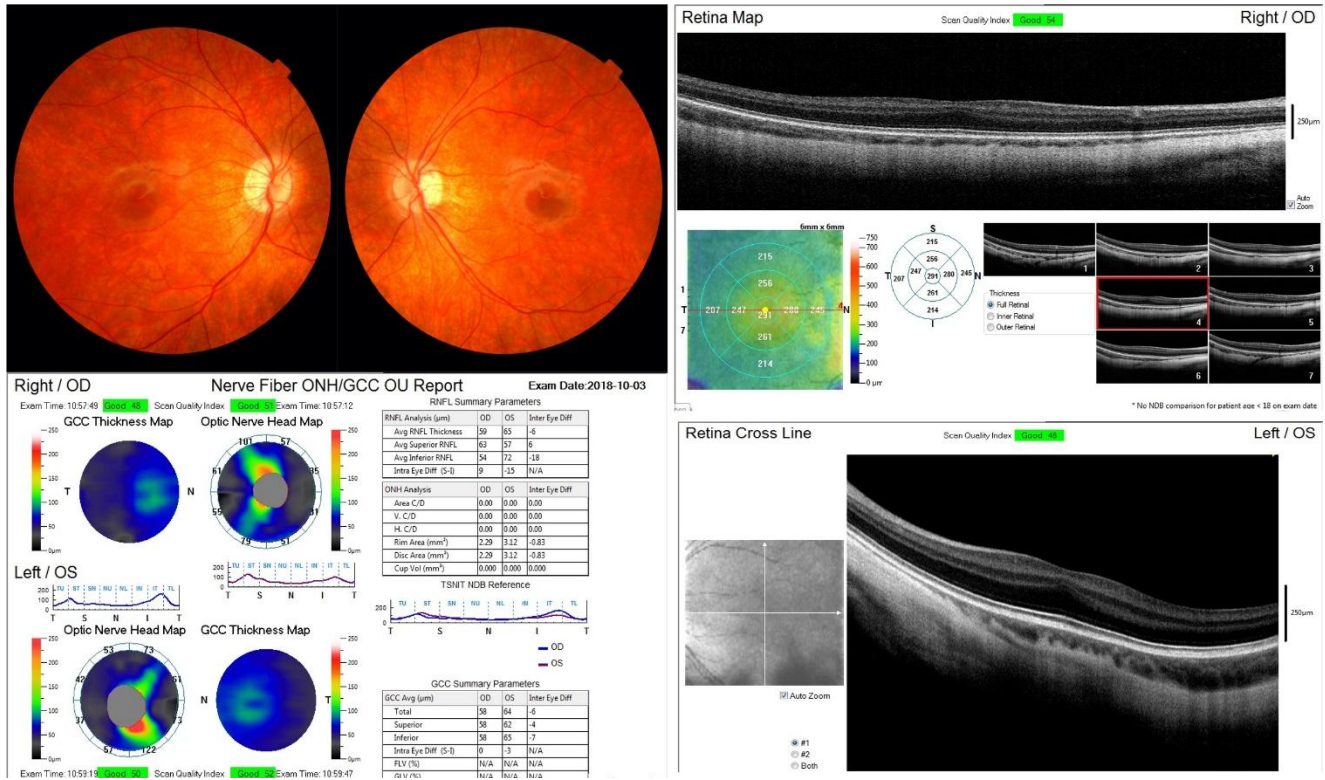


Figure 1.

Composite imaging of patient 1. Upper left: fundus image showing mild myopic change of peripapillary area. Bottom left: optic nerve head SD-OCT and GCC analysis showing bilateral low pRNFL and GCC thickness. Upper right and bottom right: SD-OCT macula scan evidence bilateral foveal hypoplasia.

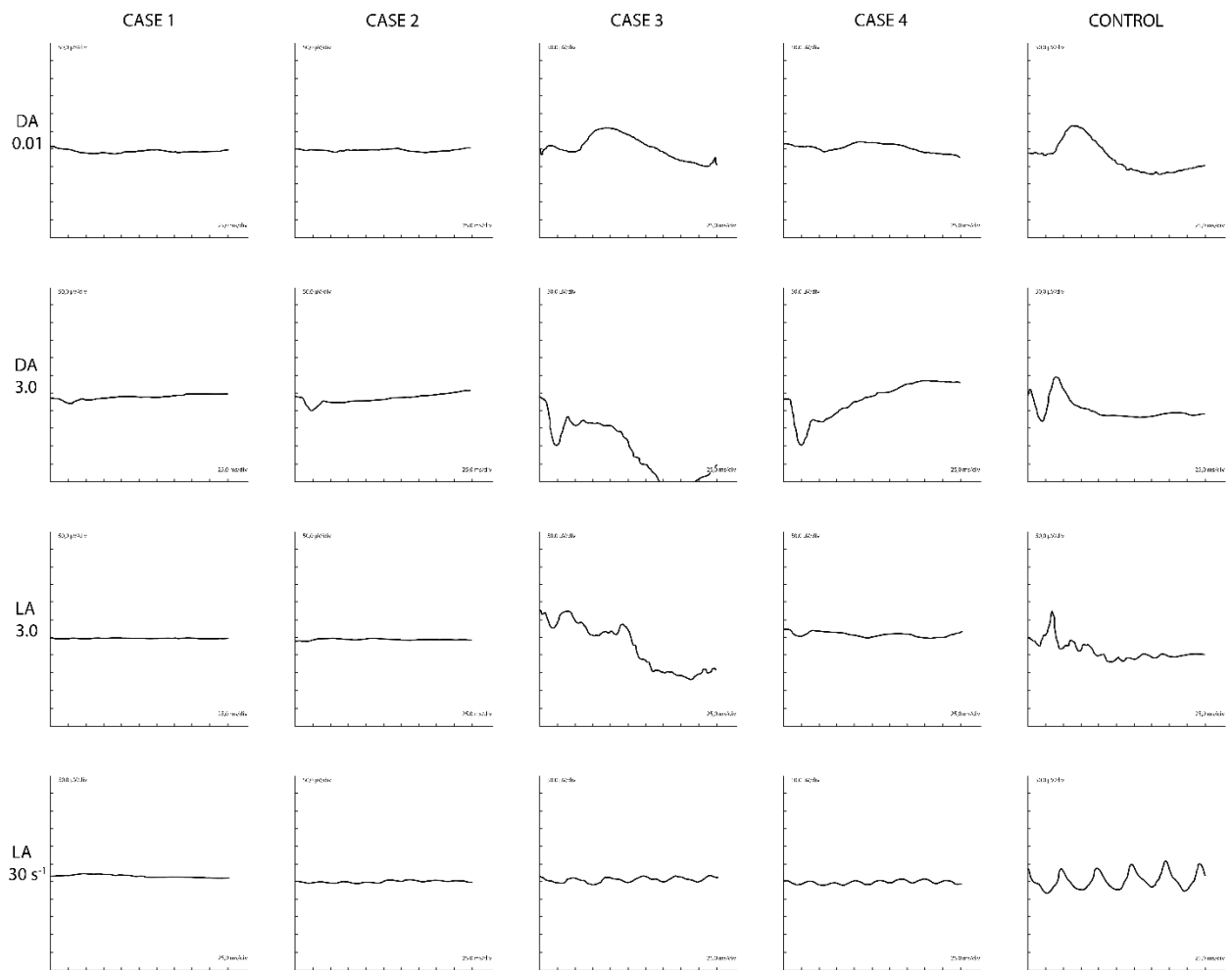


Figure 2.

Full-field ERG of Patients 1–4. Note the overall amplitude differences between the exams obtained under anesthesia (Case 1 & 2) and in conscious children (Case 3 & 4) as well as the extreme variability of the scotopic and photopic responses in *CACNA1F* associated ocular disease. All patients show the “electronegative” waveform for the dark-adapted 3.0. 50 microVolt per division and 25 ms per division.

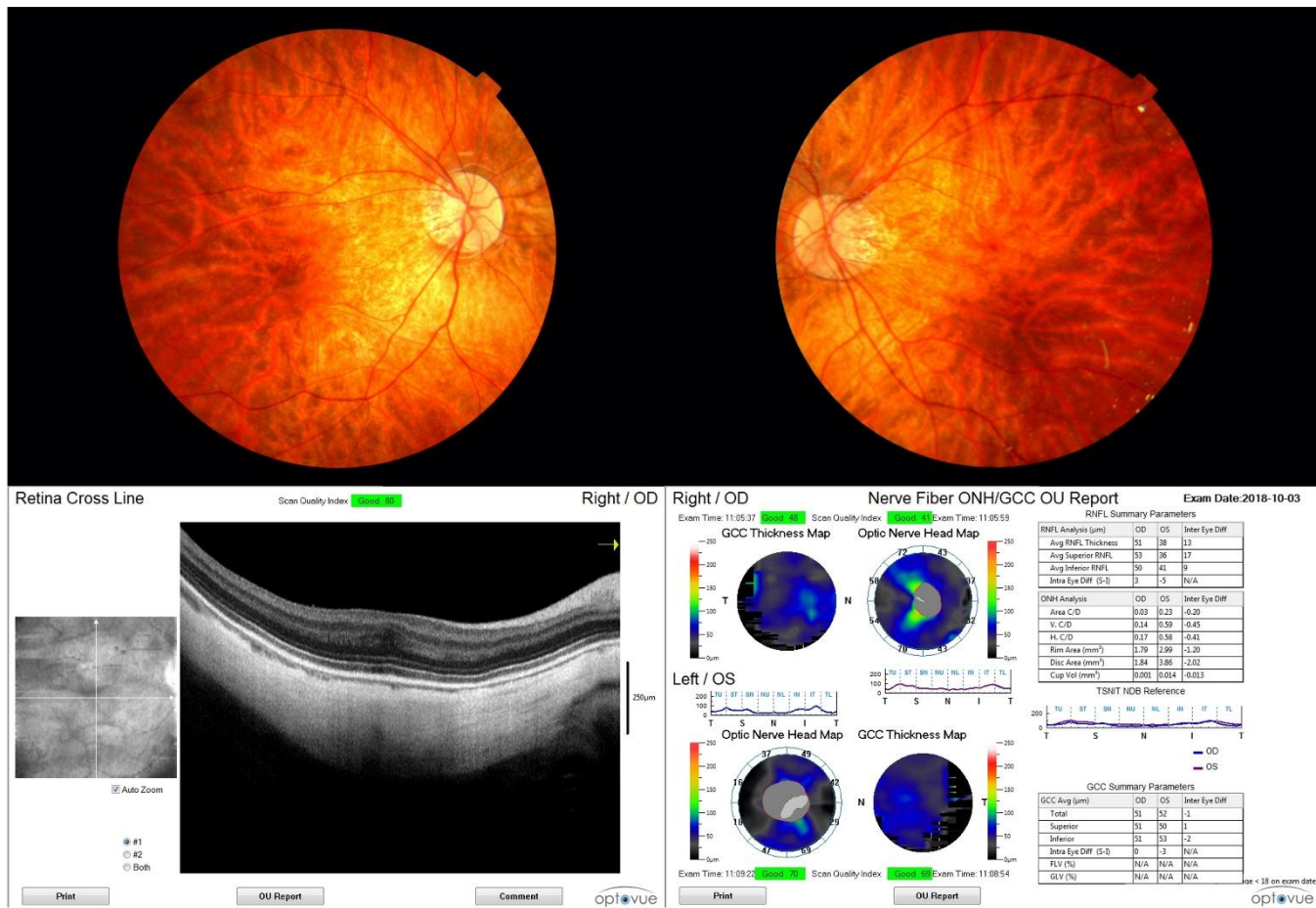


Figure 3.

Composite imaging of patient 2. Upper part: fundus image showing myopic change in the peripapillary and posterior pole area. Bottom left: SD-OCT scan showing a degree of foveal hypoplasia in the right eye. Bottom right: SD-OCT scan of optic nerve head and GCC showing low values in both eyes.

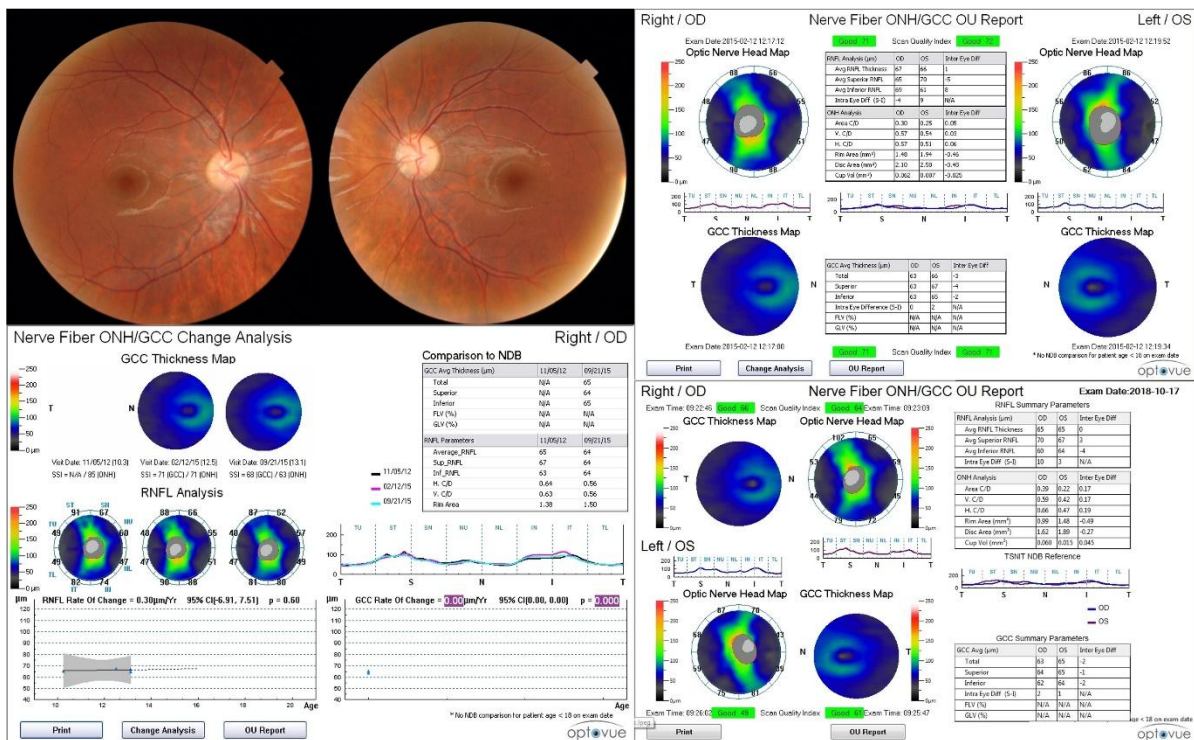


Figure 4.

Composite imaging of patient 3. Upper left: fundus image showing a mild, diffuse pallor of optic disc and overall normal ophthalmoscopic fundus. Bottom left: Optic nerve head SD-OCT showing RE pRNFL stable from 2012 until 2015 Upper and Bottom right: Optic nerve head SD-OCT showing pRNFL thickness stable values in both eyes from 2015 until 2018.

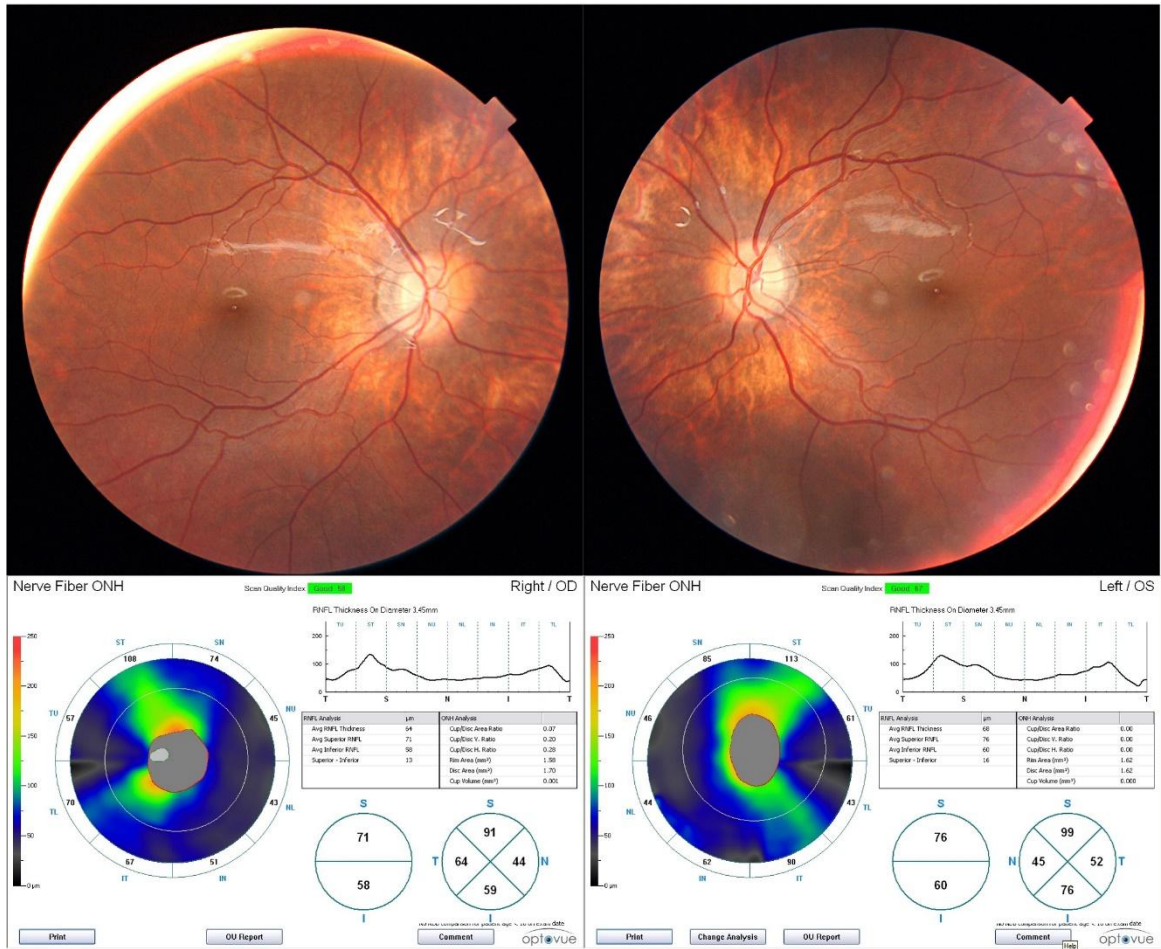


Figure 5.

Composite imaging of patient 4. Upper part: fundus image showing only mild myopic change in optic disc area and ophthalmoscopically normal posterior pole. Bottom part: Optic nerve head SD-OCT showing low bilateral pRNFL thickness.

Table 1. Clinical data.

ID	Age (years)	F/UP (years)	BCVA (Snellen eqv. ft/ft)		Refraction(SE in D)		Avg. pRNFLT (μ m)		Avg. pRNFLT (relative)	GCC	MRI	ERG	Fundus Photo	Color vision D-15	CACNA1F phenotype
			RE	LE	RE	LE	RE	LE							
1	16	15	20/80	20/63	-15,00	-15,00	59	65	Low	Very Low	Normal	Electronegative	Myopic	Normal	AIED
2	20	17	20/80	20/100	-15,00	-17,00	51	38	Low	Very Low	Normal	Electronegative	Myopic	Normal	AIED
3	19	12	20/63	20/50	-3,00	-3,00	66	64	Low	Low	Normal	Electronegative	Optic disc pallor	Normal	CSNB
4	14	7	20/63	20/50	-10,00	-11,00	64	68	Low	Low	Normal	Electronegative	Normal	Normal	CSNB
5	13	7	20/50	20/40	-1,00	-2,00	67	59	Low	Low	Normal	Electronegative	Normal	Normal	CSNB
6	22	6	20/25	20/25	-1,00	1,50	69	60	Low	Low	Normal	Electronegative	Normal	Normal	CSNB
7	27	8	20/30	20/40	-5,00	-7,00	75	82	Low	Low	Normal	Electronegative	Myopic	Normal	CSNB
8	64	23	20/40	20/40	0,50	0,75†	65	84	Low	Low	Normal	Electronegative	Myopic, tilted disc, peripapillary atrophy, peripheral reticular pattern	Normal	CSNB
9	21	12	20/100	20/50	-3,00	-3,00	66	70	Low	Low	Normal	Electronegative	Normal	Normal	CSNB
10	10	10	20/32	20/32	-4,75	-4,75	82	83	Low	Low	N.A.	Electronegative*	Mildly myopic	N.A.	CSNB
11	18	16	20/32	20/50	-6,50	-6,50	72	78	Low	Low	Normal	Electronegative	Mildly myopic; fairly large optic disc with C/D 0.5,	Normal	CSNB
12	24	12	20/32	20/40	-5,75	-6,25	58	58	Low	Very Low	N.A.	Electronegative	Myopic, tilted disc, peripapillary atrophy	Normal	CSNB

Abbreviations used: RE = right eye; LE = left eye; F/UP = duration of follow up; BCVA = best corrected visual acuity; Snellen eqv. ft/ft= Snellen equivalent in feet; SE = spherical equivalent; D = Diopter; Avg. pRNFLT = average peripapillary retinal nerve fiber layer thickness; MRI = magnetic resonance imaging (of the brain); ERG = electroretinography; GCC = ganglion cell complex (inner plexiform layer, retinal ganglion cell layer and retinal nerve fiber layer); Color vision D-15 = Farnsworth D-15 color vision test, C/D = optic nerve head cup-to-disc ratio; N.A. = not available *.ERG obtained in maternal uncle of patient with typical electronegative ERG phenotype, on-off responses of extended protocol show involvement of both pathways; segregation analysis of mutation confirmed presence in multiple family members including this proband. †.High myopia previously corrected with LASIK.

Table 2. CACNA1F (NM_005183.2) variants in this cohort.

ID	DNA Level	Protein Level	Exon/Intron	Pathogenicity	Reference
1	c.3470A>G	p.(Gln1157Arg)	28	likely pathogenic	Zeit et al. (17)
2	c.3470A>G	p.(Gln1157Arg)	28	likely pathogenic	Zeit et al. (17)
3	c.2071C>T	p.(Arg691*)	15	pathogenic	Zeit et al. (18)
4	c.3975 + 2T>C	p.?	intron 33	pathogenic	Wutz et al. (19)
5	c.2739del	p.(Ile914Phefs *8)	22	pathogenic	New
6	c.3511dup	p.(Arg1171Profs *23)	29	pathogenic	New
7	c.5514 G>A	p.(Trp1838*)	47	pathogenic	ClinVar
8	c.1195del	p.(Glu339Lysfs *34)	9	likely pathogenic	New
9	c.1537C>T	p.(Arg513*)	13	pathogenic	Zeit et al. (7)
10	c.263T>A	p.(Ile88Asn)	2	likely pathogenic	Zeit et al. (7)*
11	c.2118 + 1 G>A	p.?	intron 15	pathogenic	Zeit et al. (17)*
12	c.3052 G>A	p.(Gly1018Arg)	25	pathogenic	Wutz et al. (19)*

All variants are reported in reference to NM_005183.2. *.Patient 10 and 12, and 11 were included in Zeit et al. (7, 17) respectively, to report the mutations found in them. Within this article the focus is on novel clinical findings.