


Anatomical connectivity of the visuospatial attentional network in schizophrenia: a DTI-based tractography study

E. Leroux¹; N. Poirel^{2,3}; S. Dollfus^{1,4,5}

¹Université Caen Normandie, UNICAEN, ISTS EA 7466, 14000 Caen, France; ²Université Paris Descartes, Université Caen Normandie, UNICAEN, LaPsyDÉ, UMR 8240, CNRS, 75000 Paris, France; ³Institut Universitaire de France (IUF), 75000 Paris, France; ⁴CHU de Caen, Service de Psychiatrie Adulte, 14000 Caen, France; ⁵Normandie Univ, UNICAEN, UFR de médecine (Medical School), 14000 Caen, France

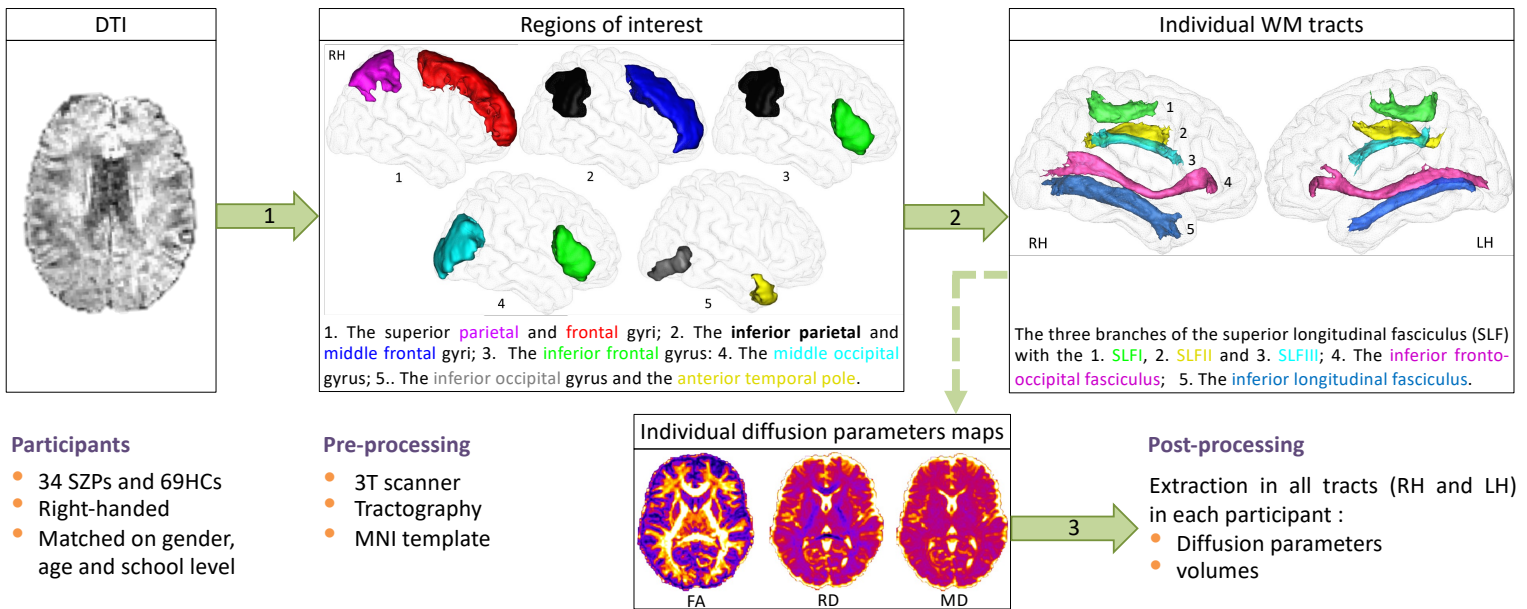
eleroux@cyceron.fr



Background

- In healthy controls (HCs), the visuospatial attentional network consists of fronto-parietal bundles distributed across both hemispheres [1]. The anatomical organization of this network remains unexplored in patients with schizophrenia (SZPs).
- The aim of the present study was to determinate the white matter integrity (WM) and the volume of visuospatial attentional pathways in the right and left hemispheres (RH and LH), as well as their structural asymmetry in SZPs and HCs, using diffusion tensor imaging (DTI)-based tractography. We hypothesized that SZPs would have WM pathway alterations and reduced rightward structural asymmetry.

Methods



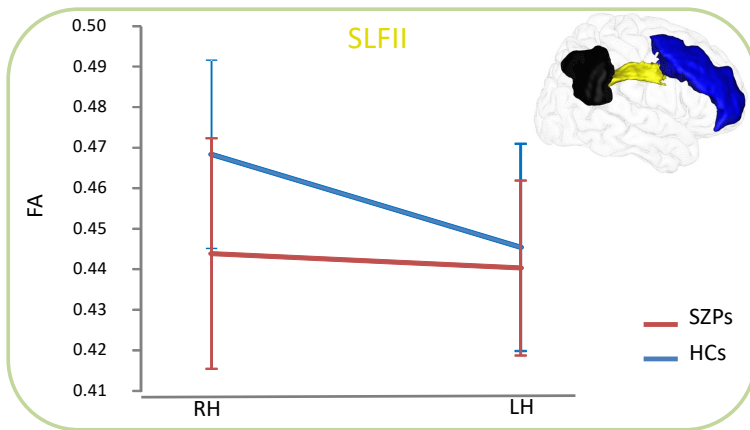
Participants

- 34 SZPs and 69HCs
- Right-handed
- Matched on gender, age and school level

Pre-processing

- 3T scanner
- Tractography
- MNI template

Results



- Repeated measure ANCOVAs with diffusion parameter as the dependent variable and group and hemisphere as independent factors were conducted. Gender was included as covariates, and the group × hemisphere interaction was tested. Post-hoc analyses used Tukey's HSD test.
- SLFII** : HCs displayed a rightward asymmetry ($P < 0.0001$ for all values), for which they presented better integrity than SZPs (FA: $P < 0.0001$; RD: $P = 0.0005$; MD: $P = 0.0059$) (Figure).
- SLFIII** : HCs and SZPs displayed a rightward asymmetry for FA ($P < 0.0001$ and $P = 0.0042$), but HCs presented better integrity than SZPs in the both RH and LH ($P < 0.0001$ respectively).
- There was no significant result for volume neither for diffusion values in the others tracts.

Discussion

- The results revealed a **specific disruption of structural connectivity in the SLFII** and a **reduced rightward anatomical asymmetry** of the fasciculus between the RH and LH in patients compared to HCs [2, 3], which could be the **substrate of attentional deficits and alterations in visuospatial abilities that SZPs experience**.
- The presents results provide new insights regarding the neuroanatomical basis of atypical visuospatial attentional network in schizophrenia and new understanding of how patients consider and process their visual world.

References

[1] Luven et Bartolomeo, 2016. Attention and spatial cognition: Neural and anatomical substrates of visual neglect. Ann Phys Rehabil Med. [2] Thiebaut De Schotten et al., 2011. A lateralized brain network for visuospatial attention. Nat Neurosci. [3] Chechlacz et al., 2015. Structural Variability within Fronto-parietal Networks and Individual Differences in Attentional Functions: An Approach Using the Theory of Visual Attention. J Neurosci.