



HAL
open science

Biological and Therapeutic Implications of the Tumor Microenvironment in Pituitary Adenomas

Mirela-Diana Ilie, Alexandre Vasiljevic, Philippe Bertolino, Gérald Raverot

► **To cite this version:**

Mirela-Diana Ilie, Alexandre Vasiljevic, Philippe Bertolino, Gérald Raverot. Biological and Therapeutic Implications of the Tumor Microenvironment in Pituitary Adenomas. *Endocrine reviews*, 2023, 44 (2), pp.297-311. 10.1210/endrev/bnac024 . hal-04113463

HAL Id: hal-04113463

<https://cnrs.hal.science/hal-04113463>

Submitted on 1 Dec 2023

HAL is a multi-disciplinary open access archive for the deposit and dissemination of scientific research documents, whether they are published or not. The documents may come from teaching and research institutions in France or abroad, or from public or private research centers.

L'archive ouverte pluridisciplinaire **HAL**, est destinée au dépôt et à la diffusion de documents scientifiques de niveau recherche, publiés ou non, émanant des établissements d'enseignement et de recherche français ou étrangers, des laboratoires publics ou privés.

26 Dr Philippe BERTOLINO
27 Cancer Research Centre of Lyon (CRCL)
28 Centre Léon Bérard, Cheney D, 1er étage
29 28 Rue Laennec, 69373 LYON CEDEX 08, France
30 philippe.bertolino@inserm.fr

31

32 **Name and address of author to whom reprint requests should be addressed:**

33 Gérald Raverot
34 Fédération d'Endocrinologie, Centre de Référence des Maladies Rares Hypophysaires
35 Groupement Hospitalier Est, Hospices Civils de Lyon
36 8 av. Doyen Lepine, 69677 Bron Cedex, France

37

38 **Funding:** This work has been supported by the *Fondation ARC pour la recherche sur le cancer* (PJA
39 20181207935 and ARCMD-DOC12020020001361), the *Ligue contre le cancer (CCAURA)*, the *Région*
40 *Rhone-Alpes-Auvergne (HypoMeT)*, and the *Société Française d'Endocrinologie (FRIEMM)*.

41

42 **Disclosure summary:** The authors have no conflict of interest to disclose.

43

44 **Abstract**

45 Pituitary adenomas are neoplasms derived from the endocrine cells of the anterior pituitary gland. Most
46 frequently, they are benign tumors, but may sometimes display an aggressive course, and in some cases
47 metastasize. Their biology, including their wide range of behavior, is only partly understood. In terms of
48 therapeutic targeting, most pituitary adenomas are easily treated with the available medical treatments,
49 surgery, and sometimes radiotherapy. Nevertheless, gonadotroph adenomas lack medical therapeutic
50 options, and treatment of aggressive pituitary adenomas and pituitary carcinomas remains challenging.
51 Here, we present an overview of the implications of tumor microenvironment in pituitary adenomas,

52 reviewing its composition and function, as well as published cases that have been treated thus far using
53 tumor microenvironment-targeting therapies. Additionally, we discuss emerging views, such as the concept
54 of non-angiogenic tumors, and present perspectives regarding treatments that may represent future potential
55 therapeutic options. Tumor-infiltrating lymphocytes, tumor-associated macrophages, folliculostellate cells,
56 tumor-associated fibroblasts, angiogenesis, as well as the extracellular matrix and its remodelling, all have
57 complex roles in the biology of pituitary adenomas. They have been linked to hormone
58 production/secretion, size, invasion, proliferation, progression/recurrence, and treatment response in
59 pituitary adenomas. From a therapeutic perspective, immune-checkpoint inhibitors and bevacizumab have
60 already shown a degree of efficacy in aggressive pituitary adenomas and pituitary carcinomas, and the use
61 of numerous other tumor microenvironment-targeting therapies can be foreseen. In conclusion, similar to
62 other cancers, understanding the tumor microenvironment improves our understanding of pituitary
63 adenoma biology beyond genetics and epigenetics, and constitutes an important tool for developing future
64 therapies.

65

66 **Introduction**

67 The environment within which a tumor exists, the tumor microenvironment (TME), is composed of vascular
68 structures, non-tumor cells such as immune cells, and non-cellular components such as extracellular matrix
69 (ECM) macromolecules. It has long been accepted that the TME impacts tumor biology and has clinical
70 implications, both as a prognostic tool and a therapeutic target in numerous cancers (1,2). In pituitary
71 adenomas (PAs), the importance of the TME has emerged more recently, but there is now a constantly
72 growing literature on the subject, and growing evidence of the complex and intricate roles that the TME
73 plays in the biology of PAs (3,4).

74 Here, we review the biological and therapeutic implications of the TME in PAs. Briefly, we provide an
75 overview of the TME composition and function, and we review all of the published cases of aggressive
76 PAs and pituitary carcinomas (PCs) that have been treated with therapies that target the TME. Additionally,
77 we present perspectives regarding treatments that have not so far been used in PAs, but that may represent

78 potential therapeutic options in the future. Given that both the mechanisms of tumorigenesis and the
79 composition of the TME, along with its biological and clinical implications, might differ depending on the
80 histological subtype of the adenoma, where possible the available data is summarized separately for each
81 major adenoma subtype. **Figure 1** depicts T cells, macrophages, blood vessels, and folliculostellate cells in
82 four different histological subtypes of PAs.

83

84 **1. Immune microenvironment**

85 A. Biology

86 a) T cells

87 Tumor-infiltrating lymphocytes (TILs) have complex roles within the TME, that can translate into either
88 anti-tumorigenic or pro-tumorigenic effects (2). TILs that are considered to have an anti-tumorigenic effect
89 include CD56+ natural killer cells, CD8+ cytotoxic T cells, CD8+ memory T cells (CD8+CD45RO+), and
90 CD4+ T helper 1 T cells, while TILs generally considered to have a pro-tumorigenic effect include CD4+
91 T helper 2 T cells and CD4+CD25+FoxP3+ regulatory T cells (1,2,5). However, these anti-tumorigenic and
92 pro-tumorigenic effects are context-dependent, varying across tumor types and tumor stages, and are
93 dependent on the specific composition of the immune infiltrate of a tumor and composition of its TME in
94 general, as well as the location of the TIL, i.e. at the tumor invasive margin versus the tumor center (5).
95 Indeed, although CD8+ T cells have been associated with a positive prognosis in most cancer types, they
96 have been associated with a negative prognosis in renal cell carcinoma. Conversely, regulatory T cells were
97 associated with a good prognosis in colorectal or gastric cancer (5). Therefore, TILs along with the other
98 TME components need to be characterized in detail in PAs, in order to understand their respective roles.
99 To date, the majority of studies in PAs (6–16) have relied on only single/few immune markers, and the
100 quantification of the immune infiltrate varied across these studies. Nonetheless, these studies already
101 provide important information on the immune composition of the TME and its potential roles.

102 PAs have been shown to be infiltrated by CD3+, CD8+, CD4+, FoxP3+, CD45RO+, and CD56+ cells
103 (8,12–14,16,17). Compared to the normal pituitary gland (NPG), PAs had more CD4+ T cells and a lower

104 CD8+/CD4+ cell ratio (15). Functioning adenomas showed increased CD3+, CD8+, CD4+, and FoxP3+
105 IHC infiltrates in comparison to non-functioning (NF) PAs (13,18). Regarding the quantity of various T
106 cell types relative to the different histological subtypes of adenomas, studies have thus far yielded
107 contradictory results (7,10,18). In terms of the genetic background, amongst GH-secreting adenomas, those
108 AIP-mutated had more FoxP3+ cells compared to sporadic adenomas (12). The potential impact of T cells
109 on aggressiveness-related characteristics (9,15,19) is summarized in **Table 1** (4,9–15,18–51).

110

111 b) Tumor-associated macrophages (TAMs)

112 Affected by cues coming from both tumor cells and TME cells, TAMs can acquire distinct phenotypes and
113 have either anti-tumorigenic or pro-tumorigenic effects (52). TAMs with an M2 phenotype are considered
114 to be pro-tumorigenic and have been consistently associated with a negative prognosis across various
115 cancers, while TAMs with an M1 phenotype are considered anti-tumorigenic and have been associated with
116 a positive prognosis (5). However, in some tumor types, the effect of TAMs on prognosis depends on their
117 location, in the tumor stroma versus the tumor core (5).

118 PAs have been reported to contain more macrophages (CD68+), more M2-like macrophages (CD163+),
119 and a CD163/HLA-DR ratio three-times higher when compared to NPG (the HLA-DR marker being
120 indicative of M1-like TAMs) (15). This is similar to what is seen in other cancers, where M2-like TAMs
121 also predominate (5). TAMs were also reported to be the most abundant immune cell in PAs (15,21,53),
122 most notably M2-like TAMs (15,53). The percentage of CD68+ TAMs showed a positive correlation with
123 adenoma size in somatotroph, lactotroph, NFPAs (21), and gonadotroph adenomas (14). In terms of TAM
124 infiltration relative to the different histological subtypes of adenomas, studies have thus far yielded
125 contradictory results (10,14,15,18,21,53). Concerning the genetic background, amongst GH-secreting
126 adenomas, those AIP-mutated had more CD68+ cells compared to sporadic adenomas (12).

127 The potential impact of TAMs on aggressiveness-related characteristics (9–15,18,21,37) is summarized in
128 **Table 1**. Taking into account both TILs and TAMs, it appears that aggressiveness is associated with an
129 immunosuppressive TME. From a mechanistic point of view, bidirectional interactions between tumor cells

130 and TAMs take place, with tumor cells recruiting and polarizing TAMs preferentially towards an M2-like
131 phenotype, while M2-like TAMs promote PA aggressiveness, and most notably PA invasiveness
132 (12,14,15,21,37). These findings are consistent with the reports of M2-like TAMs being implicated in tumor
133 growth and development of an invasive phenotype in other types of cancer (5). Moreover, bidirectional
134 interactions take place between TAMs and other components of the TME, especially between M2-like
135 TAMs and angiogenesis. For example, in several other cancers it has been shown that hypoxia leads to
136 macrophage recruitment, which in turn facilitates angiogenesis (54). **Figure 2** summarizes the roles and
137 interactions of TAMs in PAs (12,14,15,18,19,21,37,55).

138

139 c) Other immune cells

140 There is limited published data concerning other immune cells in PAs. PAs have been reported to contain
141 fewer neutrophils than NPG (15). Some studies have reported B cells to be only seen in exceptional cases
142 (6,8,10), while other studies did identify B cells in PAs, but they were fewer compared to TAMs and T cells
143 (14,15,53). Somatotroph adenomas have been reported to have more B cells compared to NFPA (56),
144 while NFPA contained more neutrophils than somatotroph adenomas (15).

145

146 B. Therapy

147 a) Immune-checkpoint inhibitors

148 The immune-checkpoint inhibitors that have been used to date in aggressive PAs and PCs include:
149 ipilimumab combined with nivolumab, used in six cases, and pembrolizumab, which was used in five cases
150 (57–64). The mechanisms of action of these drugs are illustrated in **Figure 3A**. Their use in aggressive PAs
151 and PCs has been extensively reviewed recently (65).

152 Six corticotroph carcinomas and one aggressive corticotroph adenoma have been treated with immune-
153 checkpoint inhibitors. In terms of the radiological response, four of the carcinomas showed a partial
154 response that was maintained for 6 to 42 months (duration not available in one case), two of the carcinomas
155 showed stable disease that was maintained for at least 12 months in one of the cases (data not available in

156 the second), while the aggressive adenoma showed progressive disease (57–61,64,65) (**Figure 4**). In two
157 of the cases that initially showed a partial response, a dissociated radiological response was later noted, and
158 in both cases, continuation of immune-checkpoint inhibitors in combination with local treatment
159 (radiotherapy, surgery, and radiofrequency ablation, respectively) proved to be a good therapeutic option
160 (65).

161 Three lactotroph carcinomas and one aggressive lactotroph adenoma have been treated with immune-
162 checkpoint inhibitors. Regarding the radiological response, one carcinoma showed a complete response
163 maintained for at least 13 months, one showed a partial response maintained for 8 months, the third showed
164 progressive disease, while the aggressive adenoma also showed progressive disease (59,62–64) (**Figure 4**).
165 Of note, the carcinoma that progressed was initially treated with pembrolizumab, and was subsequently
166 treated with programmed cell death protein 1 (PD-1)/programmed death-ligand 1 (PD-L1) pathway
167 inhibitors, and showed continued progression (64).

168 Regarding potential predictive factors of response, data is too scarce to allow firm conclusions. Currently,
169 the most promising predictive factor appears to be a high tumor mutational burden. Negative PD-L1
170 immunohistochemical staining should not preclude the administration of immune-checkpoint inhibitors,
171 since even negative cases responded well. Conversely, the presence of a mismatch repair deficiency did not
172 guarantee a good response (65). Moreover, for corticotroph tumors, it appears important to achieve
173 eucortisolism, since glucocorticoids have an immunosuppressive effect that could lessen the efficacy of
174 treatment (65). Currently, too little data is available to reach a conclusion on the eventual superiority of
175 combined immunotherapy over monotherapy (65).

176 Concerning the tolerance of immune-checkpoint inhibitors, patients cumulatively experienced fatigue,
177 diarrhea, nausea, vomiting, anorexia, fever, transaminitis, autoimmune hepatitis, autoimmune nephritis,
178 rash, myalgia, and possible hypophysitis and progressive weight loss (57–64). As expected, monotherapy
179 was better tolerated than combined treatment. Nevertheless, these adverse events were mostly mild, and led
180 to interruption of dual immunotherapy in only two cases: in one in which progressive disease was
181 simultaneously noted (59), and in a second case, where treatment was continued with nivolumab alone (62).

182

183 b) Perspectives

184 Potential leads for increasing the efficacy of immune-checkpoint inhibitors include a better patient
185 selection, as well as combining immune-checkpoint inhibitors with angiogenesis-targeting drugs (9,66,67),
186 with radiotherapy (68,69), or with peptide receptor radionuclide therapy (58).

187 At the same time, given both the presence and the important role TAMs appear to play in PAs, targeting
188 TAMs may prove to be a good option for PAs and PCs. This might be even more true for gonadotroph
189 tumors, which are, at least in theory, less amenable to immune-checkpoint inhibitors than other types of PA
190 (70,71). There are numerous TAM-targeting agents and TAM-targeting strategies, including preventing
191 TAM recruitment by using, for example, colony stimulating factor 1 (CSF1)–CSF1 receptor inhibitors, C-
192 C chemokine receptor (CCR)5–C-C motif chemokine ligand (CCL)5 inhibitors etc.; depleting TAMs by
193 using CSF1–CSF1 receptor inhibitors, triggering receptor expressed on myeloid cells (TREM) inhibitors
194 etc.; reprogramming TAMs by using CD40 agonists, TREM inhibitors etc.; exploiting the antitumor
195 functions of TAMs by using tyrosine protein phosphatase non-receptor type substrate 1 (SIRP α)–CD47
196 inhibitors or sialic acid-binding immunoglobulin-like lectin (SIGLEC)10–CD24 inhibitors; and infusing
197 macrophages that are engineered to eliminate tumor cells and/or reprogram the TME (72).

198

199 **2. Folliculostellate cells**

200 Apart from immune cells, the TME of PAs includes a number of additional cells, including folliculostellate
201 cells and tumor-associated fibroblasts. Folliculostellate cells are non-endocrine cells that are found in the
202 NPG, where they account for ~5% of the cells of the anterior lobe (73,74). These cells are recognized by
203 their morphology and by immunopositivity for S100B protein (75,76). Through both paracrine (76,77) and
204 physical actions (78,79), folliculostellate cells exert numerous roles in the NPG, including a supportive
205 role, phagocytic properties, regulation of hormone secretion, and the production of growth factors and
206 cytokines (vascular endothelial growth factor (VEGF), interleukin 6, basic fibroblast growth factor,
207 follistatin, transforming growth factor β etc.) (74,77,80,81). A role as a stem/progenitor cell has also been

208 often discussed, however it is still debated whether the S100B/SOX2 positive cells, considered to be the
209 stem/progenitor cells, are a subset of folliculostellate cells or an entirely different population that happens
210 to also be positive for S100B protein (74,82).

211 PAs have been consistently shown to contain fewer folliculostellate cells than the NPG (35,73,83).
212 However, heterogeneity between tumors exists, and although the vast majority of tumors had very low
213 percentages of S100B+ cells, other tumors were rich in S100B+ cells (35). Concerning their potential roles
214 in PAs, consistent with their role in the NPG, folliculostellate cells appear to potentially modulate hormone
215 production/secretion: in acromegaly patients, relationships were shown between S100B+ cells and both
216 growth hormone and prolactin levels (84), while in gonadotroph tumors a positive correlation between
217 S100B staining and FSH staining was identified (35). A role of folliculostellate cells in maintaining a more
218 functional, differentiated state, thus closer to the normal state of gonadotroph tumor cells has also been
219 proposed (35). Another proposed role for folliculostellate cells in PAs, consistent with a similar role
220 proposed for a subset of folliculostellate cells in the NPG (74,85), is an antigen presentation function, this
221 proposition being based on the spatial proximity of immune cells and folliculostellate cells co-expressing
222 the S100 protein and MHC class II antigens that was observed in three PAs (86). The potential impact of
223 folliculostellate cells on aggressiveness-related characteristics (35) is summarized in **Table 1**. Therefore, it
224 appears that folliculostellate cells might play important roles in tumorigenesis-related processes in PAs, but
225 these roles need to be further studied. Hopefully, ways in which these cells could be therapeutically
226 targeted/modulated will be developed in the future.

227

228 **3. Tumor-associated fibroblasts**

229 Tumor-associated fibroblasts are phenotypically and functionally heterogeneous cells, that are seen as a
230 key TME component across various cancers (87,88). Tumor-associated fibroblasts have been mostly
231 associated with tumor progression, but they can also exhibit cancer-restraining functions (88,89). Through
232 the secretion of cytokines, chemokines and growth factors, as well as extracellular matrix components and
233 remodeling enzymes, tumor-associated fibroblasts have been shown to be implicated in tumor growth, ECM

234 remodeling, angiogenesis, tumor invasion, metastasis, immune and metabolic reprogramming of the TME,
235 as well as in chemoresistance (1,87–89).

236 Tumor-associated fibroblasts have also been identified in PAs (24), and although the literature is, so far,
237 scarce, promising biological and therapeutic implications can be foreseen. Cultured tumor-associated
238 fibroblasts, derived from PAs with cavernous sinus invasion, expressed higher levels of VEGF and
239 interleukin 6 compared to those derived from PAs without cavernous sinus invasion (23,24). Moreover, co-
240 injecting GH3 cells with tumor-associated fibroblasts derived from PAs with cavernous sinus invasion
241 resulted in xenografts with higher VEGF expression (expressed mainly by tumor cells) compared to co-
242 injecting GH3 cells with tumor-associated fibroblasts derived from PAs without cavernous sinus invasion
243 (23). In addition, cultured tumor-associated fibroblasts derived from PAs secreted CCL2 – a molecule with
244 an angiogenic function, whose levels were strongly positively correlated with the microvessel area of PAs
245 (24). The potential impact of tumor-associated fibroblasts on aggressiveness-related characteristics (23,24)
246 is summarized in **Table 1**. These findings point towards a potential role of tumor-associated fibroblasts in
247 angiogenesis, tumor growth and tumor invasion, consistent with the roles observed for these cells in other
248 cancers.

249 From a therapeutic perspective, the somatostatin (SST) type1 receptor was shown to be the predominant
250 SST receptor expressed in tumor-associated fibroblasts from PAs, shown at the mRNA level, and
251 pasireotide was able to decrease the release of interleukin 6 and CCL2 from these cells (24). This suggests
252 that pasireotide may exert its role by acting on both pituitary tumor cells and tumor-associated fibroblasts.
253 In pancreatic cancers, pasireotide was also shown to inhibit protein synthesis in tumor-associated
254 fibroblasts, and in combination with gemcitabine it reduced the chemoresistance triggered by the tumor-
255 associated fibroblast-derived secretome, as well as reducing tumor growth (90). Lastly, numerous other
256 therapeutic strategies are emerging for targeting of tumor-associated fibroblasts, ranging from cell depletion
257 (via targeting of cell surface markers), to altering their activation and/or their function, to tumor-associated
258 fibroblasts normalization (91).

259

260 4. Angiogenesis

261 A. Biology

262 Angiogenesis, i.e. the outgrowth of new blood vessels from pre-existing vessels, is a complex process that
263 involves numerous signaling pathways and molecules (92,93). Of these, the VEGF/VEGF-receptor
264 (VEGFR) pathway has remained, thus far, the most studied and most targeted pathway (67,94), including
265 in PAs. These newly formed blood vessels are immature, disorganized, and with impaired functionality,
266 leading to poor tumor perfusion, hypoxia, and decreased immune cell infiltration and activity. These
267 characteristics further facilitate the acquisition of an aggressive phenotype by tumor cells, reduce the anti-
268 tumoral immune response, but also decrease the beneficial effects of both chemotherapy and radiotherapy
269 (52,93). Therefore, a strategy of vascular normalization, which aims to restore the normal perfusion and
270 oxygenation of the tumor, has emerged in order to mitigate the aforementioned negative effects of
271 angiogenesis (93). It is noteworthy that while angiogenesis plays pivotal roles in tumorigenesis-related
272 processes (52,95), a growing body of literature demonstrates that numerous human tumors in fact lack
273 angiogenesis, suggesting that their blood supply is acquired either by vascular co-option or by vasculogenic
274 mimicry (92). These either completely non-angiogenic tumors or partly angiogenic/partly non-angiogenic
275 tumors, display biological differences compared to angiogenic tumors, which has important therapeutic
276 implications (92). A better characterization of the blood supply of PAs is therefore needed.

277 The vascularization of PAs (the microvessel density and area, but also the number and percentage of
278 endothelial cells) was found to be lower compared to that of the NPG (49,96–99), and higher in PCs
279 compared to PAs (49,50), suggesting a potential role of angiogenesis during tumor progression and
280 malignant transformation of PAs. The exception to this is invasive macroprolactinomas, which have been
281 reported to have vascular densities similar to those of the NPG (28). VEGF expression, on the other hand,
282 was reported to be either lower in PAs compared to the NPG (100,101), or at similar levels (98). Regarding
283 vascular densities and the expression of angiogenesis-related molecules relative to the different histological
284 subtypes of adenomas, studies have so far yielded contradictory results (49,50,96–98,100,102,103). The

285 potential impact of angiogenesis and of angiogenesis-related molecules on aggressiveness-related
286 characteristics (9,20,22,28,30,34,36,38–41,48–51) is summarized in **Table 1**.

287

288 B. Therapy

289 a) Anti-VEGF-A and anti-VEGFRs therapies

290 The anti-angiogenic therapies used to date in aggressive PAs and PCs include: bevacizumab, an anti-VEGF-
291 A monoclonal antibody, which has been used in 21 cases; sunitinib, a tyrosine kinase inhibitor that targets
292 multiple tyrosine kinases, including VEGFRs, and which was used in two cases; and apatinib, a tyrosine
293 kinase inhibitor that is primarily a VEGFR2 inhibitor, and which was used in one case (3,64,104–107). The
294 mechanisms of action of these drugs are illustrated in **Figure 3B**.

295 The 15 patients who received monotherapy with one of these molecules had all previously received at least
296 one course of temozolomide, while for the nine patients receiving concomitant temozolomide, this included
297 both first-course and second-course temozolomide (3,64,104–107). Given the already proven response to
298 temozolomide, the response to combination treatments does not give a clear illustration of the potential
299 efficacy of bevacizumab, therefore in **Figure 4** we present only the radiological response to monotherapy.

300 Bevacizumab

301 Five corticotroph carcinomas and three aggressive corticotroph adenomas received bevacizumab alone (six
302 cases) or combined with temozolomide (two cases) (3,104,106,108). Of the six cases treated with
303 bevacizumab alone, the radiological response was reported in 4 cases, with two showing stable disease
304 (3,104,106) maintained for at least 26 months in one case (109), and for an unknown duration in the second
305 (110), one showed progressive disease (108) (**Figure 4**), while the fourth patient died shortly after an MRI
306 performed following 2 cycles of bevacizumab showed radiological stable disease (106). Regarding the
307 cases receiving concomitant temozolomide, one corticotroph carcinoma received bevacizumab,
308 temozolomide, and radiotherapy, and demonstrated radiological complete response, while one corticotroph
309 carcinoma received bevacizumab and temozolomide, and demonstrated radiological stable disease (104).

310 Following ICI failure, one lactotroph carcinoma and one aggressive lactotroph adenoma received
311 bevacizumab alone and showed stable disease. Stable disease was maintained for at least 2 months in one
312 case (59) (**Figure 4**), while in the second case stable disease was demonstrated 6 months after the
313 administration of three cycles of bevacizumab (62) (**Figure 4**). A third case of a lactotroph carcinoma,
314 progressed after ICI failure on combined therapy with bevacizumab, temsirolimus, and valproic acid (64).
315 One aggressive somatotroph adenoma received concomitant bevacizumab and temozolomide, and showed
316 partial response (111).
317 One aggressive non-immunoreactive adenoma was treated with bevacizumab monotherapy, and showed
318 stable disease, which was maintained for 18 months (106) (**Figure 4**).
319 Four tumors of unknown subtype were treated with bevacizumab alone and showed partial response in one
320 case, stable disease in one case, and progressive disease in one case (3) (**Figure 4**). The duration of
321 maintained partial response, and stable disease, respectively, were not reported. The radiological outcome
322 is unknown in the fourth case (112). An additional four tumors of unknown subtype were treated with
323 combined bevacizumab and temozolomide. The radiological responses consisted of a partial response in
324 two cases, progressive disease in one case, and unknown radiological response in the fourth case (3).
325 The potential benefit of adding bevacizumab to first-course temozolomide is hard to evaluate at this time
326 because of the generally good efficacy of first-course temozolomide, combined with the small number of
327 cases that have been published with combination therapy. However, regarding the combination of
328 bevacizumab with second-course temozolomide, in the European Society for Endocrinology survey, out of
329 18 patients who received second-course temozolomide, only two patients showed partial response, of whom
330 one received concomitant bevacizumab (113). Therefore, if second-course temozolomide is envisioned,
331 given the generally poor response that has been reported, addition of bevacizumab might be considered.
332 Reported adverse events consisted of epistaxis and hypertension in one case (59), nephritis in another case
333 (62), and petechia and fatigue in a third case (106).

334

335 Tyrosine kinase inhibitors

336 Two tumors, one corticotroph carcinoma and a tumor of unknown type, were treated with sunitinib
337 monotherapy and showed progression (3,108) (**Figure 4**). Any eventual adverse events were not reported.
338 An aggressive somatotroph adenoma treated concomitantly with apatinib and temozolomide showed
339 radiological partial response. Adverse events included hypertension, and hand and foot syndrome (107).

340

341 b) Perspectives

342 While the VEGF/VEGFR pathway has been thus far the most targeted pathway in cancer, tumors can be
343 inherently resistant or can become resistant to inhibition of the VEGF/VEGFR axis (67), and thus additional
344 therapeutic strategies are needed, for example vascular normalization (93). Strategies to achieve vascular
345 normalization include the use of agonists of dopamine receptor type 2, which have been found to have an
346 effect on both pericytes and endothelial cells (93,114,115). Interestingly, in a mouse prolactinoma model,
347 bromocriptine not only blocked tumor growth, but also restored the balance between anti-angiogenic and
348 pro-angiogenic factors, and normalized blood vessels (116). Of note, in the same prolactinoma model,
349 axitinib (a TKI inhibiting VEGFRs) restrained tumor growth and improved vascular remodeling, while
350 when bromocriptine was combined with axitinib, intratumoral hemorrhage was suppressed and blood vessel
351 perfusion was restored (116). This is consistent with the complementary effect that VEGF/VEGFR pathway
352 inhibitors and drugs targeting alternative angiogenesis pathways were shown to have, and highlight the role
353 that combination therapies might have when targeting angiogenesis (116–118).

354 Interestingly, the angiopoietin-2/angiopoietin-1 receptor axis, classically regarded as an endothelial cell
355 axis, was recently also shown to be active in pituitary tumor cells. Both *in vitro* and *in vivo* evidence
356 indicated that this axis was an exploitable therapeutic target in PAs, most notably in NFPA, and therefore
357 the use of anti-angiopoietin biologicals or angiopoietin-1 receptor inhibitors might be warranted in these
358 tumors (22).

359

360 5. Extracellular matrix and its remodeling

361 The ECM consists of a dynamic 3D network of macromolecules (proteins, proteoglycans,
362 glycosaminoglycans etc.), in which soluble factors (cytokines, growth factors etc.) are embedded (1,119–
363 121). The ECM is implicated in the differentiation, adhesion, migration, proliferation, and survival of cells
364 in both physiological and pathological conditions (121–123). In cancer, the ECM might also influence
365 treatment efficacy, for example, ECM attachment to cancer cells might lead to resistance to apoptosis, a
366 desmoplastic stroma might represent a physical barrier for chemotherapy, while soluble factors might
367 activate survival signaling pathways resulting in resistance to cell death (52).

368 Regarding the presence and distribution of ECM macromolecules and of integrins (cell membrane receptors
369 that transduce ECM signals to cells), differences have been shown to exist between PAs and the NPG
370 (25,124,125). For example, vitronectin was found in PA TME, but not in the NPG, while tumor cells
371 showed a greater range of expression of integrin subunits, simultaneously with the downregulation of $\alpha_3\beta_1$
372 expression and the loss of $\alpha_6\beta_4$ expression compared with the NPG (125). From a functional viewpoint,
373 laminin expression was found to gradually decrease from the NPG stage to the lactotroph hyperplasia stage
374 and then to the prolactinoma stage, and, in addition, laminin was found to inhibit GH3 and AtT-20 cell
375 proliferation (25,32). Several other ECM macromolecules were also found to impact tumor cell
376 proliferation, invasion and migration (26,32) – see **Table 1**, suggesting ECM macromolecules might indeed
377 play a role in PA tumorigenesis. Moreover, ECM macromolecules (laminin, collagen I, and fibronectin)
378 were found to inhibit hormonal production/secretion (25,32). Interestingly, the same ECM macromolecules
379 did not impact the hormonal production/secretion of normal rat pituitary cells, suggesting a potential change
380 in integrin expression during tumorigenesis (25,32).

381 Regarding ECM remodeling, numerous studies have looked at matrix metalloproteinases (MMPs), enzymes
382 that degrade and remodel the ECM, while in the process releasing the molecules that are embedded in it,
383 and also at tissue inhibitors of metalloproteinases (TIMPs), molecules that regulate MMPs (1). Lower TIMP
384 levels and higher levels of MMP activity were found in PA-derived conditioned medium compared to
385 normal pituitary explant-derived conditioned medium (27). *TIMP-3* expression was associated with the
386 deposition of fibrous matrix in PAs (126). In both PAs and PCs, MMPs and TIMPs have been linked to

387 multiple characteristics related to aggressiveness (27,29,31,33,42,43) – see **Table 1**. In addition, by
388 releasing growth factors embedded in a synthetic matrix (matrigel), MMPs were shown, *in vitro*, to have a
389 role in hormone secretion by pituitary tumor cell lines (27). MMPs have also been linked to angiogenesis
390 in PAs, with MMP-9 positive prolactinomas showing higher vascular densities than MMP-9 negative
391 prolactinomas (29). These data are consistent with the roles the MMP-system plays in other cancers, notably
392 in progression and angiogenesis (127). Other than MMPs, the urokinase plasminogen activator (uPA)
393 system is another key player in ECM remodeling and has been shown to be involved in cancer progression,
394 including in cell growth, cell migration, epithelial–mesenchymal transition, and angiogenesis (128). uPA,
395 uPA receptor, tissue-type plasminogen activator, and plasminogen activator inhibitor-1, were also found to
396 be expressed in PAs, and a higher uPA expression was noted in PAs when compared to the NPG (31). The
397 potential impact of the uPA-system, as well as of other ECM components, on aggressiveness-related
398 characteristics (4,25–27,29,31–33,42–47) is summarized in **Table 1**. Therefore, both the ECM and ECM
399 remodeling appear to have important roles in the biology of PAs, and may constitute potential treatment
400 targets. Appealing candidates include the targeting of the MMP-system (129,130) and targeting of integrins
401 (131,132).

402

403 **Conclusions**

404 Similar to the case in other cancers, the TME represents a promising lead for understanding of PA biology
405 beyond genetics and epigenetics, and promises to be an important tool for therapeutic purposes. TILs,
406 TAMs, folliculostellate cells, tumor-associated fibroblasts, angiogenesis, as well as the ECM and ECM
407 remodelling, all have complex roles in the biology of PAs, being linked to their functionality, size, invasion,
408 proliferation, progression/recurrence, and to their response to treatment. From a therapeutic viewpoint,
409 immune-checkpoint inhibitors and bevacizumab have already shown some efficacy in treating aggressive
410 PAs and PCs, and the use of numerous other TME-targeting therapies can be foreseen. Further work is still
411 required for a better understanding of TME composition, its roles, and of the extensive crosstalk that takes
412 place between adenoma cells and the TME, as well as between the different components of the TME.

413 Ideally, future studies will integrate a more intricate and complete view of the network of interactions that
414 may exist between tumor cells and the components of the PA TME. Additionally, given the potential
415 differences in TME composition and involvement in different subtypes of PAs, it will be important to study
416 each of the histological subtypes of PA separately.

417

418 **Bibliography**

- 419 1. **Balkwill FR, Capasso M, Hagemann T.** The tumor microenvironment at a glance. *Journal of Cell*
420 *Science* 2012;125(23):5591–5596.
- 421 2. **Hui L, Chen Y.** Tumor microenvironment: Sanctuary of the devil. *Cancer Letters* 2015;368(1):7–
422 13.
- 423 3. **Ilie MD, Vasiljevic A, Raverot G, Bertolino P.** The Microenvironment of Pituitary Tumors—
424 Biological and Therapeutic Implications. *Cancers* 2019;11(10):1605.
- 425 4. **Marques P, Grossman AB, Korbonits M.** The tumour microenvironment of pituitary
426 neuroendocrine tumours. *Frontiers in Neuroendocrinology* 2020;58:100852.
- 427 5. **Fridman WH, Zitvogel L, Sautès-Fridman C, Kroemer G.** The immune contexture in cancer
428 prognosis and treatment. *Nature Reviews Clinical Oncology* 2017;14(12):717–734.
- 429 6. **Rossi ML, Jones NR, Esiri MM, Havas L, Izzi MAI, Coakham HB.** Mononuclear Cell Infiltrate and
430 Hla-Dr Expression in 28 Pituitary Adenomas. *Tumori Journal* 1990;76(6):543–547.
- 431 7. **Wang P, Wang T, Yang Y, Yao K, Li Z, Li YM, Yan C-X.** The expression profile of PD-L1 and CD8+
432 lymphocyte in pituitary adenomas indicating for immunotherapy. *Journal of Neuro-Oncology*
433 2018;139(1):89–95.
- 434 8. **Heshmati HM, Kujas M, Casanova S, Wollan PC, Racadot J, Effenterre RV, Derome PJ, Turpin G.**
435 Prevalence of Lymphocytic Infiltrate in 1400 Pituitary Adenomas. *Endocrine Journal* 1998;45(3):357–361.
- 436 9. **Sato M, Tamura R, Tamura H, Mase T, Kosugi K, Morimoto Y, Yoshida K, Toda M.** Analysis of
437 Tumor Angiogenesis and Immune Microenvironment in Non-Functional Pituitary Endocrine Tumors.
438 *Journal of Clinical Medicine* 2019;8(5):695:1–12.
- 439 10. **Lu J-Q, Adam B, Jack AS, Lam A, Broad RW, Chik CL.** Immune Cell Infiltrates in Pituitary
440 Adenomas: More Macrophages in Larger Adenomas and More T Cells in Growth Hormone Adenomas.
441 *Endocrine Pathology* 2015;26(3):263–272.
- 442 11. **Lupi I, Manetti L, Caturegli P, Menicagli M, Cosottini M, Iannelli A, Acerbi G, Bevilacqua G,**
443 **Bogazzi F, Martino E.** Tumor Infiltrating Lymphocytes But Not Serum Pituitary Antibodies Are Associated
444 with Poor Clinical Outcome after Surgery in Patients with Pituitary Adenoma. *The Journal of Clinical*
445 *Endocrinology & Metabolism* 2010;95(1):289–296.

- 446 12. **Barry S, Carlsen E, Marques P, Stiles CE, Gadaleta E, Berney DM, Roncaroli F, Chelala C,**
447 **Solomou A, Herincs M, Caimari F, Grossman AB, Crnogorac-Jurcevic T, Haworth O, Gaston-Massuet C,**
448 **Korbonits M.** Tumor microenvironment defines the invasive phenotype of AIP-mutation-positive
449 pituitary tumors. *Oncogene* 2019;38:5381–5395.
- 450 13. **Mei Y, Bi WL, Greenwald NF, Du Z, Agar NYR, Kaiser UB, Woodmansee WW, Reardon DA,**
451 **Freeman GJ, Fecci PE, Laws ER, Santagata S, Dunn GP, Dunn IF.** Increased expression of programmed
452 death ligand 1 (PD-L1) in human pituitary tumors. *Oncotarget* 2016;7(47):76565–76576.
- 453 14. **Principe M, Chanal M, Ilie MD, Ziverec A, Vasiljevic A, Jouanneau E, Hennino A, Raverot G,**
454 **Bertolino P.** Immune Landscape of Pituitary Neuroendocrine Tumours Reveals Association between
455 Macrophages and Gonadotroph-Tumour Invasion. *The Journal of Clinical Endocrinology & Metabolism*
456 2020. doi:10.1210/clinem/dgaa520.
- 457 15. **Marques P, Barry S, Carlsen E, Collier D, Ronaldson A, Awad S, Dorward N, Grieve J, Mendoza**
458 **N, Muquit S, Grossman AB, Balkwill F, Korbonits M.** Chemokines modulate the tumour
459 microenvironment in pituitary neuroendocrine tumours. *Acta Neuropathologica Communications*
460 2019;7(1). doi:10.1186/s40478-019-0830-3.
- 461 16. **Jacobs JFM, Idema AJ, Bol KF, Nierkens S, Grauer OM, Wesseling P, Grotenhuis JA,**
462 **Hoogerbrugge PM, de Vries IJM, Adema GJ.** Regulatory T cells and the PD-L1/PD-1 pathway mediate
463 immune suppression in malignant human brain tumors. *Neuro-Oncology* 2009;11(4):394–402.
- 464 17. **Kemeny HR, Elsamadicy AA, Farber SH, Champion CD, Lorrey SJ, Chongsathidkiet P,**
465 **Woroniecka KI, Cui X, Shen SH, Rhodin KE, Tsvankin V, Everitt J, Sanchez-Perez L, Healy P, McLendon**
466 **RE, Codd PJ, Dunn IF, Fecci PE.** Targeting PD-L1 Initiates Effective Antitumor Immunity in a Murine
467 Model of Cushing Disease. *Clinical Cancer Research* 2020;26(5):1141–1151.
- 468 18. **Mei Y, Bi WL, Agolia J, Hu C, Giantini Larsen AM, Meredith DM, Al Abdulmohsen S, Bale T,**
469 **Dunn GP, Abedalthagafi M, Dunn IF.** Immune profiling of pituitary tumors reveals variations in immune
470 infiltration and checkpoint molecule expression. *Pituitary* 2021;24(3):359–373.
- 471 19. **Iacovazzo D, Chiloiro S, Carlsen E, Bianchi A, Giampietro A, Tartaglione T, Bima C, Braccacia**
472 **ME, Lugli F, Lauretti L, Anile C, Gessi M, Colosimo C, Rindi G, Pontecorvi A, Korbonits M, De Marinis L.**
473 Tumour-infiltrating cytotoxic T lymphocytes in somatotroph pituitary neuroendocrine tumours.
474 *Endocrine* 2020;67(3):651–658.
- 475 20. **Iuchi T, Saeki N, Osato K, Yamaura A.** Proliferation, Vascular Endothelial Growth Factor
476 Expression and Cavernous Sinus Invasion in Growth Hormone Secreting Pituitary Adenomas. *Acta*
477 *Neurochirurgica* 2000;142(12):1345–1351.
- 478 21. **Zhang A, Xu Y, Xu H, Ren J, Meng T, Ni Y, Zhu Q, Zhang W-B, Pan Y-B, Jin J, Bi Y, Wu ZB, Lin S,**
479 **Lou M.** Lactate-induced M2 polarization of tumor-associated macrophages promotes the invasion of
480 pituitary adenoma by secreting CCL17. *Theranostics* 2021;11(8):3839–3852.
- 481 22. **Karabid NM, Wiedemann T, Gulde S, Mohr H, Segaran RC, Geppert J, Rohm M, Vitale G,**
482 **Gaudenzi G, Dicitore A, Ankerst DP, Chen Y, Braren R, Kaissis G, Schilling F, Schillmaier M, Eisenhofer**
483 **G, Herzig S, Roncaroli F, Honegger JB, Pellegata NS.** Angpt2/Tie2 autostimulatory loop controls
484 tumorigenesis. *EMBO Mol Med* 2022. doi:10.15252/emmm.202114364.

- 485 23. **Lv L, Zhang S, Hu Y, Zhou P, Gao L, Wang M, Sun Z, Chen C, Yin S, Wang X, Jiang S.** Invasive
486 Pituitary Adenoma-Derived Tumor-Associated Fibroblasts Promote Tumor Progression both In Vitro and
487 In Vivo. *Experimental and Clinical Endocrinology & Diabetes* 2018;126(04):213–221.
- 488 24. **Marques P, Barry S, Carlsen E, Collier D, Ronaldson A, Awad S, Dorward N, Grieve J, Mendoza
489 N, Muquit S, Grossman AB, Balkwill F, Korbonits M.** Pituitary tumour fibroblast-derived cytokines
490 influence tumour aggressiveness. *Endocrine-Related Cancer* 2019;26(12):853–865.
- 491 25. **Kuchenbauer F, Theodoropoulou M, Hopfner U, Stalla J, Renner U, Tonn JC, Low MJ, Arzt E,
492 Stalla GK, Páez-Pereda M.** Laminin inhibits lactotroph proliferation and is reduced in early prolactinoma
493 development. *Molecular and Cellular Endocrinology* 2003;207(1–2):13–20.
- 494 26. **Azorín E, Solano-Agama C, Mendoza-Garrido ME.** The invasion mode of GH3 cells is conditioned
495 by collagen subtype, and its efficiency depends on cell–cell adhesion. *Archives of Biochemistry and
496 Biophysics* 2012;528(2):148–155.
- 497 27. **Paez-Pereda M, Ledda MF, Goldberg V, Chervín A, Carrizo G, Molina H, Müller A, Renner U,
498 Podhajcer O, Arzt E, Stalla GK.** High Levels of Matrix Metalloproteinases Regulate Proliferation and
499 Hormone Secretion in Pituitary Cells1. *The Journal of Clinical Endocrinology & Metabolism*
500 2000;85(1):263–269.
- 501 28. **Turner H, Nagy Z, Gatter K, Esiri M, Harris A, Wass J.** Angiogenesis in pituitary adenomas -
502 relationship to endocrine function, treatment and outcome. *Journal of Endocrinology* 2000;165(2):475–
503 481.
- 504 29. **Turner HE, Nagy Zs, Esiri MM, Harris AL, Wass JAH.** Role of Matrix Metalloproteinase 9 in
505 Pituitary Tumor Behavior. *The Journal of Clinical Endocrinology & Metabolism* 2000;85(8):2931–2935.
- 506 30. **Cai L, Leng ZG, Guo YH, Lin SJ, Wu ZR, Su ZP, Lu JL, Wei LF, Zhuge QC, Jin K, Wu ZB.** Dopamine
507 agonist resistance-related endocan promotes angiogenesis and cells viability of prolactinomas.
508 *Endocrine* 2016;52(3):641–651.
- 509 31. **Knappe UJ, Hagel C, Lisboa BW, Wilczak W, Ludecke DK, Saeger W.** Expression of serine
510 proteases and metalloproteinases in human pituitary adenomas and anterior pituitary lobe tissue. *Acta
511 Neuropathologica* 2003;106(5):471–478.
- 512 32. **Kuchenbauer F, Hopfner U, Stalla J, Arzt E, Stalla GK, Páez-Pereda M.** Extracellular matrix
513 components regulate ACTH production and proliferation in corticotroph tumor cells. *Molecular and
514 Cellular Endocrinology* 2001;175(1–2):141–148.
- 515 33. **Hui P, Xu X, Xu L, Hui G, Wu S, Lan Q.** Expression of MMP14 in invasive pituitary adenomas:
516 relationship to invasion and angiogenesis. *Int J Clin Exp Pathol* 2015;8(4):3556–3567.
- 517 34. **He W, Huang L, Shen X, Yang Y, Wang D, Yang Y, Zhu X.** Relationship between RSUME and HIF-
518 1 α /VEGF-A with invasion of pituitary adenoma. *Gene* 2017;603:54–60.
- 519 35. **Ilie MD, Vasiljevic A, Chanal M, Gadot N, Chinezu L, Jouanneau E, Hennino A, Raverot G,
520 Bertolino P.** Intratumoural spatial distribution of S100B + folliculostellate cells is associated with
521 proliferation and expression of FSH and ER α in gonadotroph tumours. *acta neuropathol commun*
522 2022;10(1):18.

- 523 36. **Sánchez-Ortiga R, Sánchez-Tejada L, Moreno-Perez O, Riesgo P, Niveiro M, Picó Alfonso AM.**
524 Over-expression of vascular endothelial growth factor in pituitary adenomas is associated with
525 extrasellar growth and recurrence. *Pituitary* 2013;16(3):370–377.
- 526 37. **Yagnik G, Rutkowski MJ, Shah SS, Aghi MK.** Stratifying nonfunctional pituitary adenomas into
527 two groups distinguished by macrophage subtypes. *Oncotarget* 2019;10(22):2212–2223.
- 528 38. **Wang S, Wu Z, Wei L, Zhang J.** Endothelial cell-specific molecule-1 as an invasiveness marker for
529 pituitary null cell adenoma. *BMC Endocr Disord* 2019;19(1):90.
- 530 39. **Matano F, Yoshida D, Ishii Y, Tahara S, Teramoto A, Morita A.** Endocan, a new invasion and
531 angiogenesis marker of pituitary adenomas. *Journal of Neuro-Oncology* 2014;117(3):485–491.
- 532 40. **Miao Y, Zong M, Jiang T, Yuan X, Guan S, Wang Y, Zhou D.** A comparative analysis of ESM-1 and
533 vascular endothelial cell marker (CD34/CD105) expression on pituitary adenoma invasion. *Pituitary*
534 2016;19(2):194–201.
- 535 41. **Jia W, Sander AJ, Jia G, Ni M, Liu X, Lu R, Jiang WG.** Vascular endothelial growth inhibitor (VEGI)
536 is an independent indicator for invasion in human pituitary adenomas. *Anticancer Res* 2013;33(9):3815–
537 3822.
- 538 42. **Liu W, Matsumoto Y, Okada M, Miyake K, Kunishio K, Kawai N, Tamiya T, Nagao S.** Matrix
539 metalloproteinase 2 and 9 expression correlated with cavernous sinus invasion of pituitary adenomas. *J.*
540 *Med. Invest.* 2005;52(3–4):151–158.
- 541 43. **Guo H, Sun Z, Wei J, Xiang Y, Qiu L, Guo L, Zhao W, Xu Z, Mao J.** Expressions of Matrix
542 Metalloproteinases-9 and Tissue Inhibitor of Metalloproteinase-1 in Pituitary Adenomas and Their
543 Relationships with Prognosis. *Cancer Biotherapy and Radiopharmaceuticals* 2019;34(1):1–6.
- 544 44. **Xing B, Kong YG, Yao Y, Lian W, Wang RZ, Ren ZY.** Study on the expression levels of CXCR4,
545 CXCL12, CD44, and CD147 and their potential correlation with invasive behaviors of pituitary adenomas.
546 *Biomed Environ Sci* 2013;26(7):592–598.
- 547 45. **Wu JL, Qiao JY, Duan QH.** Significance of TNF- α and IL-6 expression in invasive pituitary
548 adenomas. *Genet Mol Res* 2016;15(1). doi:10.4238/gmr.15017502.
- 549 46. **Qiu L, He D, Fan X, Li Z, Liao C, Zhu Y, Wang H.** The expression of interleukin (IL)-17 and IL-17
550 receptor and MMP-9 in human pituitary adenomas. *Pituitary* 2011;14(3):266–275.
- 551 47. **Wang F, Shu K, Lei T, Xue D.** The expression of integrin β 1 and FAK in pituitary adenomas and
552 their correlation with invasiveness. *Journal of Huazhong University of Science and Technology [Medical*
553 *Sciences]* 2008;28(5):572–575.
- 554 48. **Cornelius A, Cortet-Rudelli C, Assaker R, Kerdraon O, Gevaert M-H, Prévot V, Lassalle P,**
555 **Trouillas J, Delehedde M, Maurage C-A.** Endothelial Expression of Endocan Is Strongly Associated with
556 Tumor Progression in Pituitary Adenoma: Endocan in Pituitary Adenoma. *Brain Pathology*
557 2012;22(6):757–764.

- 558 49. **Jugenburg M, Kovacs K, Stefaneanu L, Scheithauer BW.** Vasculature in nontumorous
559 hypophyses, pituitary adenomas, and carcinomas: A quantitative morphologic study. *Endocrine*
560 *Pathology* 1995;6(2):115–124.
- 561 50. **Vidal S, Kovacs K, Horvath E, Scheithauer BW, Kuroki T, Lloyd RV.** Microvessel density in
562 pituitary adenomas and carcinomas. *Virchows Archiv* 2001;438(6):595–602.
- 563 51. **Gruppetta M, Formosa R, Falzon S, Ariff Scicluna S, Falzon E, Degeatano J, Vassallo J.**
564 Expression of cell cycle regulators and biomarkers of proliferation and regrowth in human pituitary
565 adenomas. *Pituitary* 2017;20(3):358–371.
- 566 52. **Maman S, Witz IP.** A history of exploring cancer in context. *Nature Reviews Cancer*
567 2018;18(6):359–376.
- 568 53. **Yeung JT, Vesely MD, Miyagishima DF.** In silico analysis of the immunological landscape of
569 pituitary adenomas. *Journal of Neuro-Oncology* 2020;147(3):595–598.
- 570 54. **Condeelis J, Pollard JW.** Macrophages: Obligate Partners for Tumor Cell Migration, Invasion, and
571 Metastasis. *Cell* 2006;124(2):263–266.
- 572 55. **Fujiwara K, Yatabe M, Tofrizal A, Jindatip D, Yashiro T, Nagai R.** Identification of M2
573 macrophages in anterior pituitary glands of normal rats and rats with estrogen-induced prolactinoma.
574 *Cell Tissue Res* 2017;368(2):371–378.
- 575 56. **Zhou W, Zhang C, Zhang D, Peng J, Ma S, Wang X, Guan X, Li P, Li D, Jia G, Jia W.**
576 Comprehensive analysis of the immunological landscape of pituitary adenomas: implications of
577 immunotherapy for pituitary adenomas. *J Neurooncol* 2020;149(3):473–487.
- 578 57. **Lin AL, Jonsson P, Tabar V, Yang TJ, Cuaron J, Beal K, Cohen M, Postow M, Rosenblum M, Shia**
579 **J, DeAngelis LM, Taylor BS, Young RJ, Geer EB.** Marked Response of a Hypermutated ACTH-Secreting
580 Pituitary Carcinoma to Ipilimumab and Nivolumab. *The Journal of Clinical Endocrinology & Metabolism*
581 2018;103(10):3925–3930.
- 582 58. **Lin AL, Tabar V, Young RJ, Cohen M, Cuaron J, Yang TJ, Rosenblum M, Rudneva VA, Geer EB,**
583 **Bodei L.** Synergism of Checkpoint Inhibitors and Peptide Receptor Radionuclide Therapy in the
584 Treatment of Pituitary Carcinoma. *Journal of the Endocrine Society* 2021;5(10):bvab133.
- 585 59. **Duhamel C, Ilie MD, Salle H, Nassouri AS, Gaillard S, Deluche E, Assaker R, Mortier L, Cortet C,**
586 **Raverot G.** Immunotherapy in Corticotroph and Lactotroph Aggressive Tumors and Carcinomas: Two
587 Case Reports and a Review of the Literature. *Journal of Personalized Medicine* 2020;10(3):88.
- 588 60. **Sol B, de Filette JM k., Awada G, Raeymaeckers S, Aspeslagh S, Andreescu C e., Neyns B,**
589 **Velkeniers B.** Immune Checkpoint Inhibitor Therapy for ACTH-Secreting Pituitary Carcinoma: a new
590 emerging treatment? *European Journal of Endocrinology* 2020;184(1):K1–K5.
- 591 61. **Caccese M, Barbot M, Ceccato F, Padovan M, Gardiman MP, Fassan M, Denaro L, Emanuelli E,**
592 **D’Avella D, Scaroni C, Zagonel V, Lombardi G.** Rapid disease progression in patient with mismatch-
593 repair deficiency pituitary ACTH-secreting adenoma treated with checkpoint inhibitor pembrolizumab:
594 *Anti-Cancer Drugs* 2020;31(2):199–204.

- 595 62. **Lamb LS, Sim H-W, McCormack AI.** Case Report: A Case of Pituitary Carcinoma Treated With
596 Sequential Dual Immunotherapy and Vascular Endothelial Growth Factor Inhibition Therapy. *Frontiers in*
597 *Endocrinology* 2020;11. doi:10.3389/fendo.2020.576027.
- 598 63. **Goichot B, Taquet M, Baltzinger P, Baloglu S, Gravaud M, Malouf GG, Noël G, Imperiale A.**
599 Should pituitary carcinoma be treated using a NET-like approach? A case of complete remission of a
600 metastatic malignant prolactinoma with multimodal therapy including immunotherapy. *Clinical*
601 *Endocrinology* 2021:cen.14645.
- 602 64. **Majd N, Waguespack SG, Janku F, Fu S, Penas-Prado M, Xu M, Alshawa A, Kamiya-Matsuoka C,**
603 **Raza SM, McCutcheon IE, Naing A.** Efficacy of pembrolizumab in patients with pituitary carcinoma:
604 report of four cases from a phase II study. *J Immunother Cancer* 2020;8(2):e001532.
- 605 65. **Ilie M-D, Vasiljevic A, Jouanneau E, Raverot G.** Immunotherapy in aggressive pituitary tumors
606 and carcinomas: a systematic review. *Endocrine-Related Cancer* 2022. doi:10.1530/ERC-22-0037.
- 607 66. **Rahma OE, Hodi FS.** The Intersection between Tumor Angiogenesis and Immune Suppression.
608 *Clin Cancer Res* 2019;25(18):5449–5457.
- 609 67. **Ramjiawan RR, Griffioen AW, Duda DG.** Anti-angiogenesis for cancer revisited: Is there a role
610 for combinations with immunotherapy? *Angiogenesis* 2017;20(2):185–204.
- 611 68. **Wilky BA.** Immune checkpoint inhibitors: The linchpins of modern immunotherapy.
612 *Immunological Reviews* 2019;290(1):6–23.
- 613 69. **Deng L, Liang H, Burnette B, Beckett M, Darga T, Weichselbaum RR, Fu Y-X.** Irradiation and
614 anti-PD-L1 treatment synergistically promote antitumor immunity in mice. *Journal of Clinical*
615 *Investigation* 2014;124(2):687–695.
- 616 70. **Ilie MD, Raverot G.** Treatment options for gonadotroph tumors: current state and perspectives.
617 *The Journal of Clinical Endocrinology & Metabolism* 2020;105(10):dgaa497.
- 618 71. **Wang Z, Guo X, Gao L, Deng K, Lian W, Bao X, Feng M, Duan L, Zhu H, Xing B.** The Immune
619 Profile of Pituitary Adenomas and a Novel Immune Classification for Predicting Immunotherapy
620 Responsiveness. *The Journal of Clinical Endocrinology & Metabolism* 2020;105(9):e3207–e3223.
- 621 72. **Pittet MJ, Michielin O, Migliorini D.** Clinical relevance of tumour-associated macrophages. *Nat*
622 *Rev Clin Oncol* 2022. doi:10.1038/s41571-022-00620-6.
- 623 73. **Hofler H, Walter GF, Denk H.** Immunohistochemistry of folliculo-stellate cells in normal human
624 adenohypophyses and in pituitary adenomas. *Acta Neuropathol* 1984;65(1):35–40.
- 625 74. **Allaerts W, Vankelecom H.** History and perspectives of pituitary folliculo-stellate cell research.
626 *European Journal of Endocrinology* 2005;153(1):1–12.
- 627 75. **Nakajima T, Yamaguchi H, Takahashi K.** S100 protein in folliculostellate cells of the rat pituitary
628 anterior lobe. *Brain Research* 1980;191(2):523–531.
- 629 76. **Morris J, Christian H.** Folliculo-stellate Cells: Paracrine Communicators in the Anterior Pituitary.
630 *The Open Neuroendocrinology Journal* 2011;4(1):77–89.

- 631 77. **Denef C.** Paracrinicity: the story of thirty years of cellular pituitary crosstalk. *Journal of*
632 *Neuroendocrinology* 2007;20:1–70.
- 633 78. **Fauquier T, Guérineau NC, McKinney RA, Bauer K, Mollard P.** Folliculostellate cell network: A
634 route for long-distance communication in the anterior pituitary. *Proceedings of the National Academy of*
635 *Sciences* 2001;98(15):8891–8896.
- 636 79. **Hodson DJ, Legros C, Desarménien MG, Guérineau NC.** Roles of connexins and pannexins in
637 (neuro)endocrine physiology. *Cell. Mol. Life Sci.* 2015;72(15):2911–2928.
- 638 80. **Devnath S, Inoue K.** An Insight to Pituitary Folliculo-Stellate Cells. *Journal of Neuroendocrinology*
639 2008;20(6):687–691.
- 640 81. **Claudius L, Yoshimi Y, Yoichiro H, Gabriel M, Koichi M.** Phagocytotic removal of apoptotic
641 endocrine cells by folliculostellate cells and its functional implications in clusterin accumulation in
642 pituitary colloids in helmeted guinea fowl (*Numida meleagris*). *Acta Histochemica* 2006;108(1):69–80.
- 643 82. **Kato Y, Yoshida S, Kato T.** New insights into the role and origin of pituitary S100 β -positive cells.
644 *Cell Tissue Res* 2021;386(2):227–237.
- 645 83. **Iwaki T, Kondo A, Takeshita I, Nakagaki H, Kitamura K, Tateishi J.** Proliferating potential of
646 folliculo-stellate cells in human pituitary adenomas: Immunohistochemical and electron microscopic
647 analysis. *Acta Neuropathol* 1986;71(3–4):233–242.
- 648 84. **Voit D, Saeger W, Lüdecke DK.** Folliculo-stellate Cells in Pituitary Adenomas of Patients with
649 Acromegaly. *Pathology - Research and Practice* 1999;195(3):143–147.
- 650 85. **Allaerts W, Fluitsma DM, Hoefsmit ECM, Jeucken PHM, Morreau H, Bosnian FT, Drexhage HA.**
651 Immunohistochemical, Morphological and Ultrastructural Resemblance between Dendritic Cells and
652 Folliculo-Stellate Cells in Normal Human and Rat Anterior Pituitaries. *Journal of Neuroendocrinology*
653 1996;8(1):17–29.
- 654 86. **Vajtai I, Kappeler A, Sahli R.** Folliculo-stellate cells of “true dendritic” type are involved in the
655 inflammatory microenvironment of tumor immunosurveillance of pituitary adenomas. *Diagnostic*
656 *Pathology* 2007;2(1):20:1–4.
- 657 87. **Ziani L, Chouaib S, Thiery J.** Alteration of the Antitumor Immune Response by Cancer-Associated
658 Fibroblasts. *Frontiers in Immunology* 2018;9:414:1–14.
- 659 88. **Kalluri R.** The biology and function of fibroblasts in cancer. *Nature Reviews Cancer*
660 2016;16(9):582–598.
- 661 89. **LeBleu VS, Kalluri R.** A peek into cancer-associated fibroblasts: origins, functions and
662 translational impact. *Disease Models & Mechanisms* 2018;11(4):dmm029447.
- 663 90. **Duluc C, Moatassim-Billah S, Chalabi-Dchar M, Perraud A, Samain R, Breibach F, Gayral M,**
664 **Cordelier P, Delisle M, Bousquet-Dubouch M, Tomasini R, Schmid H, Mathonnet M, Pyronnet S,**
665 **Martineau Y, Bousquet C.** Pharmacological targeting of the protein synthesis mTOR /4E- BP 1 pathway in
666 cancer-associated fibroblasts abrogates pancreatic tumour chemoresistance. *EMBO Molecular Medicine*
667 2015;7(6):735–753.

- 668 91. **Chen X, Song E.** Turning foes to friends: targeting cancer-associated fibroblasts. *Nature Reviews*
669 *Drug Discovery* 2019;18(2):99–115.
- 670 92. **Donnem T, Reynolds AR, Kuczynski EA, Gatter K, Vermeulen PB, Kerbel RS, Harris AL, Pezzella**
671 **F.** Non-angiogenic tumours and their influence on cancer biology. *Nat Rev Cancer* 2018;18(5):323–336.
- 672 93. **Viallard C, Larrivé B.** Tumor angiogenesis and vascular normalization: alternative therapeutic
673 targets. *Angiogenesis* 2017;20(4):409–426.
- 674 94. **Ferrara N.** Vascular Endothelial Growth Factor: Basic Science and Clinical Progress. *Endocrine*
675 *Reviews* 2004;25(4):581–611.
- 676 95. **Folkman J.** Tumor Angiogenesis: Therapeutic Implications. *New England Journal of Medicine*
677 1971;285(21):1182–1186.
- 678 96. **Turner HE, Nagy Z, Gatter KC, Esiri MM, Harris AL, Wass JAH.** Angiogenesis in Pituitary
679 Adenomas and the Normal Pituitary Gland. *The Journal of Clinical Endocrinology & Metabolism*
680 2000;85(3):1159–1162.
- 681 97. **Takada K, Yamada S, Teramoto A.** Correlation Between Tumor Vascularity and Clinical Findings
682 in Patients with Pituitary Adenomas. *EP* 2004;15(2):131–140.
- 683 98. **Viacava P, Gasperi M, Acerbi G, Manetti L, Cecconi E, Bonadio AG, Naccarato AG, Acerbi F,**
684 **Parenti G, Lupi I, Genovesi M, Martino E.** Microvascular density and vascular endothelial growth factor
685 expression in normal pituitary tissue and pituitary adenomas. *J Endocrinol Invest* 2003;26(1):23–28.
- 686 99. **Marques P, Barry S, Carlsen E, Collier D, Ronaldson A, Dorward N, Grieve J, Mendoza N, Nair R,**
687 **Muquit S, Grossman AB, Korbonits M.** The role of the tumour microenvironment in the angiogenesis of
688 pituitary tumours. *Endocrine* 2020;70(3):593–606.
- 689 100. **Lloyd RV, Scheithauer BW, Kuroki T, Vidal S, Kovacs K, Stefanescu L.** Vascular endothelial
690 growth factor (VEGF) expression in human pituitary adenomas and carcinomas. *Endocrine Pathology*
691 1999;10(3):229–235.
- 692 101. **Kurosaki M, Saeger W, Abe T, Lüdecke DK.** Expression of vascular endothelial growth factor in
693 growth hormone-secreting pituitary adenomas: special reference to the octreotide treatment.
694 *Neurological Research* 2008;30(5):518–522.
- 695 102. **Cristina C, Perez-Millan MI, Luque G, Dulce RA, Sevlever G, Berner SI, Becu-Villalobos D.** VEGF
696 and CD31 Association in Pituitary Adenomas. *Endocrine Pathology* 2010;21(3):154–160.
- 697 103. **Niveiro M, Aranda FI, Peiró G, Alenda C, Picó A.** Immunohistochemical analysis of tumor
698 angiogenic factors in human pituitary adenomas. *Human Pathology* 2005;36(10):1090–1095.
- 699 104. **Ilie MD, Lasolle H, Raverot G.** Emerging and Novel Treatments for Pituitary Tumors. *Journal of*
700 *Clinical Medicine* 2019;8(8):1107:1–17.
- 701 105. **Dai C, Liang S, Sun B, Li Y, Kang J.** Anti-VEGF Therapy in Refractory Pituitary Adenomas and
702 Pituitary Carcinomas: A Review. *Frontiers in Oncology* 2021. doi:10.3389/fonc.2021.773905.

- 703 106. **Osterhage K, Rotermund R, Droste M, Dierlamm J, Saeger W, Petersenn S, Aberle J, Flitsch J.**
704 Bevacizumab in Aggressive Pituitary Adenomas – Experience with 3 Patients. *Exp Clin Endocrinol*
705 *Diabetes* 2021;129(03):178–185.
- 706 107. **Wang Y, He Q, Meng X, Zhou S, Zhu Y, Xu J, Tao R.** Apatinib (YN968D1) and Temozolomide in
707 Recurrent Invasive Pituitary Adenoma: Case Report and Literature Review. *World Neurosurgery*
708 2019;124:319–322.
- 709 108. **Alshaikh OM, Asa SL, Mete O, Ezzat S.** An Institutional Experience of Tumor Progression to
710 Pituitary Carcinoma in a 15-Year Cohort of 1055 Consecutive Pituitary Neuroendocrine Tumors.
711 *Endocrine Pathology* 2019;30(2):118–127.
- 712 109. **Ortiz LD, Syro LV, Scheithauer BW, Ersen A, Uribe H, Fadul CE, Rotondo F, Horvath E, Kovacs K.**
713 Anti-VEGF therapy in pituitary carcinoma. *Pituitary* 2012;15(3):445–449.
- 714 110. **O’Riordan LM, Grealley M, Coleman N, Breathnach OS, Hennessy B, Thompson CJ, Grogan W.**
715 Metastatic ACTH-producing pituitary carcinoma managed with combination pasireotide and
716 bevacizumab following failure of temozolamide therapy: A case report. *Journal of Clinical Oncology*
717 2013;31(15_suppl):e13022–e13022.
- 718 111. **Dutta P, Reddy KS, Rai A, Madugundu AK, Solanki HS, Bhansali A, Radotra BD, Kumar N, Collier**
719 **D, Iacovazzo D, Gupta P, Raja R, Gowda H, Pandey A, Devgun JS, Korbonits M.** Surgery, Octreotide,
720 Temozolomide, Bevacizumab, Radiotherapy, and Pegvisomant Treatment of an AIP Mutation–Positive
721 Child. *The Journal of Clinical Endocrinology & Metabolism* 2019;104(8):3539–3544.
- 722 112. **Xu L, Khaddour K, Chen J, Rich KM, Perrin RJ, Campian JL.** Pituitary carcinoma: Two case reports
723 and review of literature. *World Journal of Clinical Oncology* 2020;11(2):91–102.
- 724 113. **McCormack A, Dekkers OM, Petersenn S, Popovic V, Trouillas J, Raverot G, Burman P.**
725 Treatment of aggressive pituitary tumours and carcinomas: results of a European Society of
726 Endocrinology (ESE) survey 2016. *European Journal of Endocrinology* 2018;178(3):265–276.
- 727 114. **Chakroborty D, Sarkar C, Yu H, Wang J, Liu Z, Dasgupta PS, Basu S.** Dopamine stabilizes tumor
728 blood vessels by up-regulating angiopoietin 1 expression in pericytes and Kruppel-like factor-2
729 expression in tumor endothelial cells. *Proceedings of the National Academy of Sciences*
730 2011;108(51):20730–20735.
- 731 115. **Sarkar C, Chakroborty D, Dasgupta PS, Basu S.** Dopamine is a safe antiangiogenic drug which
732 can also prevent 5-fluorouracil induced neutropenia: DA a Safe Antiangiogenic Drug. *International*
733 *Journal of Cancer* 2015;137(3):744–749.
- 734 116. **Chauvet N, Romanò N, Lafont C, Guillou A, Galibert E, Bonnefont X, Le Tissier P, Fedele M,**
735 **Fusco A, Mollard P, Coutry N.** Complementary actions of dopamine D2 receptor agonist and anti-vegf
736 therapy on tumoral vessel normalization in a transgenic mouse model: Tumoral vessel normalization by
737 dopamine and Vegf blockade. *International Journal of Cancer* 2017;140(9):2150–2161.
- 738 117. **Peterson TE, Kirkpatrick ND, Huang Y, Farrar CT, Marijt KA, Kloepper J, Datta M, Amoozgar Z,**
739 **Seano G, Jung K, Kamoun WS, Vardam T, Snuderl M, Goveia J, Chatterjee S, Batista A, Muzikansky A,**
740 **Leow CC, Xu L, Batchelor TT, Duda DG, Fukumura D, Jain RK.** Dual inhibition of Ang-2 and VEGF

741 receptors normalizes tumor vasculature and prolongs survival in glioblastoma by altering macrophages.
742 *Proceedings of the National Academy of Sciences* 2016;113(16):4470–4475.

743 118. **Hashizume H, Falcon BL, Kuroda T, Baluk P, Coxon A, Yu D, Bready JV, Oliner JD, McDonald**
744 **DM.** Complementary Actions of Inhibitors of Angiopoietin-2 and VEGF on Tumor Angiogenesis and
745 Growth. *Cancer Research* 2010;70(6):2213–2223.

746 119. **Burgos-Panadero R, Lucantoni F, Gamero-Sandemetrio E, Cruz-Merino L de la, Álvaro T,**
747 **Noguera R.** The tumour microenvironment as an integrated framework to understand cancer biology.
748 *Cancer Letters* 2019;461:112–122.

749 120. **Paez-Pereda M, Kuchenbauer F, Arzt E, Stalla GK.** Regulation of pituitary hormones and cell
750 proliferation by components of the extracellular matrix. *Brazilian Journal of Medical and Biological*
751 *Research* 2005;38(10):1487–1494.

752 121. **Theocharis AD, Skandalis SS, Gialeli C, Karamanos NK.** Extracellular matrix structure. *Advanced*
753 *Drug Delivery Reviews* 2016;97:4–27.

754 122. **Yue B.** Biology of the Extracellular Matrix: An Overview. *Journal of Glaucoma* 2014;23:S20–S23.

755 123. **Evans JJ, Chitcholtan K.** Extracellular Matrix Proteins in the Anterior Pituitary Gland. *The Open*
756 *Neuroendocrinology Journal* 2011;4(1):111–119.

757 124. **Farnoud MR, Lissak B, Kujas M, Peillon F, Racadot J, Li JY.** Specific alterations of the basement
758 membrane and stroma antigens in Human pituitary tumours in comparison with the normal anterior
759 pituitary. An immunocytochemical study. *Virchows Archiv A Pathological Anatomy and Histopathology*
760 1992;421(6):449–455.

761 125. **Farnoud MR, Veirana N, Derome P, Peillon F, Li JY.** Adenomatous transformation of the human
762 anterior pituitary is associated with alterations in integrin expression. *International Journal of Cancer*
763 1996;67(1):45–53.

764 126. **Tofrizal A, Fujiwara K, Azuma M, Kikuchi M, Jindatip D, Yashiro T, Yamada S.** Tissue inhibitors
765 of metalloproteinase-expressing cells in human anterior pituitary and pituitary adenoma. *Medical*
766 *Molecular Morphology* 2017;50(3):145–154.

767 127. **Quintero-Fabián S, Arreola R, Becerril-Villanueva E, Torres-Romero JC, Arana-Argáez V, Lara-**
768 **Riegos J, Ramírez-Camacho MA, Alvarez-Sánchez ME.** Role of Matrix Metalloproteinases in
769 Angiogenesis and Cancer. *Front Oncol* 2019;9:1370.

770 128. **Su S-C, Lin C-W, Yang W-E, Fan W-L, Yang S-F.** The urokinase-type plasminogen activator (uPA)
771 system as a biomarker and therapeutic target in human malignancies. *Expert Opinion on Therapeutic*
772 *Targets* 2016;20(5):551–566.

773 129. **Cathcart J, Pulkoski-Gross A, Cao J.** Targeting Matrix Metalloproteinases in Cancer: Bringing
774 New Life to Old Ideas. *Genes Dis* 2015;2(1):26–34.

775 130. **Yao Q, Kou L, Tu Y, Zhu L.** MMP-Responsive “Smart” Drug Delivery and Tumor Targeting. *Trends*
776 *Pharmacol Sci* 2018;39(8):766–781.

777 131. **Slack RJ, Macdonald SJF, Roper JA, Jenkins RG, Hatley RJD.** Emerging therapeutic opportunities
778 for integrin inhibitors. *Nat Rev Drug Discov* 2022;21(1):60–78.

779 132. **Bergonzini C, Kroese K, Zweemer AJM, Danen EHJ.** Targeting Integrins for Cancer Therapy -
780 Disappointments and Opportunities. *Front. Cell Dev. Biol.* 2022;10:863850.

781

782

783

784

785

786

787

788

789

790

791

792 **Figure legends**

793 **Figure 1.** Immunohistochemical stainings depicting T cells (CD3+), macrophages (CD68+), blood vessels
794 (CD34+), and folliculostellate cells (S100B+) in four different histological subtypes of pituitary adenomas.
795 Original magnification ×200.

796
797 **Figure 2.** Roles and interactions of tumor-associated macrophages (TAMs) in pituitary adenomas. Derived
798 from data from (12,14,15,18,19,21,29,37,55). Dashed arrows indicate that only associations or correlations
799 (i.e., no causality, nor any mechanism demonstrated) are available so far. Question marks indicate that
800 additional, currently unknown, mechanisms might be also responsible. *In rat estrogen-induced
801 prolactinoma. Figure created using illustrations from *Servier Medical Art* (<https://smart.servier.com/>).
802 Abbreviations: associated with (as.), correlated with (cor.), matrix metalloproteinase (MMP), S100
803 calcium-binding protein A9 (S100A9), epithelial-to-mesenchymal transition (EMT), enhancer of zeste
804 homolog 2 (EZH2), growth factors (GFs), C-C motif chemokine ligand (CCL), colony stimulating factor 1
805 (CSF1), granulocyte-macrophage colony-stimulating factor (GM-CSF), cluster of differentiation (CD),
806 human leukocyte antigen – DR isotype (HLA-DR), vascular endothelial growth factor (VEGF), VEGF-
807 receptor (VEGFR).

808
809 **Figure 3.** Schematic representation of the mechanism of action of immune-checkpoint inhibitors (**A**), and
810 of anti-VEGF-A and anti-VEGFRs therapies (**B**) used in pituitary carcinomas and aggressive pituitary
811 adenomas. Immune-checkpoint inhibitors are monoclonal antibodies that block either CTLA-4
812 (ipilimumab) or PD-1 (nivolumab and pembrolizumab), that are found on T cells, or PD-L1, the ligand of
813 PD-1, which is found on antigen-presenting cells and on tumor cells. Bevacizumab is a monoclonal
814 antibody that blocks VEGF-A. Sunitinib and apatinib are tyrosine kinase inhibitors that target VEGFR1
815 and VEGFR2 (amongst other targets) for sunitinib, and VEGFR2 for apatinib. Figure produced using
816 illustrations from *Servier Medical Art* (<https://smart.servier.com/>). *Not used so far in pituitary carcinomas
817 and aggressive pituitary adenomas. Abbreviations: programmed cell death protein 1 (PD-1), programmed

818 death-ligand 1 (PD-L1), cytotoxic T-lymphocyte-associated protein 4 (CTLA-4), vascular endothelial
819 growth factor A (VEGF-A), VEGF-receptor (VEGFR).

820

821 **Figure 4.** Radiological response of pituitary carcinomas and aggressive pituitary adenomas treated with
822 therapies targeting the tumor microenvironment. Derived from data from (3,65,104,105). Abbreviation:
823 non-immunoreactive (NIR), immune-checkpoint inhibitors (ICIs).

824

825

826

827

828

829

830

831

832

833

834

835

836

837

838

839

840

841

842

843

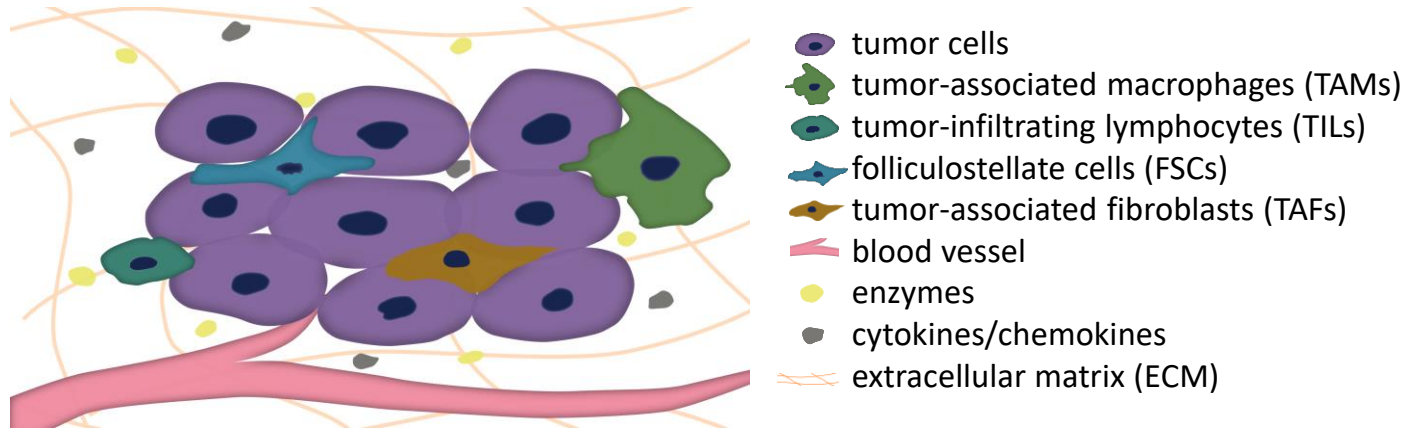
844 **Table 1.** Potential impact of tumor microenvironment on aggressiveness-related characteristics of pituitary adenomas and carcinomas. Derived from data from (4,9–15,18–51).

	Invasion (Patients)	Proliferation (Patients)	Progression/Recurrence/Resistance to treatment (Patients)	<i>In vivo/in vitro</i>
Somatotroph	F: CS inv. as. with less CD8+ cells (19) & more CD68+ TAMs (14)	F: Higher Ki-67 index in PAs with high VEGF expression vs. PAs with no VEGF expression (20)	F: Resistance to first-generation SRLs as. with less CD8+ cells (19)	<p>Macrophage-conditioned media induced morphology changes, EMT activation & increased inv. of GH3 cells (12,15)</p> <p>CCL17 promoted increased EMT changes, migration, inv. & pf. of GH3 cells (21)</p> <p>Angiopoietin-2 promoted the pf. of GH3 cells (22)</p> <p>TAFs derived from PAs with CS inv. promoted pf. of GH3 cells <i>in vitro</i>, as well as the growth of GH3-derived xenografts in mice (23)</p> <p>TAF-conditioned medium induced morphology changes, EMT activation, & increased inv. & migration of GH3 cells (24)</p>
Lactotroph	<p>F: Inv. macroprolactinomas as. with higher microvessel density than non-inv. macroprolactinomas (28)</p> <p>F: Inv. macroprolactinomas expressed more MMP-9 than non-inv. macroprolactinomas (29)</p>		F: Resistance to bromocriptine as. with higher endothelial expression of endocan (30)	<p>Laminin inhibited GH3 cell pf. (25)</p> <p>Different collagen subtypes impacted differently GH3 cell inv. & migration strategy (26)</p> <p>MMP inhibition decreased GH3 cell pf. (27)</p> <p>IL-2, IL-6, BMP-4 & CXCL12 stimulated, while TGF-β inhibited GH3 cell pf. (4)</p> <p>CXCL12 stimulated, while TGF-β inhibited GH4 cell pf. (4)</p>
Corticotroph	F: CS inv. as. with lower tPA expression (31)			<p>Collagen IV, fibronectin & activation of β1 integrin stimulated, while collagen I & laminin inhibited AtT-20 cell pf. (32)</p> <p>TIMP-1 inhibited AtT-20 cell inv. & migration (33)</p> <p>MMP inhibition decreased AtT-20 cell pf. (27)</p> <p>RSUME silencing inhibited inv. of AtT-20 cells (34)</p> <p>IL-1 & IL-2 stimulated, while IFN-γ & LIF inhibited AtT-20 cell pf. (4)</p>
Gonadotroph	CS inv. as. with more CD68+ & CD163+ TAMs, & less thick & thin collagen fibers (14)	Ki67 index \geq 3%, mitosis > 2/10 HPFs & proliferative status as. with fewer S100B+ cells (35)	<p>Progression after surgery as. with higher <i>VEGF</i> expression (36)</p> <p>Less progression-free time as. with higher <i>VEGFR2</i> expression (36)</p>	

Unspecified or combined NFPA	<p>CS inv. as. with more CD163+ TAMs (9), M2-like/M1-like TAMs ratio >1 (37) & higher FoxP3/CD8 ratio (9)</p> <p>CS inv. as. with more VEGF & VEGFR1 (9)</p> <p>Inv. of hormone-negative PAs as. with high endothelial expression of endocan (38)</p>	<p>Higher MMP-9 expression in recurrent NFPA (for the second surgery compared to the first) (29)</p>	<p>Cultured M2 versus M1 macrophages promoted increased inv., motility & pf. of primary NFPA cultures (37)</p>
Combined histological subtypes	<p>Knosp grades cor. with CD68+ TAMs number (10), endocan expression relative to CD34 expression (39) & tumor cell expression of endocan (40)</p> <p>CS inv. as. with high infiltration of M2-like TAMs, higher expression of lactate-related genes, more CCL17 & high CCL17 expression (21), lower <i>VEGI</i> levels (41), higher MMP-2, -9 (42) & MMP-14 expression (33), & lower TIMP-2 expression (31)</p> <p>Inv. as. with more VEGF, HIF-1α, RSUME (34), higher MMP-9 expression (43,46) & serum levels (43), lower TIMP-1 expression & serum levels (43), higher CXCL12 & CXCR4 expression, more CXCL12-positive & CXCR4-positive cells (44), higher IL-6 & TNF-α expression (45), higher IL-17 expression & serum levels (46), higher IL-17 receptor expression (46), & positively cor. with β1 integrin & FAK expression (47)</p>	<p>Ki67 index \geq3% as. with more FoxP3+ cells, lower CD8/FoxP3, CD68/FoxP3 & CD8/CD4 ratios, & a “deleterious immune phenotype” (CD68^{hi}CD4^{hi}FOXP3^{hi}CD20^{hi}) (15), as well as as. with fewer S100B+ cells (35)</p> <p>Ki67 index >3% as. with increased expression in CD45+ cells (13)</p> <p>Higher mitotic count & p53 expression as. with endothelial expression of endocan (48)</p>	<p>Persistence/recurrence after surgery as. with the presence of CD45+ cells (11)</p> <p>Recurrent PAs had higher CD45+ & lower CD163+ infiltrates than primary PAs (18)</p> <p>Recurrence/progression after surgery as. with high CCL17 expression (21) & endothelial expression of endocan (48)</p> <p>Carcinomas as. with increased vascularization compared to PAs (49,50)</p> <p>No recurrence/regrowth positively cor. with VEGF expression (51)</p> <p>Lower post-operative survival rate as. with higher MMP-9 & lower TIMP-1 expression (43)</p>

845 Abbreviations: non-functioning pituitary adenoma (NFPA), functioning (F), cavernous sinus (CS), invasion (inv.), was associated (as.), tumor-associated macrophages
846 (TAMs), matrix metalloproteinase (MMP), tissue-type plasminogen activator (tPA), vascular endothelial growth factor (VEGF), VEGF-receptor (VEGFR), pituitary
847 adenoma (PA), correlated (cor.), C-C motif chemokine ligand (CCL), endothelial growth inhibitor (VEGI), hypoxia-inducible factor-1 α (HIF-1 α), RWD-containing
848 sumoylation enhancer (RSUME), C-X-C motif chemokine (CXCL), C-X-C chemokine receptor (CXCR), interleukin (IL), tumor necrosis factor- α (TNF- α), vascular
849 somatostatin receptor ligands (SRLs), tissue inhibitors of metalloproteinases (TIMP), focal adhesion kinase (FAK), proliferation (pf.), epithelial-to-mesenchymal transition
850 (EMT), tumor-associated fibroblast (TAF), bone morphogenetic protein (BMP), transforming growth factor- β (TGF- β), interferon- γ (IFN- γ), leukaemia inhibitory factor
851 (LIF).

Tumor Microenvironment Implications in Pituitary Adenomas



Biological → linked to pituitary adenoma:

- Functionality
- Size
- Invasion
- Proliferation
- Progression/recurrence
- Treatment response

Therapeutic → targeting of:

- The immune infiltrate: immune-checkpoint inhibitors, TAM-targeting
- Angiogenesis: bevacizumab, tyrosine kinase inhibitors, vascular normalization
- TAFs & FSCs
- The ECM & its remodeling

Figure 1

[Click here to access/download;Figure;llie_fig1.pdf](#)

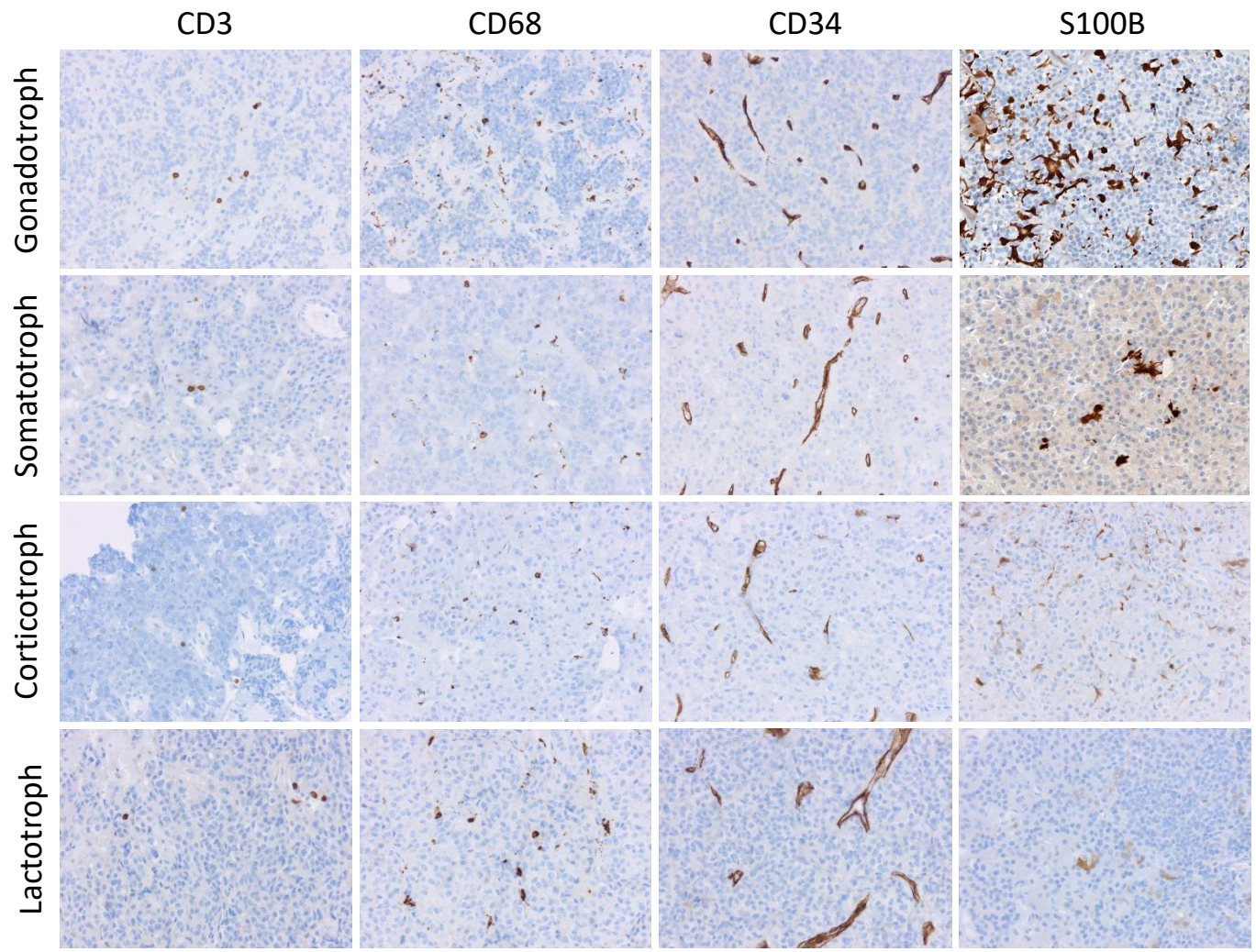


Figure 2

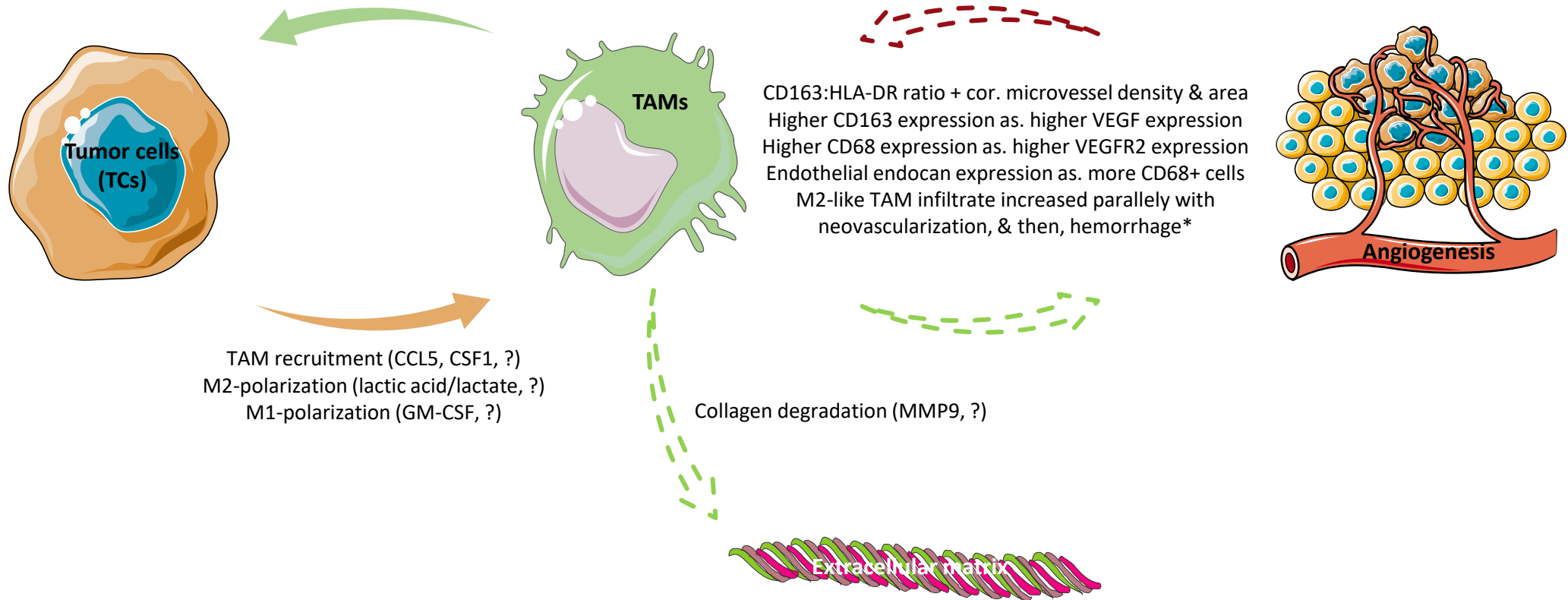
Increase TC invasion (CCL17, upregulation of *MMP9* & *S100A9* in TCs, ?)

Increase TC motility/migration (CCL17, upregulation of *S100A9* in TCs, ?)

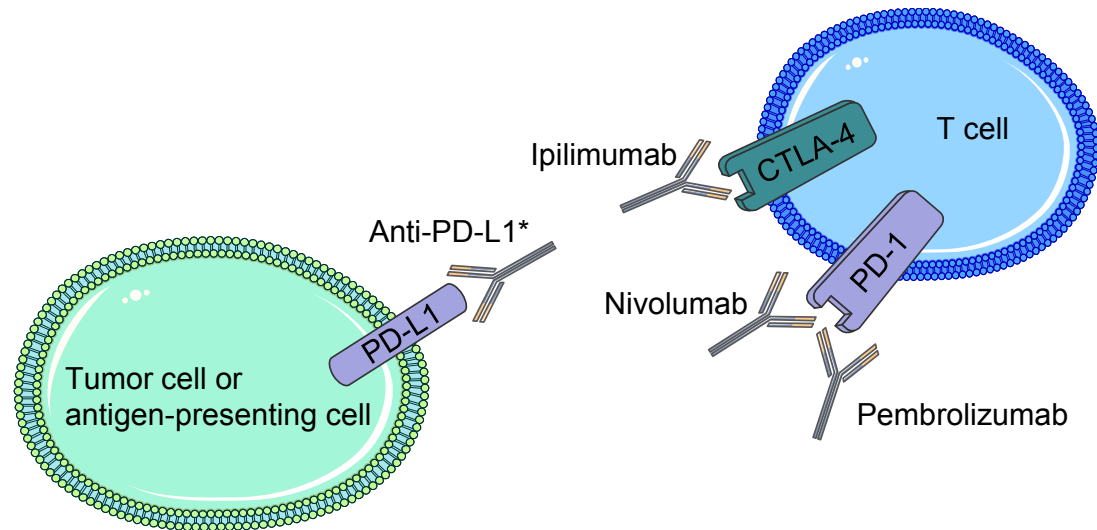
Induce TC EMT activation (CCL17, ?)

Increase TC proliferation (CCL17, upregulation of *EZH2* in TCs, ?)

Increase secretion of cytokines/chemokines/GFs by TCs



A. Immune-checkpoint inhibitors



B. Anti-VEGF-A and anti-VEGFRs therapies

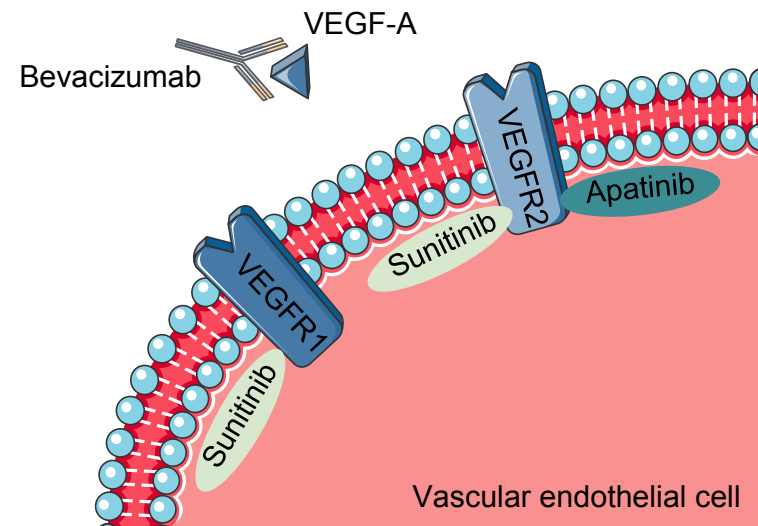
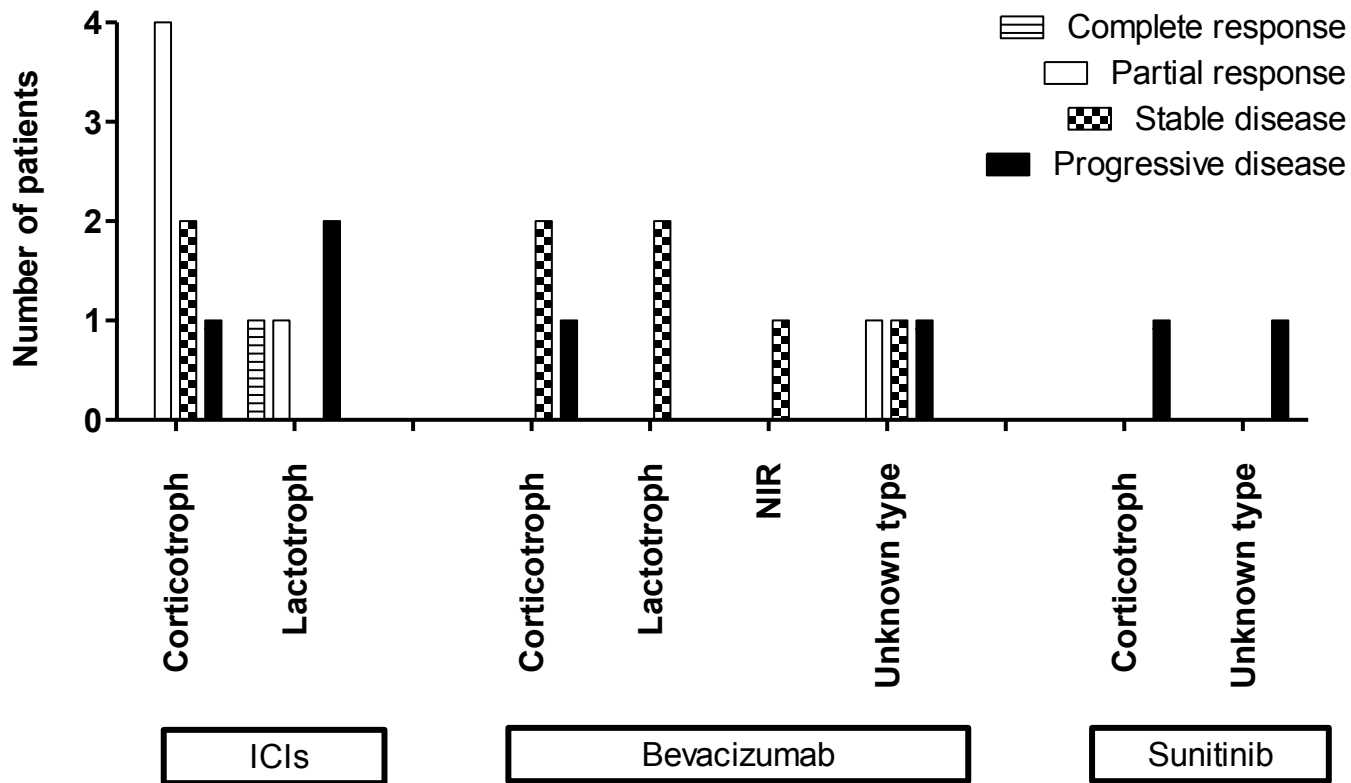


Figure 4 [Click here to access/download:Figure:llie_fig4.pdf](#)
Radiological response of pituitary carcinomas and aggressive pituitary adenomas treated with tumor microenvironment-directed therapies



Essential points

- Tumor-associated macrophages are the most abundant immune cell in pituitary adenomas, and have been linked to the size, invasion, and proliferation of pituitary adenomas – most notably to their invasion.
- Tumor-infiltrating lymphocytes have been linked to invasion and proliferation of pituitary adenomas, and to the response to treatment of somatotroph adenomas.
- Folliculostellate cells have been linked to hormone production/secretion and to the proliferation of pituitary adenomas.
- Angiogenesis and angiogenesis-related molecules have been linked to invasion, proliferation, and the progression/recurrence of pituitary adenomas, as well as to response to treatment in lactotroph adenomas.
- The extracellular matrix and its remodeling have been linked to hormone production/secretion, to the invasion and proliferation of pituitary adenomas – most notably to their invasion.
- Substantial crosstalk takes place between adenoma cells and the tumor microenvironment, as well as between the different components of the tumor microenvironment.
- Immune-checkpoint inhibitors and bevacizumab have already shown some efficacy in treating aggressive pituitary adenomas and pituitary carcinomas.