



**HAL**  
open science

# Immune-Mediated Rippling Muscle Disease Associated With Thymoma and Anti-MURC/Cavin-4 Autoantibodies

Juliette Svahn, Laurent Coudert, Nathalie Streichenberger, Alexandra Kraut, Alice Gravier-Dumonceau-Mazelier, Ludivine Rotard, Laurence Calemard-Michel, Rita Menassa, Elisabeth Errazuriz-Cerda, Lara Chalabreysse, et al.

► **To cite this version:**

Juliette Svahn, Laurent Coudert, Nathalie Streichenberger, Alexandra Kraut, Alice Gravier-Dumonceau-Mazelier, et al.. Immune-Mediated Rippling Muscle Disease Associated With Thymoma and Anti-MURC/Cavin-4 Autoantibodies. *Neurology Neuroimmunology & Neuroinflammation*, 2023, 10 (1), pp.e200068. 10.1212/NXI.0000000000200068 . hal-04293370

**HAL Id: hal-04293370**

**<https://cnrs.hal.science/hal-04293370>**

Submitted on 23 Nov 2023

**HAL** is a multi-disciplinary open access archive for the deposit and dissemination of scientific research documents, whether they are published or not. The documents may come from teaching and research institutions in France or abroad, or from public or private research centers.

L'archive ouverte pluridisciplinaire **HAL**, est destinée au dépôt et à la diffusion de documents scientifiques de niveau recherche, publiés ou non, émanant des établissements d'enseignement et de recherche français ou étrangers, des laboratoires publics ou privés.

# Immune-Mediated Rippling Muscle Disease Associated With Thymoma and Anti-MURC/Cavin-4 Autoantibodies

Juliette Svahn, MD, Laurent Coudert, PhD, Nathalie Streichenberger, MD, Alexandra Kraut, MS, Alice Gravier-Dumonceanu-Mazelier, MD, Ludivine Rotard, MS, Laurence Caemard-Michel, MD, Rita Menassa, MD, Elisabeth Errazuriz-Cerda, MS, Lara Chalabreysse, MD, Alexis Osseni, PhD, Christophe Vial, MD, Laurentiu Jomir, MD, François Tronc, MD, Do Le Duy, PhD, Emilien Bernard, MD, Vincent Gache, PhD, Yohann Couté, PhD, Vincent Jacquemond, PhD, Laurent Schaeffer, PhD, and Pascal Leblanc, PhD

**Correspondence**

Dr. Leblanc  
pascal.leblanc@univ-lyon1.fr

*Neurol Neuroimmunol Neuroinflamm* 2023;10:e200068. doi:10.1212/NXI.000000000200068

## Abstract

### Objectives

Rippling muscle disease (RMD) is characterized by muscle stiffness, muscle hypertrophy, and rippling muscle induced by stretching or percussion. Hereditary RMD is due to sequence variants in the *CAV3* and *PTRF/CAVIN1* genes encoding Caveolin-3 or Cavin-1, respectively; a few series of patients with acquired autoimmune forms of RMD (iRMD) associated with AChR antibody-positive myasthenia gravis and/or thymoma have also been described. Recently, MURC/caveolae-associated protein 4 (Cavin-4) autoantibody was identified in 8 of 10 patients without thymoma, highlighting its potential both as a biomarker and as a triggering agent of this pathology. Here, we report the case of a patient with iRMD-AChR antibody negative associated with thymoma.

### Methods

We suspected a paraneoplastic origin and investigated the presence of specific autoantibodies targeting muscle antigens through a combination of Western blotting and affinity purification coupled with mass spectrometry-based proteomic approaches.

### Results

We identified circulating MURC/Cavin-4 autoantibodies and found strong similarities between histologic features of the patient's muscle and those commonly reported in caveolinopathies. Strikingly, MURC/Cavin-4 autoantibody titer strongly decreased after tumor resection and immunotherapy correlating with complete disappearance of the rippling phenotype and full patient remission.

### Discussion

MURC/Cavin-4 autoantibodies may play a pathogenic role in paraneoplastic iRMD associated with thymoma.

**MORE ONLINE****Videos**

From the Electroneuromyography and Neuromuscular Department (J.S., A.G.-D.-M., C.V., L.J., E.B.), Pierre Wertheimer Hospital, Hospices Civils de Lyon; Institut NeuroMyoGène Physiopathologie et Génétique du neurone et du muscle (INMG-PGNM) (J.S., Laurent Coudert, N.S., L.R., L.C.-M., R.M., A.O., E.B., V.G., V.J., L.S., P.L.), CNRS UMR5261, INSERM U1315, Faculté de Médecine Rockefeller, Université Claude Bernard Lyon, Cedex; Department of Neuropathology (N.S., Lara Chalabreysse), Hospices Civils de Lyon; Univ. Grenoble Alpes (A.K., Y.C.), INSERM, CEA, UMR BioSanté U1292, CNRS, CEA; Department of Molecular Endocrinology and Rare Diseases (L.C.-M., R.M.), Hospices Civils de Lyon; Centre d'imagerie quantitative Lyon Est (CIQLE) (E.E.-C.), Department of Thoracic Surgery (F.T.), Hospices Civils de Lyon; Institut NeuroMyoGène INMG-MeLIS (D.L.D.), CNRS UMR5284, INSERM U1314, SynatAc Team, Faculté de Médecine Rockefeller, Universités de Lyon, Université Claude Bernard Lyon 1; and French Reference Center on Paraneoplastic Neurological Syndromes and Autoimmune Encephalitis (D.L.D.), Hospices Civils de Lyon, France.

Go to [Neurology.org/NN](https://www.neurology.org/NN) for full disclosures. Funding information is provided at the end of the article.

The Article Processing Charge was funded by CNRS UMR5261.

See the Highlighted Changes supplement, showing the changes made in this updated version: <http://links.lww.com/NXI/A811>

This is an open access article distributed under the terms of the Creative Commons Attribution-NonCommercial-NoDerivatives License 4.0 (CC BY-NC-ND), which permits downloading and sharing the work provided it is properly cited. The work cannot be changed in any way or used commercially without permission from the journal.

Hereditary rippling muscle disease (hRMD) is due to sequence variations in the *CAV3* and *PTRF/CAVIN1* genes encoding Caveolin-3 and Cavin-1 proteins, respectively.<sup>1,2</sup> A few series of patients with acquired autoimmune forms of RMD (iRMD) associated with AChR antibody-positive myasthenia gravis (MG) and/or thymoma have also been described.<sup>3,4</sup> Until 2022, the precise target for autoimmunity in iRMD was still unknown.<sup>4,7</sup> More recently, MURC/Cavin-4 autoantibodies were identified in 8 of 10 patients with iRMD without thymoma, thus suggesting that it could be considered potential biomarkers and triggering agents of this pathology.<sup>8</sup> Of interest, MURC/Cavin-4 was found to play a major role in early T-tubule remodeling by recycling caveolar components from the T-tubule to the sarcolemma<sup>9</sup> and then participates to the stabilization of this key macromolecular complex involved in the muscle excitation-contraction coupling system.<sup>9</sup> Here, we report the presence of MURC/Cavin-4 antibodies in a patient presenting iRMD associated with thymoma.

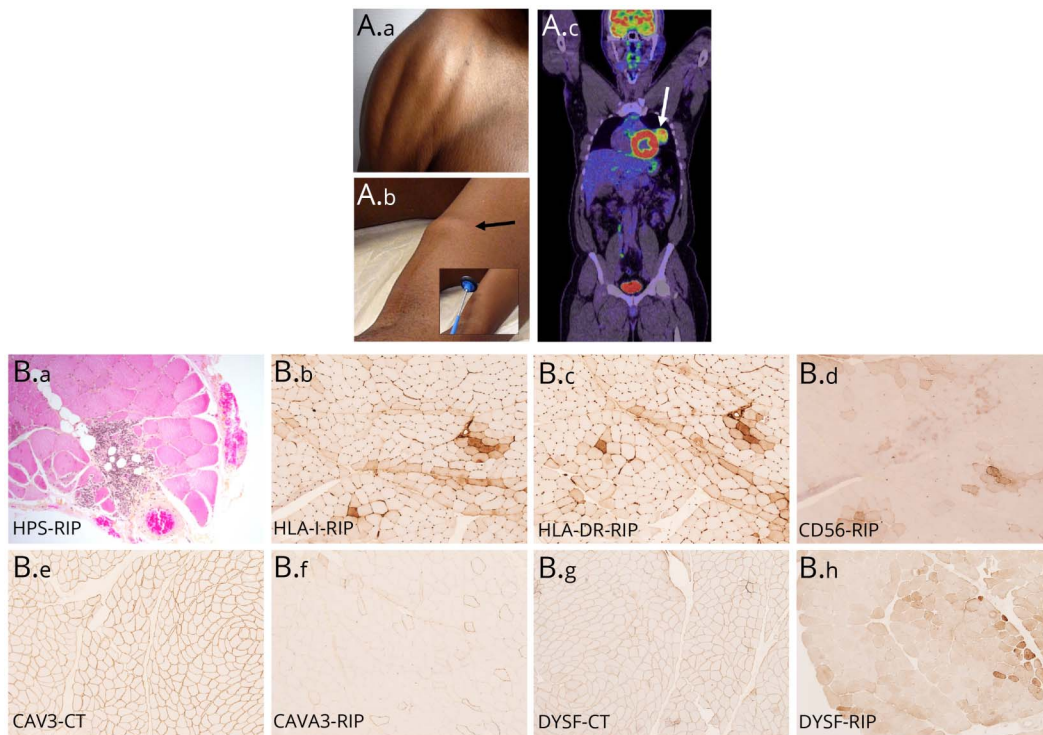
## Case Report

A 40-year-old man presented in February 2018 with myalgias and rippling waves of muscle contraction in the pectoralis

major and deltoid muscles (Figure 1A; Videos 1 and 2). Surface EMG (EMG) showed electrical silence during muscle rippling. Needle EMG studies revealed fibrillation potentials and pseudomyotonic discharges in deltoid muscles. The serum creatine kinase (CK) level was increased at 1,890 IU/L (normal value <200 IU/L). Anti-Titin antibodies were positive without anti-Lgi1, anti-Caspr2, anti-AChR, anti-MuSK, and anti-myositis-specific or -associated antibodies. Molecular investigations revealed no mutation in the *CAV3* and *PTRF/CAVIN1* genes. Whole-body fluorodeoxyglucose-PET showed a hypermetabolic mediastinal left paracardiac tumor in contact with the lower part of the thymus (Figure 1A.c).

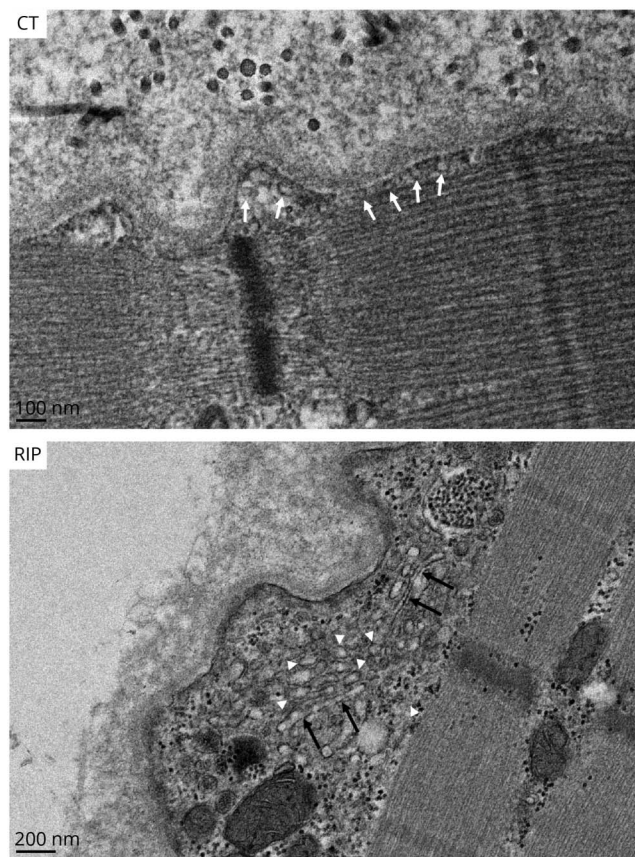
Hematoxylin-phloxine-saffron staining performed on the patient's deltoid muscle biopsy revealed rare perifascicular and endomysial necrotic fibers associated with few pericapillary perimysial and endomysial inflammatory infiltrates (Figure 1B.a). The inflammatory infiltrates were composed mostly of CD20-positive B cells, few T cells (more CD4 than CD8-positive cells), and CD68-positive macrophages. Immunohistochemistry (IHC) investigations identified peri- and intrafascicular HLA-I and HLA-DR upregulated expression associated with positive CD56-regenerating fibers (Figure 1B.b–B.d). Complementary IHC on

**Figure 1** Rippling Patient (RIP) Clinical, Radiologic Features and Deltoid Muscle Biopsy vs Control (CT)



Rippling (A.a) Voluntary contraction and active stretching induced rippling phenomenon, which traversed the pectoralis major and deltoid muscles in a wave-like manner. (A.b) Quick and firm percussion of biceps muscle induced muscle mounding (see black arrow). (A.c) Whole-body fluorodeoxyglucose-PET showed a hypermetabolic mediastinal left paracardiac tumor (white arrow) in contact with the lower part of the thymus. (B) Hematoxylin-phloxine-saffron (HPS) staining and immunohistochemistry analyses. (B.a) HPS analysis revealed peri- and endomysial inflammatory infiltrates in the Rippling (RIP) muscle patient. (B.b) Increased expression of peri- and intrafascicular HLA-I in the RIP muscle patient. (B.c) Upregulated expression of peri- and intrafascicular HLA-DR in the RIP muscle patient. (B.d) Increased expression of peri- and intrafascicular CD56 in the RIP muscle patient. (B.e) Caveolin-3 expression in control (CT) muscle. (B.f) Caveolin-3 expression in the RIP muscle patient. Note the strong decrease of Caveolin-3 staining in RIP patient muscle. (B.g) Dysferlin expression in control (CT) muscle. (B.h) Dysferlin expression in RIP patient muscle. Note the strong decrease of staining and distribution perturbation of dysferlin in RIP patient muscle. Magnification  $\times 100$ .

**Figure 2** Electron Microscopy Analyses of Control (CT) and Rippling Patient Skeletal Muscles



CT individual and RIP-thymoma associated rippling patient. Note the presence of caveolae structures in CT (white arrows), which are mainly absent from the RIP patient at the expense of vesicular and tubular structures that accumulate beneath the sarcolemma (white arrowheads and black arrows, respectively). Scale bars 100 and 200 nm, respectively.

frozen muscle sections did not reveal any positive signal for C3, C1q, IgG, -A, and -M, and free light chain kappa and lambda. The terminal membrane attack complex C5b-9 was observed as rare endomysial punctiform deposits without endomysial capillaries stainings (data not shown). Overall, this set of data appeared evocative of an overlap myositis pattern.<sup>10</sup> Of interest, a significant decreased sarcolemmal expression of Caveolin-3 was observed in a mosaic-like pattern associated with disturbed localization of its interacting partner dysferlin (Figure 1B.e–B.h).

Electron microscopy (EM) approaches revealed as well a reduction of caveolae formation at the sarcolemma level at the expense of an accumulation of vesicular and tubular structures beneath the sarcolemma (Figure 2) as commonly found in inherited caveolinopathies.<sup>1</sup> The patient underwent surgical resection of an encapsulated type B2 thymoma of the World Health Organization (WHO) classification and received steroids during 4 months with only partial improvement of his symptoms and persistently elevated CK level (593 IU/L). Azathioprine was then added with progressive disappearance of rippling phenomenon within few months. The serum CK level decreased at 291 IU/L.

We next investigated the presence in the patient serum (PS) of specific antibodies targeting skeletal muscle antigens by Western blotting on human myoblasts (MBs) and myotubes (MTs). A major 55-kDa immunoreactive band was detected with PS in MT extract (Figure 3A). Conversely, when probed with the posttreatment patient serum, a drastic signal decrease of the 55-kDa band was observed (Figure 3A), thus suggesting strong autoantibody titer reduction after tumor resection and immunotherapy. No signal was observed with healthy control serum (Figure 3, A and B). These data were confirmed by immunofluorescence microscopy (Figure 3B).

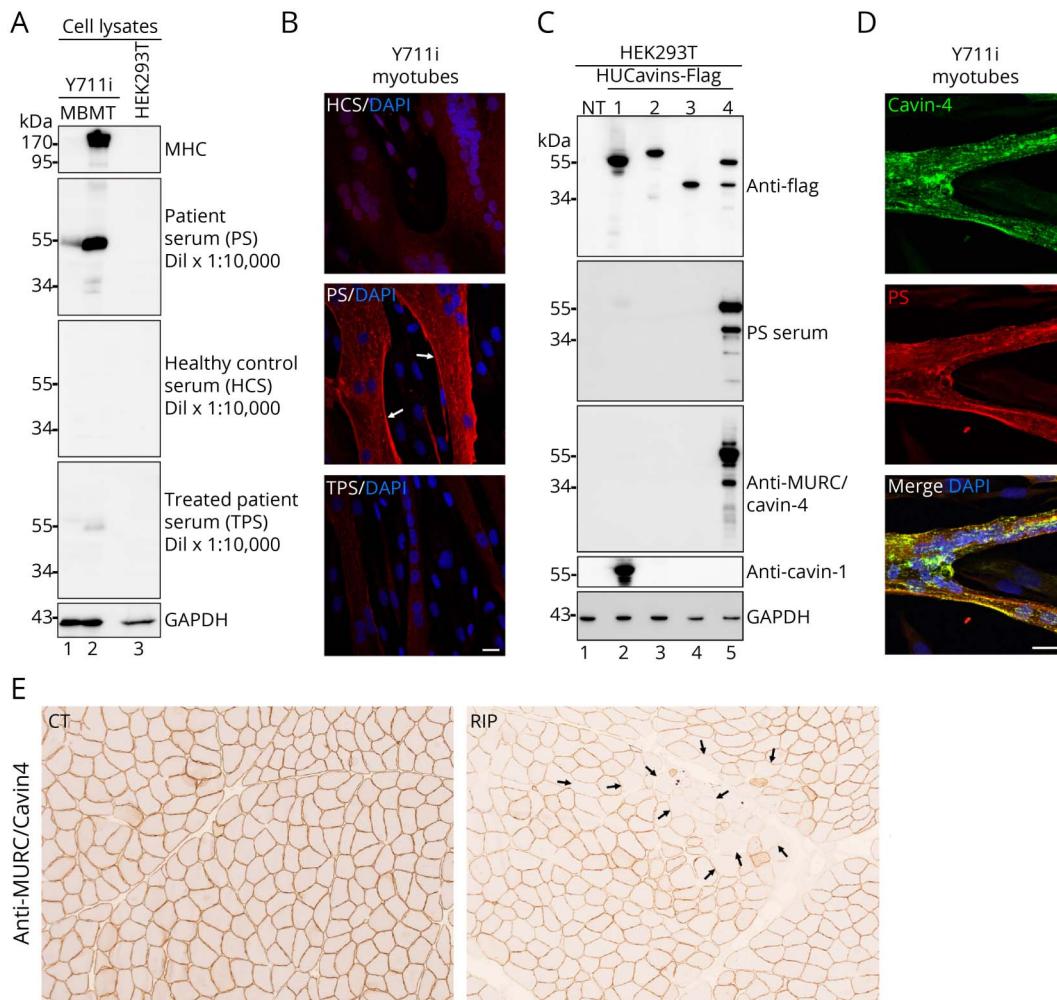
Immunoprecipitation-MS-based proteomic approaches on MTs using PS revealed that MURC/Cavin-4 and Cavin-1 were the most specifically enriched proteins (data not shown). We validated PS specificity for MURC/Cavin-4 by WB on HEK293T cells expressing Flag-tagged Cavin-1-4 (Figure 3C) and immunofluorescence colabeling in human MT using PS and commercial anti-MURC/Cavin-4 (Figure 3D). Isotype antibody determination was performed by WB using anti-IgG1, 2, 3, or 4 secondary antibodies. Anti-MURC/cavin-4 autoantibodies were recognized by anti-IgG1, 2, and 3 but not by anti-IgG4 (data not shown). IHC experiments performed on patient muscle biopsy using commercial anti-MURC/Cavin-4 antibody revealed a decrease of subsarcolemmal MURC/Cavin-4 staining in a mosaic-like pattern (Figure 3E), thus suggesting that MURC/Cavin-4 autoantibodies may induce antibody-mediated protein depletion.

To determine whether the thymoma itself could express MURC/Cavin-4 autoantigen that could lead to the induction of MURC/Cavin-4 autoantibodies by resident immune cells, the patient thymoma section was analyzed by IHC using a commercial anti-MURC/Cavin-4. We failed to detect MURC/Cavin-4 signal in the section through this approach, whereas a strong sarcolemmal signal was concomitantly observed in control healthy individual muscle tissue (eFigure 1A, [links.lww.com/NXI/A786](https://links.lww.com/NXI/A786)). Western blotting investigations performed on the non-iRMD B2 thymoma sample compared with the iRMD B2 thymoma and using the commercial anti-MURC/Cavin-4 confirmed the absence of the 55-kDa MURC/Cavin-4 band in both thymomas (eFigure 1, [links.lww.com/NXI/A786](https://links.lww.com/NXI/A786)). However, a faint MURC/Cavin-4 immunoreactive band around 43 kDa (see red arrow) was specifically detected in both iRMD thymoma and MT extracts but absent from the non-iRMD thymoma sample (eFigure 1B, [links.lww.com/NXI/A786](https://links.lww.com/NXI/A786)). This may suggest a possible weak expression of a MURC/Cavin-4 distinct isoform in the iRMD patient thymoma (see Discussion).

## Discussion

We identified circulating MURC/Cavin-4 autoantibody in a patient with iRMD associated with thymoma. This set of data complements the concomitant recent finding by Dubey et al.<sup>8</sup>

**Figure 3** iRMD Associated With Thymoma and MURC/Cavin-4 Autoantibodies



(A) Representative WB of myoblast (MB; lane 1) and myotube (MT; lane 2) protein extracts from the immortalized Y711i myoblast cell line or HEK293T cells (lane 3) and probed with anti-Myosin Heavy Chain (MHC) (marker of differentiated MT), patient serum (PS), healthy control serum (HCS) as negative control, patient serum after tumor ablation and immunotherapy (TPS for treated patient serum) and anti-glyceraldehyde-3-phosphate dehydrogenase (GAPDH) antibody as loading control. (B) Representative immunofluorescence of Y711i MT probed with HCS, PS, or TPS (red signal). Note the presence of a strong signal distributed near the sarcolemma when PS was used as a primary antibody (see white arrows). A drastic signal decrease was observed when MT extracts were probed with TPS. No specific signal was observed in MT when probed with HCS. The scale bar is 20  $\mu$ m. (C) WB validation of the 55 kDa as MURC/cavin-4 immunoreactive band. WB on untransfected HEK293T cells (NT) or transfected with human Flag-tagged Cavin-1, -2, -3, or -4 expressing constructs and probed with the anti-Flag antibody, PS, commercial anti-MURC/Cavin-4 and anti-Cavin-1 antibodies, or GAPDH antibodies as loading control. Note the specific detection of MURC/Cavin-4 by PS. (D) Representative immunofluorescence images of MT probed with the commercial anti-MURC/Cavin-4 antibody. Note the presence of a perfect yellow merge colocalization signal between commercial anti-MURC/Cavin-4 and PS. The scale bar is 10  $\mu$ m. (E) IHC of control individual (CT) and rippling patient (RIP) skeletal muscle sections probed with the commercial anti-MURC/Cavin-4. Note the decrease of MURC/Cavin-4 expression in a mosaic-like pattern in the thymoma rippling affected patient (see black arrows;  $\times 20$  magnification).

(2022) who isolated MURC/Cavin-4 autoantibodies in 8 of 10 patients with iRMD without thymoma. One prior MURC/Cavin-4 IgG+ case was reported with breast cancer a few months after symptom onset, with subsequent resolution of symptoms following cancer management and immunomodulatory therapies, supporting a potential paraneoplastic basis.<sup>8,11</sup> Of interest, MURC/Cavin-4 autoantibody titer of our patient strongly decreased after treatment correlating with complete remission. iRMD has also been reported as paraneoplastic syndrome related to thymoma (4 patients), mostly of B2 cortical type<sup>3,4</sup> and then presents similarities with AChR antibody-positive MG associated with thymoma.<sup>12</sup> In the latter, fully functional AChRs were not expressed in thymomas, but isolated

subunits were detected by immunolabeling or molecular methods.<sup>12</sup> At the present time, we could not eliminate ongoing autosensitization against MURC/Cavin-4 epitopes inside the thymoma primed by a non-posttranslationally modified isoform of MURC/Cavin-4 or eventually by an unrelated protein sharing epitope similarities.

Our study confirmed the isotype IgG1-3 subclass predominance in iRMD–Cavin-4 IgG+ patients. Additional evidence is needed to determine whether there is a role for antibody-dependent complement-mediated injury<sup>13</sup> in iRMD because a variable number of fibers in iRMD muscle biopsied exhibited upregulation of sarcolemmal HLA-I and C5b-9 deposition in non-

necrotic fibers.<sup>8</sup> Importantly, no C3 signals (required for the assembly phase in the classical or alternative pathway) or IgG deposits on muscle fibers were observed in our patient.

Of interest, anti-Titin antibodies were detected, similarly to 5 of 10 iRMD anti-MURC/Cavin-4–positive patients in the Dubey's study.<sup>8</sup> We cannot exclude, at this step, that both anti-MURC/Cavin-4 and anti-Titin association could act in a cumulative manner to disturb the normal muscle excitation-contraction coupling process.<sup>5,6</sup>

The mechanisms involved in these uncontrolled propagating wave-like muscle contractions are still nonelucidated. MURC/Cavin-4 plays a crucial role in the remodeling and the development of T-tubule membranes.<sup>9</sup> Loss of MURC/Cavin-4 caused aberrant accumulation of interconnected Caveolin-3–positive caveolae within the T-tubules and impaired Ca<sup>2+</sup> response on mechanical stimulation. Thus, the presence of MURC/Cavin-4 autoantibodies could potentially alter the T-tubule formation/maintenance by altering the Caveolin-3 expression and distribution. Accordingly, our EM analyses revealed alterations of caveolae formation beneath the sarcolemma as commonly visualized in inherited caveolinopathies.<sup>1</sup> To conclude, MURC/Cavin-4 autoantibodies may play a pathogenic role in paraneoplastic iRMD associated with thymoma.

## Standard Protocol Approvals, Registrations, and Patient Consents

The patient gave his written and informed consent for complementary research on his pre/posttreatment serum, muscle, and thymoma biopsies, associated with consent to disclose regarding pictures and videos. Human biological samples and associated data were obtained from Tissu-Tumorothèque Est and Centre de Biologie Cellulaire (CBC) Biotec Biobank (Centre de Ressources Biologiques Hospices Civils de Lyon NF S 96900 certification BB-0033-0046), a center for biological resources authorized by the French Ministry of Research (AC-2019-3465).

## Data Availability

Anonymized data not published within this article will be made available by request from any qualified investigator. The Methods section can be downloaded as supplemental eMethods, links.lww.com/NXI/A786.

## Acknowledgment

This work was supported by the CNRS and the INSERM, Equipe FRM, and AFM telethon funding through the strategic MyoNeurALP Alliance (L. Schaeffer and P. Leblanc).

## Study Funding

This work was funded by CNRS UMR5261 (P. Leblanc). The proteomic experiments (Y. Couté) were partially supported by Agence Nationale de la Recherche under projects ProFI (Proteomics French Infrastructure, ANR-10-INBS-08) and GRAL, a program from the Chemistry Biology Health (CBH) Graduate School of University Grenoble Alpes (ANR-17-EURE-0003).

## Disclosure

The authors report no disclosures relevant to the manuscript. Go to [Neurology.org/NN](https://www.neurology.org/NN) for full disclosure.

## Publication History

Received by *Neurology: Neuroimmunology & Neuroinflammation* July 28, 2022. Accepted in final form October 10, 2022. Submitted and externally peer reviewed. The handling editor was Josep O. Dalmau, MD, PhD, FAAN.

## Appendix Authors

Name	Location	Contribution
<b>Juliette Svahn, MD</b>	Electroneuromyography and Neuromuscular Department, Pierre Wertheimer Hospital, Hospices Civils de Lyon, Lyon, France; Institut NeuroMyoGène Physiopathologie et génétique du neurone et du muscle (INMG-PGNM), CNRS UMR5261, INSERM U1315, Faculté de Médecine Rockefeller, Université Claude Bernard Lyon	Drafting/revision of the manuscript for content, including medical writing for content; major role in the acquisition of data; study concept or design; and analysis or interpretation of data
<b>Laurent Coudert, PhD</b>	Institut NeuroMyoGène Physiopathologie et génétique du neurone et du muscle (INMG-PGNM), CNRS UMR5261, INSERM U1315, Faculté de Médecine Rockefeller, Université Claude Bernard Lyon	Major role in the acquisition of data; study concept or design; and analysis or interpretation of data
<b>Nathalie Streichenberger, MD</b>	Institut NeuroMyoGène Physiopathologie et génétique du neurone et du muscle (INMG-PGNM), CNRS UMR5261, INSERM U1315, Faculté de Médecine Rockefeller, Université Claude Bernard Lyon; Department of Neuropathology, Hospices Civils de Lyon, Lyon, France	Drafting/revision of the manuscript for content, including medical writing for content; major role in the acquisition of data; study concept or design; and analysis or interpretation of data
<b>Alexandra Kraut, MS</b>	Univ. Grenoble Alpes, INSERM, CEA, UMR BioSanté U1292, CNRS, CEA, FR2048	Major role in the acquisition of data; study concept or design; and analysis or interpretation of data
<b>Alice Gravier-Dumonceau-Mazelier, MD</b>	Electroneuromyography and Neuromuscular Department, Pierre Wertheimer Hospital, Hospices Civils de Lyon, Lyon, France	Drafting/revision of the manuscript for content, including medical writing for content; major role in the acquisition of data; study concept or design; and analysis or interpretation of data
<b>Ludivine Rotard, MS</b>	Institut NeuroMyoGène Physiopathologie et génétique du neurone et du muscle (INMG-PGNM), CNRS UMR5261, INSERM U1315, Faculté de Médecine Rockefeller, Université Claude Bernard Lyon	Major role in the acquisition of data and analysis or interpretation of data

Continued

## Appendix (continued)

Name	Location	Contribution
<b>Laurence Calemard-Michel, MD</b>	Institut NeuroMyoGène Physiopathologie et génétique du neurone et du muscle (INMG-PGNM), CNRS UMR5261, INSERM U1315, Faculté de Médecine Rockefeller, Université Claude Bernard Lyon; Department of Molecular Endocrinology and Rare Diseases, Hospices Civils de Lyon, Lyon, France	Major role in the acquisition of data; study concept or design; and analysis or interpretation of data
<b>Rita Menassa, MD</b>	Institut NeuroMyoGène Physiopathologie et génétique du neurone et du muscle (INMG-PGNM), CNRS UMR5261, INSERM U1315, Faculté de Médecine Rockefeller, Université Claude Bernard Lyon; Department of Molecular Endocrinology and Rare Diseases, Hospices Civils de Lyon, Lyon, France	Major role in the acquisition of data; study concept or design; and analysis or interpretation of data
<b>Elisabeth Errazuriz-Cerda, MS</b>	Centre d'imagerie quantitative Lyon Est (CIQLE)	Major role in the acquisition of data; study concept or design; and analysis or interpretation of data
<b>Lara Chalabreysse, MD</b>	Department of Neuropathology, Hospices Civils de Lyon, Lyon, France	Major role in the acquisition of data and analysis or interpretation of data
<b>Alexis Osseni, PhD</b>	Institut NeuroMyoGène Physiopathologie et génétique du neurone et du muscle (INMG-PGNM), CNRS UMR5261, INSERM U1315, Faculté de Médecine Rockefeller, Université Claude Bernard Lyon	Drafting/revision of the manuscript for content, including medical writing for content; major role in the acquisition of data; study concept or design; and analysis or interpretation of data
<b>Christophe Vial, MD</b>	Electroneuromyography and Neuromuscular Department, Pierre Wertheimer Hospital, Hospices Civils de Lyon, Lyon, France	Major role in the acquisition of data; study concept or design; and analysis or interpretation of data
<b>Laurentiu Jomir, MD</b>	Electroneuromyography and Neuromuscular Department, Pierre Wertheimer Hospital, Hospices Civils de Lyon, Lyon, France	Major role in the acquisition of data; study concept or design; and analysis or interpretation of data
<b>François Tronc, MD</b>	Department of thoracic surgery, Hospices Civils de Lyon, Lyon, France	Major role in the acquisition of data; study concept or design; and analysis or interpretation of data
<b>Do Le Duy, PhD</b>	Institut NeuroMyoGène INMG-MeLiS, CNRS UMR5284, INSERM U1314, SynatAc Team, Faculté de Médecine Rockefeller, Universités de Lyon, Université Claude Bernard Lyon 1, Lyon, France French Reference Center on Paraneoplastic Neurological Syndromes and Autoimmune Encephalitis, Hospices Civils de Lyon, Lyon, France	Study concept or design

## Appendix (continued)

Name	Location	Contribution
<b>Emilien Bernard, MD</b>	Electroneuromyography and Neuromuscular Department, Pierre Wertheimer Hospital, Hospices Civils de Lyon, Lyon, France; Institut NeuroMyoGène Physiopathologie et génétique du neurone et du muscle (INMG-PGNM), CNRS UMR5261, INSERM U1315, Faculté de Médecine Rockefeller, Université Claude Bernard Lyon	Major role in the acquisition of data; study concept or design; and analysis or interpretation of data
<b>Vincent Gache, PhD</b>	Institut NeuroMyoGène Physiopathologie et génétique du neurone et du muscle (INMG-PGNM), CNRS UMR5261, INSERM U1315, Faculté de Médecine Rockefeller, Université Claude Bernard Lyon	Study concept or design and analysis or interpretation of data
<b>Yohann Couté, PhD</b>	Univ. Grenoble Alpes, INSERM, CEA, UMR BioSanté U1292, CNRS, CEA, FR2048	Drafting/revision of the manuscript for content, including medical writing for content; major role in the acquisition of data; study concept or design; and analysis or interpretation of data
<b>Vincent Jacquemond, PhD</b>	Institut NeuroMyoGène Physiopathologie et génétique du neurone et du muscle (INMG-PGNM), CNRS UMR5261, INSERM U1315, Faculté de Médecine Rockefeller, Université Claude Bernard Lyon	Drafting/revision of the manuscript for content, including medical writing for content; study concept or design; and analysis or interpretation of data
<b>Laurent Schaeffer, PhD</b>	Institut NeuroMyoGène Physiopathologie et génétique du neurone et du muscle (INMG-PGNM), CNRS UMR5261, INSERM U1315, Faculté de Médecine Rockefeller, Université Claude Bernard Lyon	Drafting/revision of the manuscript for content, including medical writing for content, and analysis or interpretation of data
<b>Pascal Leblanc, PhD</b>	Institut NeuroMyoGène Physiopathologie et génétique du neurone et du muscle (INMG-PGNM), CNRS UMR5261, INSERM U1315, Faculté de Médecine Rockefeller, Université Claude Bernard Lyon	Drafting/revision of the manuscript for content, including medical writing for content; major role in the acquisition of data; study concept or design; and analysis or interpretation of data

## References

- Woodman SE, Sotgia F, Galbiati F, Minetti C, Lisanti MP. Caveolinopathies: mutations in caveolin-3 cause four distinct autosomal dominant muscle diseases. *Neurology*. 2004;62(4):538-543. doi: 10.1212/WNL.62.4.538.
- Hayashi YK, Matsuda C, Ogawa M, et al. Human PTRF mutations cause secondary deficiency of caveolins resulting in muscular dystrophy with generalized lipodystrophy. *J Clin Invest*. 2009;119(9):2623-2633. doi: 10.1172/JCI38660.
- Ansevin CF, Agamanolis DP. Rippling muscles and myasthenia gravis with rippling muscles. *Arch Neurol*. 1996;53(2):197-199. doi: 10.1001/archneur.1996.00550020113023.
- Schulte-Mattler WJ, Kley RA, Rothenfusser-Korber E, et al. Immune-mediated rippling muscle disease. *Neurology*. 2005;64(2):364-367. doi: 10.1212/01.WNL.0000149532.52938.5B.

5. Walker GR, Watkins T, Ansevin CF. Identification of autoantibodies associated with rippling muscles and myasthenia gravis that recognize skeletal muscle proteins: possible relationship of antigens and stretch-activated ion channels. *Biochem Biophysical Res Commun.* 1999;264(2):430-435. doi: 10.1006/bbrc.1999.1534.
6. Watkins TC, Zelinka LM, Kesic M, Ansevin CF, Walker GR. Identification of skeletal muscle autoantigens by expression library screening using sera from autoimmune rippling muscle disease (ARMD) patients. *J Cell Biochem.* 2006;99(1):79-87. doi: 10.1002/jcb.20857.
7. Lo HP, Bertini E, Mirabella M, et al. Mosaic caveolin-3 expression in acquired rippling muscle disease without evidence of myasthenia gravis or acetylcholine receptor autoantibodies. *Neuromuscul Disord.* 2011;21(3):194-203. doi: 10.1016/j.nmd.2010.11.015.
8. Dubey D, Beecher G, Hammami MB, et al. Identification of caveolae-associated protein 4 autoantibodies as a biomarker of immune-mediated rippling muscle disease in adults. *JAMA Neurol.* 2022;79(8):808. doi: 10.1001/jamaneurol.2022.1357.
9. Lo HP, Lim YW, Xiong Z, et al. Cavin4 interacts with Bin1 to promote T-tubule formation and stability in developing skeletal muscle. *J Cell Biol.* 2021;220(12):e201905065. doi: 10.1083/jcb.201905065
10. Dalakas MC. Inflammatory muscle diseases. *N Engl J Med.* 2015;372(18):1734-1747. doi: 10.1056/NEJMra1402225.
11. Liewluck T, Goodman BP, Milone M. Electrically active immune-mediated rippling muscle disease preceding breast cancer. *Neurologist.* 2012;18(3):155-158. doi: 10.1097/NRL.0b013e318251e70f.
12. Marx A, Willcox N, Leite MI, et al. Thymoma and paraneoplastic myasthenia gravis. *Autoimmunity.* 2010;43(5-6):413-427. doi: 10.3109/08916930903555935.
13. Dalakas MC. Complement in autoimmune inflammatory myopathies, the role of myositis-associated antibodies, COVID-19 associations, and muscle amyloid deposits. *Expert Rev Clin Immunol.* 2022;18(4):413-423. doi: 10.1080/1744666X.2022.2054803.



# Neurology<sup>®</sup> Neuroimmunology & Neuroinflammation

## Immune-Mediated Rippling Muscle Disease Associated With Thymoma and Anti-MURC/Cavin-4 Autoantibodies

Juliette Svahn, Laurent Coudert, Nathalie Streichenberger, et al.  
*Neurol Neuroimmunol Neuroinflamm* 2023;10;  
DOI 10.1212/NXI.0000000000200068

This information is current as of December 15, 2022

<b>Updated Information &amp; Services</b>	including high resolution figures, can be found at: <a href="http://nn.neurology.org/content/10/1/e200068.full.html">http://nn.neurology.org/content/10/1/e200068.full.html</a>
<b>References</b>	This article cites 13 articles, 1 of which you can access for free at: <a href="http://nn.neurology.org/content/10/1/e200068.full.html#ref-list-1">http://nn.neurology.org/content/10/1/e200068.full.html#ref-list-1</a>
<b>Errata</b>	An erratum has been published regarding this article. Please see <a href="#">next page</a> or: <a href="/content/10/2/e200101.full.pdf">/content/10/2/e200101.full.pdf</a>
<b>Permissions &amp; Licensing</b>	Information about reproducing this article in parts (figures,tables) or in its entirety can be found online at: <a href="http://nn.neurology.org/misc/about.xhtml#permissions">http://nn.neurology.org/misc/about.xhtml#permissions</a>
<b>Reprints</b>	Information about ordering reprints can be found online: <a href="http://nn.neurology.org/misc/addir.xhtml#reprintsus">http://nn.neurology.org/misc/addir.xhtml#reprintsus</a>

*Neurol Neuroimmunol Neuroinflamm* is an official journal of the American Academy of Neurology. Published since April 2014, it is an open-access, online-only, continuous publication journal. Copyright Copyright © 2023 The Author(s). Published by Wolters Kluwer Health, Inc. on behalf of the American Academy of Neurology.. All rights reserved. Online ISSN: 2332-7812.



## Immune-Mediated Rippling Muscle Disease Associated With Thymoma and Anti-MURC/Cavin-4 Autoantibodies

*Neurol Neuroimmunol Neuroinflamm* 2023;10:e200101. doi:10.1212/NXI.000000000200101

In the Clinical/Scientific Note “Immune-Mediated Rippling Muscle Disease Associated With Thymoma and Anti-MURC/Cavin-4 Autoantibodies” by Svahn et al.<sup>1</sup>, the designators for Figure 1 were incorrectly labeled. The article has been replaced by a corrected version with the updated designators. The original version with the changes highlighted is available from a link in the corrected article. The publisher regrets the errors.

### Reference

1. Svahn J, Coudert L, Streichenberger N, et al. Immune-mediated rippling muscle disease associated with thymoma and anti-MURC/cavin-4 autoantibodies. *Neurol Neuroimmunol Neuroinflamm*. 2023;10(1):e200068.