



Clinical authorization of amyloid PET in France: Towards a more precise diagnosis of Alzheimer's disease

Antoine Verger, T. Horowitz, F. Le Jeune, C. Prunier-Aesh, S. Querellou,
M.-O. Habert, E. Guedj

► To cite this version:

Antoine Verger, T. Horowitz, F. Le Jeune, C. Prunier-Aesh, S. Querellou, et al.. Clinical authorization of amyloid PET in France: Towards a more precise diagnosis of Alzheimer's disease. Médecine Nucléaire - Imagerie Fonctionnelle et Métabolique, 2023, 47 (4), pp.175-178. 10.1016/j.mednuc.2023.03.002 . hal-04415555

HAL Id: hal-04415555

<https://cnrs.hal.science/hal-04415555>

Submitted on 12 Apr 2024

HAL is a multi-disciplinary open access archive for the deposit and dissemination of scientific research documents, whether they are published or not. The documents may come from teaching and research institutions in France or abroad, or from public or private research centers.

L'archive ouverte pluridisciplinaire **HAL**, est destinée au dépôt et à la diffusion de documents scientifiques de niveau recherche, publiés ou non, émanant des établissements d'enseignement et de recherche français ou étrangers, des laboratoires publics ou privés.

Clinical authorization of amyloid PET in France: towards a more precise diagnosis of Alzheimer's disease

Antoine Verger^{1, 2}, Tatiana Horowitz^{3, 4, 5}, Florence Lejeune⁶, Caroline Prunier-Aesh⁷, Solène Querellou⁸, Marie-Odile Habert⁹, Eric Guedj^{3, 4, 5}, GT Neurologie SFMN¹⁰

¹Department of Nuclear Medicine & Nancyclotep Imaging platform, CHRU-Nancy, Université de Lorraine, 54000, Nancy, France.

²Université de Lorraine, IADI, INSERM, UMR 1254, 54000, Nancy, France

³Department of Nuclear Medicine, Assistance Publique-Hôpitaux de Marseille, Aix-Marseille Université, Timone University Hospital, 13000 Marseille, France.

⁴CERIMED, Aix-Marseille Université, 13000 Marseille, France.

⁵Aix-Marseille Université, CNRS, Ecole Centrale de Marseille, UMR 7249, Institut Fresnel, 13000 Marseille, France.

⁶ Department of Nuclear Medicine, Centre Eugène Marquis, 45000 Rennes, France.

⁷ Department of Nuclear Medicine, Médecine Nucléaire Tourangelle, 37170 Chambray les Tours, France.

⁸ Department of Nuclear Medicine, CHRU Brest, 29200 Brest, France.

⁹ Department of Nuclear Medicine, APHP Pitié-Salpêtrière, 75013 Paris, France.

¹⁰GT Neurologie : Groupe de Travail Neurologie, Société Française de Médecine Nucléaire : Clément Bouvet (Clermont), Caroline Bund (Strasbourg), Jacques Darcourt (Nice), Nicolas De Leiris (Grenoble), Anthime Flaus (Lyon), Eric Guedj (Marseille), Marie-Odile Habert (Paris), Aurélie Kas (Paris), Pierre-Olivier Kotzki (Nîmes), Florence Le Jeune (Rennes), Marie Mayer (Bordeaux), Izzie Namer (Strasbourg), Pierre Payoux (Toulouse), Caroline Prunier-Aesh (Tours), Maria-Joao Santiago-Ribeiro (Tours), Franck Semah (Lille), Antoine Verger (Nancy).

Adresse pour correspondance : Pr Antoine Verger, Médecine Nucléaire, Hôpital de Brabois, CHRU-
Nancy, Allée du Morvan, 54500 Vandoeuvre-les-Nancy, France.

Tel: (+33) 3 83 15 55 67; Fax: (+33) 3 83 15 38 39; E-mail: a.verger@chru-nancy.fr

Abstract

The recent clinical authorization of amyloid PET in France represents a crucial step for the nuclear medicine community involved in the diagnosis of Alzheimer's disease (AD). At the era of ATN (Amyloid, Tau, Neurodegeneration) biomarkers, amyloid PET fills a need in patients with an atypical or mixed clinical presentation, in particular young patients (< 65 years old), when the lumbar puncture is contraindicated or not feasible for technical reasons. Importantly, a negative amyloid PET scan discards the diagnosis of AD. Furthermore, early phase imaging of amyloid PET allows to estimate the perfusion neuronal state, increasing the diagnostic value of such PET radiotracer. Its role could be further developed in routine care for the selection and monitoring of promising disease modifiers therapies.

Keywords: Alzheimer disease, amyloid PET, biomarkers, ATN classification, clinical authorization

Résumé

La récente autorisation clinique de la TEP amyloïde en France représente une étape cruciale pour la communauté de la médecine nucléaire impliquée dans le diagnostic de la maladie d'Alzheimer (MA). A l'ère des biomarqueurs ATN (Amyloïde, Tau, Neurodégénérescence), la TEP amyloïde comble un réel besoin diagnostique chez les patients présentant une présentation clinique atypique ou mixte, en particulier les patients jeunes (< 65 ans), lorsque la ponction lombaire est contre-indiquée ou non réalisable pour raisons techniques. Il est important de noter qu'une TEP amyloïde négative écarte le diagnostic de MA. De plus, l'imagerie de phase précoce de la TEP amyloïde permet d'estimer la perfusion neuronale, augmentant la valeur diagnostique d'un tel radiotraceur TEP. Son rôle pourrait à l'avenir être développé davantage en soins courants pour la sélection et le suivi de thérapies anti-amyloïdes dans la MA.

Mots-clés: maladie d'Alzheimer, TEP amyloïde, biomarqueurs, classification ATN, autorisation clinique

The Haute Autorité de Santé (HAS) issued a favorable opinion on June 8, 2022 on clinical authorization for amyloid Positron Emission Tomography (PET) imaging with flutemetamol in the diagnosis of Alzheimer's disease (AD) with atypical clinical presentation and/or early age of onset under 65 years old. This authorization has been proposed under the following circumstances: i. when the cognitive deficit has been objectively confirmed and the cause of the cognitive disorder remains uncertain after an evaluation by a specialist and the explorations recommended by the guidelines and, ii. when the performance of a lumbar puncture to allow the research and assay of the biomarkers A β 42, Tau and phosphoTau in the cerebro-spinal fluid (CSF) is contraindicated, not feasible or has provided inconclusive results, i.e. equivocal results not interpretable, results in disagreement with clinical presentation. A negative amyloid PET scan discards the diagnosis of AD, even if another neurodegenerative disorder cannot be excluded. This represents a crucial step for the nuclear medicine community involved in the diagnosis of AD. By contrast, a positive amyloid PET is not in itself indicative of AD since positive findings can occur in non-AD forms of dementia (1). According to the data from the Banque Nationale Alzheimer (BNA), we could estimate at approximately 1000-1500, the number of patients who could benefit from this examination per year in France.

Today, the prevalence of dementias in France is estimated at approximately 900,000 people (2). Of these dementia cases, approximately two-thirds are attributable to AD. With the aging of the population, this figure should double by 2,050 affecting on average 1 in 6 patients after 80 years. In addition to the life expectancy, which is clearly reduced in these patients, the cost relating to this pathology comes from the loss of autonomy leading to significant expenses related to dependency. The average societal cost is estimated at around 16,500 euros per person per year (Institut Français de la Moëlle et du Cerveau). An accurate diagnosis could limit the costs related to the delay in in medical care.

AD and related syndromes generally occur after the age of 65 (3) and are mainly manifested by an inaugural amnesic syndrome subsequently affecting other cognitive spheres, i.e. executive functions,

language, gestures, gnosis. However, several ADs may initially be manifested by other cognitive-behavioral disorders: aphasia, visuo-spatial, or psycho-behavioral disorders. These “atypical” forms of AD, which are not uncommon, are more difficult to differentiate from other diseases, such as frontotemporal dementia or Lewy body disease, than the typical clinical forms. In addition, more than 30,000 French patients with dementia are estimated early-onset degenerative disease, i.e. before the age of 65, with only a small number of which are of genetic origin. Early-onset forms of AD represent a complex diagnostic challenge.

The current formal diagnosis is based solely on post-mortem histological data. Alzheimer's disease is defined by the association of a clinical dementia syndrome with the presence of two histological characteristics, the extraneuronal accumulation of β -amyloid plaques ($A\beta$ pathology) which appears years before clinical symptoms, following by the intraneuronal deposition of Tau protein or “degeneration neurofibrillary” (Tau pathology), directly linked to the cognitive deficits.

Diagnosis based solely on clinical criteria shows insufficient performance since approximately 35% of clinically defined ADs are in fact not ADs, the many atypical forms of AD limiting the diagnostic accuracy (4). This has led expert groups to include biomarkers in the diagnosis, which can be biological or obtained from PET imaging.

The ATN classification defined by the NIA-AA (National Institute on Aging and Alzheimer's Association) group in 2018 marked a major turning point in the diagnosis of AD in research by systematically integrating the pathology biomarkers $A\beta$ and Tau in the diagnosis of AD, whether they are obtained by biology or imaging (5). More recently, the IWG (International Working Group) took up these diagnostic elements of biomarkers by associating them with clinically objectified cognitive impairment for care criteria (6).

If the AD biomarkers can be obtained through CSF analyses, a certain number of patients are contraindicated in performing a lumbar puncture, e.g. patients with anti-coagulant treatment, representing more than 3 million people in 2013 according to the Agence Nationale pour la Santé et le Médicament, or the realization of the latter is impossible, e.g. excessive scoliosis in elderly

subjects, non-compliant patients or categorically refusing the gesture, or the results of the biological biomarkers are inconclusive representing approximately 4% of lumbar punctures (7). Currently in France, these patients are wandering or even in a diagnostic impasse.

The Food and Drug Administration (FDA) conditionally approved aducanumab (June 7, 2021) an anti-amyloid immunotherapy in the indication of "Alzheimer's disease". It was the first so-called "disease modifier" treatment to obtain approval from the drug regulatory authorities, although it is temporary for the time being pending subsequent clinical results confirming its effectiveness. However, for the time, the European Agency of Medicines did not approve this medication. More recently, the FDA approved lecanemab (January 6, 2023), another anti-amyloid antibody, which shows a significant reduction of clinical decline in a large global clinical study of 1,795 participants with early AD in addition to a significant reduction of amyloid PET burden (8). The prospect of routine access to anti-amyloid medications reinforces the need to establish the diagnosis of AD in patients likely to be treated with these medications by confirmation of cerebral amyloidopathy.

The current literature includes number of studies validating the clinical interest of performing amyloid PET in clinical routine. The most consistent is that of Rabinovici et al. (9) (IDEAS study, The Imaging Dementia—Evidence for Amyloid Scanning), under the aegis of the American College of Radiology, which is a multicenter and longitudinal study of 11,409 patients (patients >65 years old, suspicion of clinical AD) which shows that up to 30% of patients with dementia and nearly 50% of patients with mild cognitive impairment (MCI) may have an erroneous etiological diagnosis of AD which could be ruled out by a negative amyloid PET scan. This study was carried out with the 3 fluorine-labelled radiotracers to image amyloid pathology (flutemetamol, florbetapir and florbetaben). It showed changes in the management strategy in 60.2% of MCI subjects and 63.5% of subjects with dementia. The proportion of subjects with a diagnosis of AD increased from 80 to 96% in subjects with positive PET A β results and, very importantly, decreased from 72 to 10% in subjects with negative PET A β results. Moreover, PET imaging also had a strong impact on diagnostic confidence, reducing uncertain diagnoses from 72 to 16 %.

Another study is that of Zwan et al (10), prospective and bicentric, carried out in 211 patients suspected of dementia with an MMSE ≥ 18 and an age ≤ 70 years. Only flutemetamol was considered in this study. Results were similar to the previous multicenter study with a change in patient management in 37% of them, a diagnostic change in 19% and an increase in diagnostic confidence from 69 to 88%. The strength of these two latest studies is their “real-life” integration to measure the impact of adding an amyloid PET scan to patient care. A limitation is the lack of correlation with biological biomarkers.

In France, two "real life" studies were carried out with florbetaben, another amyloid PET radiotracer. These studies focused on the impact of the management of patients with suspected AD for whom lumbar puncture was not available (contraindicated, not feasible or with non-contributory results) (11) or only with results non-contributory (7). Findings of these studies were similar for changes in patient management: respectively 39 and 19% of intention-to-treat treatment changes with increases in diagnostic confidence among medical specialists. These two French studies have the merit of having been carried out in populations targeted by the current approval from local authorities.

The Review study by Barthel et al (12), confirms the clinical usefulness of amyloid imaging with an average change in diagnosis in 29% of cases, with a gain in diagnostic confidence of 63% , an overall change in care of 64% and a change in drug treatments of 38% on average. Moreover, a longitudinal study recently showed that patients having benefited from an amyloid PET had lower risks of institutionalization (10% vs. 21%), mortality rate (11% vs. 18%) and lower health-care costs in the years after diagnosis compared to matched no-PET patients (13).

An important point is the comparison of CSF and imaging biomarkers for amyloid pathology. If the concordance observed between the two biomarkers is good, about 85%, (14), there are discrepancies observed between biology and imaging for the amyloid marker (15–17). Participants with a CSF+/PET– amyloid profile are at an earlier clinical and biological stage of the disease and have a

better prognosis for at least 5 years than those with CSF+/PET+. In this sense, prognostic data from amyloid PET are also to be expected from the ongoing multicenter AMYPAD study (18).

The international recommendations mention the use of amyloid PET in the clinical indications indicated by the HAS (young and atypical forms of AD) (19) and those coming from the national Centre Mémoire Ressources et Recherche (CMRR)- Société Française de Médecine Nucléaire (SFMN) coordination specify the use of PET amyloid in these indications (patients with atypical clinical symptoms or typical symptoms of early onset dementia and lumbar puncture contraindicated, not feasible or giving inconclusive results) (20).

More recent expert recommendations (21) proposed the search for amyloid pathology for suspicious forms of atypical AD while highlighting the lower number of contraindications or adverse effects of PET compared to lumbar puncture (including post-lumbar puncture headaches affecting up to 10% of subjects), as well as a lower variability inter-center and inter-individual imaging biomarkers. In addition, the amyloid PET imaging biomarkers allow visualization of lesion extension and location. In any case, CSF and imaging biomarkers are complementary in the assessment of AD diagnosis, and their respective role could be further discussed with the recent development of plasmatic biomarkers for AD (22). The collaboration of nuclear medicine departments with its referent CMRR, well-structured entities in France, is essential to facilitate the selection of patients who will mostly benefit from the amyloid PET.

On the other hand, interesting perspectives are addressed with this current clinical authorization of amyloid PET imaging. Early phase imaging of amyloid PET allows to estimate the perfusion neuronal state and it has been showed to be comparable to that of metabolism at the single-subject level by parametric analysis, particularly in the presence of a high neurodegeneration burden (23). These findings could at term, replace a part of the investigations in neurodegenerative disorders covered by ^{18}F -FDG PET. With the development of disease modifiers therapy in AD and the ageing of the population, an increased number of patients might be addressed for such amyloid PET imaging investigations. These potential increased number of amyloid PET scans expected in the next years

should nevertheless be contra-balanced with the cost of these radiotracers, insufficiently covered by their reimbursement in France. However, development of cost-effective dedicated brain PET imaging devices, with increased sensitivity allowed by detectors arrangement in a compact hemisphere, could be a solution to the expected increase number of brain PET acquisitions needed (23). This potential increase of brain PET investigations will also require the training of many nuclear medicine physicians for the visual amyloid PET image interpretation. Some keys of visual interpretation are described in the SNMMI/EANM guidelines for PET imaging, and the nuclear physician should be aware that specific criteria for amyloid PET image interpretation may differ among amyloid PET radiotracers (24). In the report, any areas in which cerebral cortical uptake is more intense than white matter uptake should be noted. The nuclear physician should state clearly whether the scan demonstrates moderate or frequent amyloid deposition in the cerebral cortex (positive result) or not (negative result). Online training programs are currently available. Figure 1 depicts typical positive and negative amyloid PET scans with flutemetamol. Some tools are currently developed for assisting nuclear medicine physicians in their visual assessment by integrating automatic semi-quantification, quantification possibly detecting earlier pathological deposition (25,26). In this line, the centiloid scale, aiming at harmonizing quantitative measurements of amyloid PET imaging will be of great interest value for trials evaluating different type of amyloid PET radiotracers (27).

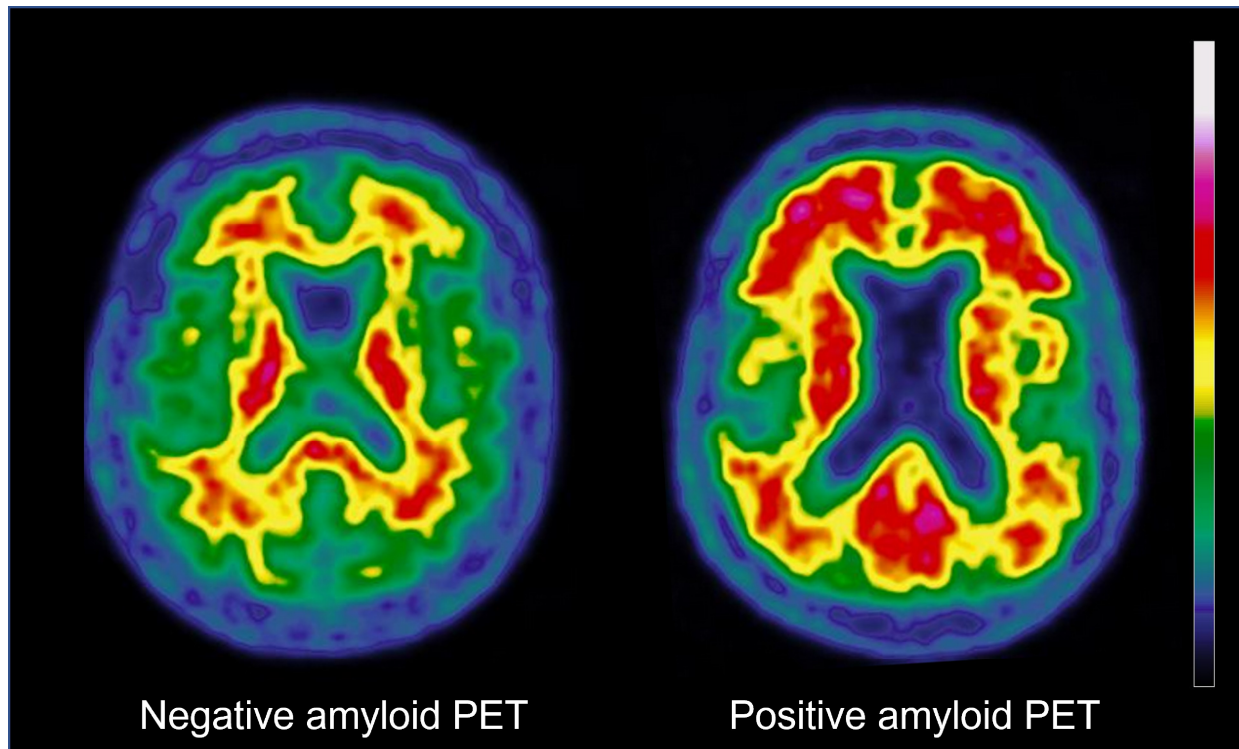
As a conclusion, amyloid PET provides real added value, currently not covered in patients with an atypical or mixed clinical presentation, in particular young patients (< 65 years old), when lumbar puncture is contraindicated for medical reasons or not feasible for technical reasons.

In this context, the examination could be requested by clinicians who are experts in dementia working in memory centers, after multidisciplinary consultation. Importantly, a negative amyloid PET scan discards the diagnosis of AD and this information should be mentioned by the nuclear physician in the report. By contrast, a positive amyloid PET scan cannot be by itself indicative of AD.

Furthermore, early phase imaging of amyloid PET allows to estimate the perfusion neuronal state,

increasing the diagnostic value of such PET radiotracer. Its role could be further developed in routine care for the selection and monitoring of promising disease modifiers therapies.

Figure 1. Typical images of amyloid PET imaging. On the left part, a typical negative amyloid PET with flutemetamol in a 69-years-old man. On the right part, a typical positive amyloid PET with flutemetamol in a 78-years-old man.



References

1. Villemagne VL, Ong K, Mulligan RS, Holl G, Pejoska S, Jones G, et al. Amyloid Imaging with ¹⁸F-Florbetaben in Alzheimer Disease and Other Dementias. *J Nucl Med.* août 2011;52(8):1210-7.
2. Jacqmin-Gadda H, Alperovitch A, Montlahuc C, Commenges D, Leffondre K, Dufouil C, et al. 20-Year prevalence projections for dementia and impact of preventive policy about risk factors. *Eur J Epidemiol.* juin 2013;28(6):493-502.
3. Winblad B, Amouyel P, Andrieu S, Ballard C, Brayne C, Brodaty H, et al. Defeating Alzheimer's disease and other dementias: a priority for European science and society. *Lancet Neurol.* avr 2016;15(5):455-532.
4. Boccardi M, Altomare D, Ferrari C, Festari C, Guerra UP, Paghera B, et al. Assessment of the Incremental Diagnostic Value of Florbetapir F 18 Imaging in Patients With Cognitive Impairment: The Incremental Diagnostic Value of Amyloid PET With [¹⁸F]-Florbetapir (INDIA-FBP) Study. *JAMA Neurol.* 1 déc 2016;73(12):1417.
5. Jack CR, Bennett DA, Blennow K, Carrillo MC, Dunn B, Haeberlein SB, et al. NIA-AA Research Framework: Toward a biological definition of Alzheimer's disease. *Alzheimers Dement J Alzheimers Assoc.* 2018;14(4):535-62.
6. Dubois B, Villain N, Frisoni GB, Rabinovici GD, Sabbagh M, Cappa S, et al. Clinical diagnosis of Alzheimer's disease: recommendations of the International Working Group. *Lancet Neurol.* juin 2021;20(6):484-96.
7. Manca C, Hopes L, Kearney-Schwartz A, Roch V, Karcher G, Baumann C, et al. Assessment of 18F-Florbetaben Amyloid PET Imaging in Patients with Suspected Alzheimer's Disease and Isolated Increase in Cerebrospinal Fluid Tau Proteins. *J Alzheimers Dis JAD.* 2019;68(3):1061-9.
8. van Dyck CH, Swanson CJ, Aisen P, Bateman RJ, Chen C, Gee M, et al. Lecanemab in Early Alzheimer's Disease. *N Engl J Med.* 5 janv 2023;388(1):9-21.
9. Rabinovici GD, Gatsonis C, Apgar C, Chaudhary K, Gareen I, Hanna L, et al. Association of Amyloid Positron Emission Tomography With Subsequent Change in Clinical Management Among Medicare Beneficiaries With Mild Cognitive Impairment or Dementia. *JAMA.* 2 avr 2019;321(13):1286-94.
10. Zwan MD, Bouwman FH, Konijnenberg E, van der Flier WM, Lammertsma AA, Verhey FRJ, et al. Diagnostic impact of [18F]flutemetamol PET in early-onset dementia. *Alzheimers Res Ther.* déc 2017;9(1):2.
11. Ceccaldi M, Jonveaux T, Verger A, Krolak-Salmon P, Houzard C, Godefroy O, et al. Added value of 18F-florbetaben amyloid PET in the diagnostic workup of most complex patients with dementia in France: A naturalistic study. *Alzheimers Dement J Alzheimers Assoc.* mars 2018;14(3):293-305.
12. Barthel H, Sabri O. Clinical Use and Utility of Amyloid Imaging. *J Nucl Med.* nov 2017;58(11):1711-7.
13. van Maurik IS, Broulikova HM, Mank A, Bakker ED, de Wilde A, Bouwman FH, et al. A more precise diagnosis by means of amyloid PET contributes to delayed institutionalization, lower

mortality, and reduced care costs in a tertiary memory clinic setting. *Alzheimers Dement*. 23 nov 2022;alz.12846.

14. Zwan M, van Harten A, Ossenkoppele R, Bouwman F, Teunissen C, Adriaanse S, et al. Concordance between cerebrospinal fluid biomarkers and [11C]PIB PET in a memory clinic cohort. *J Alzheimers Dis JAD*. 2014;41(3):801-7.
15. Pannee J, Portelius E, Minthon L, Gobom J, Andreasson U, Zetterberg H, et al. Reference measurement procedure for CSF amyloid beta (A β)1-42 and the CSF A β 1-42 /A β 1-40 ratio - a cross-validation study against amyloid PET. *J Neurochem*. nov 2016;139(4):651-8.
16. Schindler SE, Gray JD, Gordon BA, Xiong C, Batrla-Utermann R, Quan M, et al. Cerebrospinal fluid biomarkers measured by Elecsys assays compared to amyloid imaging. *Alzheimers Dement J Alzheimers Assoc*. nov 2018;14(11):1460-9.
17. Reimand J, Collij L, Scheltens P, Bouwman F, Ossenkoppele R, Alzheimer's Disease Neuroimaging Initiative. Association of amyloid- β CSF/PET discordance and tau load five years later. *Neurology*. 10 sept 2020;
18. Lopes Alves I, Collij LE, Altomare D, Frisoni GB, Saint-Aubert L, Payoux P, et al. Quantitative amyloid PET in Alzheimer's disease: the AMYPAD prognostic and natural history study. *Alzheimers Dement*. mai 2020;16(5):750-8.
19. Johnson KA, Minoshima S, Bohnen NI, Donohoe KJ, Foster NL, Herscovitch P, et al. Appropriate use criteria for amyloid PET: a report of the Amyloid Imaging Task Force, the Society of Nuclear Medicine and Molecular Imaging, and the Alzheimer's Association. *Alzheimers Dement J Alzheimers Assoc*. janv 2013;9(1):e-1-16.
20. Koric L, Guedj E, Habert MO, Semah F, Branger P, Payoux P, et al. Molecular imaging in the diagnosis of Alzheimer's disease and related disorders. *Rev Neurol (Paris)*. déc 2016;172(12):725-34.
21. Chételat G, Arbizu J, Barthel H, Garibotto V, Law I, Morbelli S, et al. Amyloid-PET and 18F-FDG-PET in the diagnostic investigation of Alzheimer's disease and other dementias. *Lancet Neurol*. nov 2020;19(11):951-62.
22. Cullen NC, Leuzy A, Janelidze S, Palmqvist S, Svenningsson AL, Stomrud E, et al. Plasma biomarkers of Alzheimer's disease improve prediction of cognitive decline in cognitively unimpaired elderly populations. *Nat Commun*. déc 2021;12(1):3555.
23. Catana C. Development of Dedicated Brain PET Imaging Devices: Recent Advances and Future Perspectives. *J Nucl Med*. août 2019;60(8):1044-52.
24. Minoshima S, Drzezga AE, Barthel H, Bohnen N, Djekidel M, Lewis DH, et al. SNMMI Procedure Standard/EANM Practice Guideline for Amyloid PET Imaging of the Brain 1.0. *J Nucl Med*. août 2016;57(8):1316-22.
25. Peira E, Poggiali D, Pardini M, Barthel H, Sabri O, Morbelli S, et al. A comparison of advanced semi-quantitative amyloid PET analysis methods. *Eur J Nucl Med Mol Imaging*. oct 2022;49(12):4097-108.

26. Bucci M, Savitcheva I, Farrar G, Salvadó G, Collij L, Doré V, et al. A multisite analysis of the concordance between visual image interpretation and quantitative analysis of [18F]flutemetamol amyloid PET images. *Eur J Nucl Med Mol Imaging*. juill 2021;48(7):2183-99.
27. Klunk WE, Koeppe RA, Price JC, Benzinger TL, Devous MD, Jagust WJ, et al. The Centiloid Project: Standardizing quantitative amyloid plaque estimation by PET. *Alzheimers Dement*. janv 2015;11(1):1.