



HAL
open science

Innovative treatments for meningiomas

T. Graillon, Emeline Tabouret, B. Salgues, T. Horowitz, L. Padovani, R. Appay, K. Farah, H. Dufour, J. Régis, E. Guedj, et al.

► To cite this version:

T. Graillon, Emeline Tabouret, B. Salgues, T. Horowitz, L. Padovani, et al.. Innovative treatments for meningiomas. *Revue Neurologique*, 2023, 179 (5), pp.449-463. 10.1016/j.neurol.2023.03.006 . hal-04415615

HAL Id: hal-04415615

<https://cnrs.hal.science/hal-04415615v1>

Submitted on 14 Apr 2024

HAL is a multi-disciplinary open access archive for the deposit and dissemination of scientific research documents, whether they are published or not. The documents may come from teaching and research institutions in France or abroad, or from public or private research centers.

L'archive ouverte pluridisciplinaire **HAL**, est destinée au dépôt et à la diffusion de documents scientifiques de niveau recherche, publiés ou non, émanant des établissements d'enseignement et de recherche français ou étrangers, des laboratoires publics ou privés.

Innovative treatments for meningiomas

**T.Graillon, E.Tabouret, B.Salgues, T.Horowitz, L.Padovani, R.Appay, K.Farah, H.Dufour,
J.Régis, E.Guedj, A.Barlier, O.Chinot**

Abstract

Multi-recurrent high-grade meningiomas remain an unmet medical need in neuro-oncology when iterative surgeries and radiation therapy sessions fail to control tumor growth.

Nevertheless, the last 10 years have been marked by multiple advances in the comprehension of meningioma tumorigenesis via the discovery of new driver mutations, the identification of activated intracellular signaling pathways, and DNA methylation analyses, providing multiple potential therapeutic targets.

Today, Anti-VEGF and mTOR inhibitors are the most used and probably the most active drugs in aggressive meningiomas.

Peptide radioactive radiation therapy aims to target SSTR2A receptors, which are strongly expressed in meningiomas, but have an insufficient effect in most aggressive meningiomas, requiring the development of new techniques to increase the dose applied to the tumor.

Based on the multiple potential intracellular targets, multiple targeted therapy clinical trials targeting Pi3K-Akt-mTOR and MAP kinase pathways as well as cell cycle and particularly, cyclin D4-6 are ongoing. Recently discovered driver mutations, *SMO*, *Akt*, and *PI3KCA*, offer

new targets but are mostly observed in benign meningiomas, limiting their clinical relevance mainly to rare aggressive skull base meningiomas. Therefore, *NF2* mutation remains the most frequent mutation and main challenging target in high-grade meningioma. Recently, inhibitors of focal adhesion kinase (FAK), which is involved in tumor cell adhesion, were tested in a phase 2 clinical trial with interesting but insufficient activity. The Hippo pathway was demonstrated to interact with *NF2*/Merlin and could be a promising target in *NF2*-mutated meningiomas with ongoing multiple preclinical studies and a phase 1 clinical trial. Recent advances in immune landscape comprehension led to the proposal of the use of immunotherapy in meningiomas. Except in rare cases of *MSH2/6* mutation or high tumor mass burden, the activity of PD-1 inhibitors remains limited; however, its combination with various radiation therapy modalities is particularly promising. On the whole, therapeutic management of high-grade meningiomas is still challenging even with multiple promising therapeutic targets and innovations.

Key words: Meningioma, targeted therapy, immunotherapy, radiation therapy, mutations, peptide receptor radionuclide therapy

Acknowledgments: this study was partly supported by research funding from the Canceropôle Provence Alpes Côte d'Azur, Gefluc Marseille-Provence, Institut National du Cancer and Région Sud

1. Introduction

Meningiomas are the most frequent intracranial tumor in adults [1]. Meningiomas are more frequent in females with an M/F ratio of 2/1 or 3/1 but are more aggressive in males.

Malignant meningiomas are rare, in contrast, WHO grade 2 meningiomas represent 10%–20% of operated meningiomas with a time increasing ratio WHO grade 2/WHO grade 1 [2-5].

Meningiomas arise from arachnoid cap cells and therefore can occur in various locations: the convexity, in the parasagittal area invading venous sinuses, in the skull base, the posterior fossa, and spinal location. Metastasis remains rare even in high grades, but their occurrence leads to redefine therapeutic strategy.

According to the 2021 WHO classification, the current reference treatment for meningiomas is surgical removal for growing or symptomatic tumors; however, in the case of non-symptomatic and non-growing tumors, observation is only recommended. Regarding other local therapies, radiosurgery or stereotactic radiation therapy could be alternatives for growing volume-limited tumors. The very long-term, high safety and efficacy of stereotactic radiosurgery (SRS) for skull base meningiomas as well as the long-term tumor control of small or middle-sized meningiomas has been well demonstrated.[6, 7]. Radiosurgery has been shown to be especially safe in meningiomas enclosed in the cavernous sinus and those of the petroclival area [8-11]. Complementary radiation therapy after surgical resection is indicated in WHO grade 3 meningioma, WHO grade 2 meningioma with a postoperative residue, or WHO grade 1 meningioma with a growing residue.

Nevertheless, when multiple surgeries and radiation therapy sessions fail to control tumor growth, no standard treatment are retained. Therefore, multi-recurrent high-grade

meningiomas or those that are non-accessible to surgery such as invasive skull base meningiomas remain an unmet medical need.

In the last 10 years, multiple and major advances have been performed in understanding meningioma tumorigenesis. The discovery of multiple driver mutations, DNA methylation studies, activation of intracellular signaling pathways, and more recently, immune landscape description, revealed multiple potential therapeutic targets and opened promising therapeutic perspectives.

The aim of this review is to provide an update on current and future innovative treatments for meningiomas.

2. Recent advances in understanding meningioma tumorigenesis and their clinical implications

2.1. 2021 WHO classification: What is new?

According to the 2021 WHO Classification of Tumors of the Central Nervous System (CNS), the morphological spectrum of meningiomas is now considered as a single tumor type with 15 subtypes [12].

For each tumor type, this last classification introduced the essential criteria (their absence excludes the diagnosis) and the desirable criteria (not mandatory but supporting the diagnosis). Regarding meningiomas, the main criteria are based on classical histopathological features according to the different meningioma subtypes or on suggestive histopathological features associated with molecular markers, such as *NF2*, *TRAF7*, *AKT1*, *KLF4*, *SMO*, *PIK3CA* alterations, and *SMARCE1* mutation in clear cell meningiomas [13]; *BAP1* mutation in rhabdoid and papillary meningiomas [14, 15]; or a DNA methylation class of meningioma. On the other hand, desirable criteria include meningeal localization, evidence of EMA and SSTR2A

protein expression with immunohistochemistry, or classic copy number alterations such as monosomy 22 or losses of 1p, 6, 10q, 14q, or 18.

Concerning the tumor grading in the 2021 WHO CNS classification, Arabic numerals are now used (instead of the previously used Roman numerals) and grades are defined within tumor types (instead of associating them with a tumor type). Accordingly, the grading criteria defining atypical (grade 2) or anaplastic (grade 3) meningiomas are applied across all meningioma subtypes, apart from the chordoid and clear cell subtypes, which are grade 2 considering their reported higher likelihood of recurrence. On the other hand, a grade 3 should no longer be assigned to the rhabdoid and papillary subtypes without any other criteria of malignancy [16].

The histopathological criteria for grading meningiomas remain unchanged; the latter include the number of mitotic figures in 10 consecutive high-power field of each 0.16 mm² (at least 2.5/mm²), unequivocal brain invasion, increased cellularity, small cells with high nucleus-to-cytoplasmic ratio, prominent nucleoli, patternless growth, foci of spontaneous necrosis, or frank anaplasia. However, as with gliomas, two molecular markers have also been introduced for assigning meningiomas to grade 3: the presence of a *TERT* promoter mutation and/or a homozygous deletion of *CDKN2A* [17, 18].

2.2. Genomic mutational landscape

In the last 10 years, multiple new driver mutations have been identified in meningiomas. *NF2* mutation or 22q chromosomal deletion remain the most frequent genomic alterations, particularly in high-grade meningiomas (40% in WHO grade 1 vs. 80% in WHO grades 2 and 3) [19].

Recently, an interesting parallelism was highlighted between meningeal embryology and tumorigenesis: driver mutations and their activated molecular pathways were demonstrated to be related to embryological cell origin and therefore, tumor location [20-22]. For instance, the mutations of *SMO* and *SUFU* genes involved in the Sonic Hedgehog signaling pathway are mostly observed in the anterior medial line skull base meningioma, while *POLR2A* was observed in suprasellar meningiomas. *TRAF7* mutations are mostly observed in the anterior and the medial skull base tumors. Association of the *TRAF7* and *KLF4* mutations leads to the angiomatous subtype. In contrast, *NF2* is mostly involved in convexity and parasagittal meningiomas, such as posterior fossa and spinal meningiomas. Recent potentially targetable *BAP-1* and *CDKN2A* mutations have been identified in rhabdoid subtypes and spinal meningiomas for *BAP-1* and in aggressive meningiomas for *CDKN2A* [15, 17].

TRAF7, *PI3KCA*, *AKT1*, *POLR2A*, and *SMO* mutations are mostly observed in benign WHO grade 1 meningiomas. Consequently, despite their putative targeting, the clinical and therapeutic interests of these mutations remain limited.

Approximately 2.5% of meningiomas have a high mutation level, some of which are associated with the loss of function in mismatch repair (MMR) genes (*MSH2/MSH6*) or MMR-related genes (*SETD2* or *POLE*), which are involved in only a few meningiomas but all with aggressive phenotypes. This genotype, even if rare, could highly impact clinical management suggesting to propose immunotherapy [23].

2.3. Methylation study

Sahm *et al.* recently highlighted methylation studies for prognostic classifications of meningiomas [24, 25]. Methylome profiling determined different classes improving the prediction in the risk of recurrence and aggressive course. Mutations such as those in the

PI3KCA, *AKT1*, and *TRAF7* genes were found in class 1 with a low rate of recurrence. However, the methylation classification could reclassify some WHO grade 1 meningiomas as aggressive meningiomas and conversely reclassify aggressive meningiomas as benign meningiomas. More recently, Choudhury *et al.* determined 3 different classes based on methylation profiling integrating genomic, transcriptomic data, and single cell RNA sequencing with co-culture organoids studies. Class 1 includes the *NF2*/Merlin intact meningiomas, with the best outcome; class 2 includes meningiomas with immune cell enrichment; and class 3 includes “hypermitotic” meningiomas with a higher rate of *NF2* genomic alterations [26]. The development of DNA methylation analysis in clinical practice remains limited to centers that have access to this technology and for which cost is not an issue but may help physicians in their management and decision regarding postoperative management of meningiomas although not yet included in the 2021 WHO CNS classification.

2.4. Targeted intracellular signaling pathways

Today, the Pi3K-Akt-mTOR pathway remains the main intracellular pathway for therapeutic targeting in meningioma. Its hyperactivation was identified many years ago [27-29]. We developed an *in vitro* model of a meningioma primary cell culture from surgically removed meningiomas and demonstrated that the mTOR targeting was relevant in meningiomas by decreasing cell viability and proliferation [30]. Nevertheless, mTOR inhibition was demonstrated to induce positive feedback on Akt phosphorylation, which could limit mTOR inhibitor efficacy. In inhibiting the Pi3K-Akt-mTOR pathway, the somatostatin agonists reversed the positive feedback on Akt phosphorylation induced by mTOR inhibitors, highlighting the relevance of a co-targeting strategy using somatostatin agonists and mTOR inhibitors [30, 31]. While mTOR inhibitors did not trigger apoptosis in our *in vitro* model, Pi3K inhibitors, which target upstream mTOR, led to cell apoptosis in approximately 40 % of

meningiomas without Akt activation [32]. PI3K-Akt-mTOR pathway interacts strongly with GSK3, a ubiquitous protein kinase involved in apoptosis and expressed in meningiomas, representing a potential therapeutic target [33].

The MAP kinase pathway is also a relevant target in meningiomas. This pathway was demonstrated to be tightly more activated in low-grade meningiomas. *In vitro*, MEK inhibition decreased meningioma cell proliferation [32, 34, 35]. Nevertheless, the clinical relevance of targeting the MAP kinase pathway in meningiomas remains to be assessed.

The hedgehog pathway could also be involved in meningioma tumorigenesis, particularly in anterior skull base and olfactory meningiomas. *SMO* mutations were found in 3%–5 % of meningiomas [20, 21]. *SMO* gene mutation coding for a 7-transmembrane receptor impacts the SHH pathway activation. Even when benign, these *SMO*-mutated tumors could be associated with a higher rate of recurrence compared with meningiomas with other mutated genes, such as *AKT1* [20].

The main genetic alterations remain on the *NF2* gene encoding the Merlin protein, a putative target particularly for aggressive meningiomas. Merlin has multiple roles including involvement in cell–cell adhesion and cell contact inhibition through focal adhesion kinase (FAK)-Src signaling. FAK is a non-tyrosine kinase receptor likely overexpressed in cancer, which interacts with integrins and downstream target proteins leading to tumor cell adhesion and tumor angiogenesis, promoting tumor growth, tumor invasion, and tumor ability to metastasize [36]. The Merlin-negative cells from the mesothelium were greatly dependent on extracellular matrix adhesion induced by FAK signaling for proliferation and apoptosis resistance and consequently are sensitive to FAK inhibition. FAK inhibitors are able

to decrease *in vitro* cell proliferation and mesothelium xenograft growth [37] and may represent a relevant treatment in Merlin-negative meningioma.

The loss of *CDKN2A* and *CDKN2B* on chromosome 9p increased the risk of recurrence with a poor outcome, classifying these tumors as WHO grade 3 [17]. In their study, Choudhury *et al.* suggested the use of cytostatic cell cycle inhibitors for such tumors. More specifically, they demonstrated that CDK4/6 inhibitors were able to block cell proliferation of *in vitro* models of co-culture organoids as well as xenograft growth [26].

Recently, *NF2* was shown to interact with the Hippo pathway in activating LATS1/2 phosphorylation [38]. Therefore, targeting the Hippo pathway in meningiomas is of interest, particularly in those with *NF2* mutations [39-41]. Data on mesothelioma bearing *NF2* alterations exist [42], but data on meningiomas with *NF2* alterations remain scarce.

SSTR2A receptors are strongly expressed in meningiomas at the same level in benign or aggressive and recurrent tumors [43-47]; however, the role of its high expression remains to be clarified. The mechanism of SSTR2A in controlling cell proliferation involves, at least partially, the Pi3K-Akt-mTOR pathway inhibition [43]. Octreotide treatment targeting SSTR2A decreased meningioma cell proliferation *in vitro*, but the clinical impact remains limited, particularly in aggressive meningiomas [43, 48]. Nevertheless, SSTR2A is certainly a therapeutic target for somatostatin agonists, largely used in clinical practice in neuroendocrine tumors. Beyond being therapeutic targets, SSTR2A are particularly useful targets for molecular imaging at diagnosis, as illustrated by OctreoScan© scintigraphy and more recently, positron emission tomography (PET) with ⁶⁸Gallium-DOTA-conjugated SSTR2A analogs such as ⁶⁸Ga-DOTATOC. Such molecular imaging techniques are helpful in diagnosis, for instance, to precise tumor histology as in optic nerve meningiomas, or to help in tumor

delineation in the preoperative planning or in the radiation therapy dosimetry planning [49]. In Nuclear Medicine, SSTR2A analogs can be coupled with a powerful radioactive element for therapy instead of ⁶⁸Gallium used for imaging. Considering that approximately 10% of meningiomas harbor a low or lack SSTR2A expression, such expression should be considered for PET DOTATOC interpretation and could limit the use of metabolic radiation therapy in such patients.

Other types of somatostatinergic receptors, SSTR1–5, are also expressed in 30%–40% of meningiomas [31]. The somatostatin agonist, pasireotide, targets not only SSTR2A but also SSTR1 and SSTR5. Previously, we have demonstrated that pasireotide was more effective on primary meningioma cells *in vitro* compared with octreotide to decrease cell proliferation [31]. However, its relevance in clinical practice remains uncertain [50].

Dopamine D2 receptors (D2DRs), which are used in the treatment of prolactinoma, for instance, were found to be expressed in most meningiomas [51-53], but this was not confirmed in D2 binding experiments [54], and clinical relevance remains uncertain.

However, *in vitro*, bromocriptine, a dopamine agonist, decreases cell proliferation of meningiomas [55]. In addition, a clinical case where meningioma growth was controlled by cabergoline was reported [56].

2.5. Immune landscape

Recently, many advances have been performed in the comprehension of the dura CNS immunosurveillance role. Wang *et al.* observed a large pattern of immune and non-immune cells with specific immune microenvironments both in the non-tumoral dura and in meningiomas [57]. The immune landscape was demonstrated to be different in skull base *versus* convexity meningiomas, with a higher rate of T-cells in the former *versus* a higher rate

of mast cells and neutrophils in the latter [58]. According to their methylation profile, Choudhury *et al.* described a group of meningiomas characterized by immune cell enrichment, including T-cells enrichment, as revealed by immunocytochemistry analyses. This group was named “immune-enriched meningiomas” (38%), and was mostly *NF2*-mutated with a worst outcome, suggesting a relationship between peritumoral immune response and tumor progression [26].

One case each of abscopal effect and long-term remission after nivolumab treatment in a patient with multi-recurrent high-grade meningioma suggest the relevance of immunotherapy in meningioma therapy [23, 59]. Nevertheless, the immune landscape, as in the role of the different immune cells and their interactions with meningioma and lymphatic vessels, remain poorly understood. PD-1 and PD-L1 expression seems stronger in aggressive meningiomas compared with those in benign meningiomas [60]. Other checkpoint inhibitors targets are expressed in meningiomas as PD-L2, which seems more expressed in meningiomas than PD-L1 [61]. B7-H3 and CTLA-4 are also expressed, suggesting immune checkpoints targeting relevance [58].

2.6. Progestin-related meningiomas

Progestin and 3 drugs in particular (acetate of cyproterone, acetate of chlormadinone, and acetate of norgestrol) have been involved in meningioma tumorigenesis and growth [62, 63]. Involvement of other progestins should be suspected on a case-by-case basis as pregnancy could be associated with meningioma growth. The mechanism leading to meningioma tumorigenesis remains uncertain. These meningiomas were demonstrated to harbor a high level of progesterone receptors expression [63]. Peyre *et al.* observed a high rate of *PI3KCA* mutation (approximately 35% vs. 3% in sporadic meningiomas) and in

contrast a low rate of *NF2* mutation (7.5% vs. 32% in sporadic meningiomas)) [64].

Interestingly, the prognosis of these progestin-related meningiomas remains favorable after progestin discontinuation leading to volume decrease or stabilization in most cases.

3. Historical treatments and their poor antitumoral activity

For many years, multiple clinical trials have been performed with various drugs and chemotherapy in aggressive meningiomas. Unfortunately, most of these trials led to poor results and highlighted the lack of antitumoral activity of various drugs, such as mifepristone (RU486), trabectedin, alkylating agent temozolomide, PDGF-R inhibitor imatinib, and EGFR inhibitors (erlotinib and gefitinib) [65-68]. Two drugs, hydroxyurea and octreotide (SSTR2A agonist), could be associated with limited but real activity, although their effects are clearly insufficient in aggressive meningiomas [69-75]. Nevertheless, these drugs could be an alternative in non-operable patients with altered medical status to slow down tumor growth [76].

One of the main problems related to aggressive meningioma research is the low frequency of the disease, the lack of control treatment, and the heterogeneity of the tumors and treated patients, leading to difficulties in setting up clinical trials as well as in the analysis of results with different PFS6 for the same drug. Only two randomized clinical trials were performed and have confirmed the lack of activity of megestrol acetate and more recently, the antisarcomatous agent, trabectedin [67, 77].

4. New currently available therapies for high-grade multi-recurrent meningiomas, ongoing clinical trials and future perspectives

4.1. Radiation therapy

4.1.1. What is new on meningiomas?

Radiation therapy is currently the reference treatment in aggressive meningiomas complementary to surgery for all WHO grade 3 meningiomas and WHO grade 2 meningiomas with postoperative residue [78]. One question remains: how do we better determine the radiation therapy role in WHO grade 2 meningiomas? Systematically in postoperative period or at recurrence? Current trials with radiation therapy in WHO grade 2 meningiomas are ongoing, but more than the benefit of radiation therapy on recurrence, the main challenge to determine patients who need radiation therapy remains [79, 80].

ROAM/EORTC 1308, ISRCTN71502099 Therefore, determination of the risk factors for meningioma recurrence needs to be improved. PET of SSTR ligands could also be proposed to improve the quality of the surgical resection assessment and improve the Simpson scale grading [81]. By identifying postoperative residues, PET may help to determine complementary radiation therapy indication [49]. Keeping in mind the limited spatial resolution of PET (a few millimeters), residues that are less than 1 or 2mm will not be visualized on PET imaging [82]. Moreover, SSTR2A expression should be analyzed on surgical removed tumor and should be considered for PET DOTATOC interpretation (false negative in PET in case of a low or absent SSTR2A expression).

As in all intracranial tumors, intensity modulation radiotherapy (IMRT) including imagery guided radiation therapy becomes the preferred technique to increase conformal treatment and decrease the high dose delivered on the “out-of-field” healthy tissues.

In parallel, the emergence of intracranial stereotactic radiation therapy improves the possibility of reirradiation in meningiomas, which may help in tumor control [83]. These techniques allow delivering very high doses per fraction on the target while sparing the peritumoral tissues. It is also possible to deliver different schedules with different numbers of fractions and different

interfraction times according to the patient's history, the volume of the target, and the proximity of organ at risk. Compared with single fraction treatment, hypofractionated radiotherapy delivering 5 fractions has been reported to decrease complication rates, such as leukoencephalopathy, local toxicity with edema, and epilepsy [84].

Recently, the development of PET DOTATOC could also help to better delineate meningioma, [49] decreasing unnecessary dose levels on clinical target volume (defined as infraclinal involvement) or improving determination of tumor extension and invasiveness for instance in "en plaques" meningiomas.

4.1.2. Proton beam therapy: Indications, interest and limitations, and current knowledge

Proton beam therapy present multiple advantages *versus* classical radiation therapy, which includes providing a lower Gamma particle course in the tissue, and is particularly adapted for skull base lesions [85-87]. Multi-recurrent high-grade meningioma requires multiple iterative radiation therapy sessions in an aleatory time frame. In these situations, proton beam therapy may help in decreasing radiation dose to the healthy tissue while applying a higher dose to the tumor. Nevertheless, literature data is currently limited to assessing its activity and adverse events, particularly the risk of radionecrosis, which remains difficult to predict. Larger trials are required to better determine the indications and efficacy of proton beam therapy *versus* conventional radiation therapy.

4.1.3. Radiosurgery: the latest advancements

In recent years, a number of technical and conceptual changes have occurred. The Perfexion Gamma Knife generation is allowing the treatment of meningiomas located as low as C4 [88]. These new generation machines, fully robotized, have dramatically reduced treatment time. PET DOTATOC is performed frequently before SRS when there is a dilemma on the histological nature. Mask fixation enables the treatment of patients with small meningiomas in spite of large craniotomies but frame are remaining a standard considering meningiomas which are complex and located in critical areas [89]. In large skull base tumors, combined approaches with upfront partial resection followed by SRS is a strategy largely practiced [90]. In skull base meningiomas encasing the optic pathways, hypofractionated radiosurgery (stereotactic radiotherapy) is currently still under evaluation [91-93], although there is no clear evidence in terms of the reduction of the visual risk thanks to fractionation. Radiosurgery has indisputably dramatically changed the safety efficacy of modern neurosurgical management of meningiomas.

4.1.4. Radiation therapy and Radiosurgery in Meningiomas: What about the future?

Dose of radiotherapy

Due to the lack of phase III data, one of the main unknowns in meningioma radiotherapy is the recommended dose level. The molecular alterations, which were recently reported to be associated with the risk of recurrence, could be useful to adapt the dose and guide the radiotherapy. In addition, new technologies are currently available for meningioma treatment with ionizing radiation. Moreover, IMRT treatment using IRM-Linac could provide adaptive radiation therapy to reduce the dose to the healthy tissues and to optimize the dose to the target volume. Monitoring by multiple MRIs during the course of treatment could be one of the future modalities to improve and adapt the necessary dose.

Different radiotherapy modalities

Future treatments could also combine different radiation therapy modalities as external and metabolic radiotherapy for radio-resistant tumor and/or for re-treatment [94].

The carbon ion radiotherapy is one of the future modalities for the treatment of recurrent or aggressive meningiomas allowing an increase in the dose delivered to the target volume while sparing the organ at risk. Phase II clinical trials are ongoing ([NCT01166321](#)).

The emergence of a new type of radiotherapy, flash radiotherapy, could be the next tool for preoperative reirradiation in delivering a very high dose with a very fast debit. These techniques are still in preclinical research but future phases I and II will soon be started for extra nervous system tumors.

4.2. Peptide receptor radionuclide therapy

4.2.1. Current knowledge

Peptide receptor radionuclide therapy (PRRT) relies on the administration of radioactive drugs that target specific receptors. As octreotide-everolimus combination, PRRT was first developed to treat neuroendocrine tumors (NETs). In NETs, the injected drug targets SSTR2A, and is bound to a radioactive agent, most often lutetium-177. PRRT is currently used in clinical practice to treat NETs, after several studies proving its effectiveness [95]. Interestingly, meningiomas strongly express SSTR2A regardless of the WHO grade [43, 45-47], and similar dose protocols were applied for progressive refractory meningiomas i.e., without further surgical or external radiotherapy treatment options.

PRRT obviously requests high tumor SSTR2A expression on pre-therapy PET DOTATOC imaging (similar or higher than hepatic uptake). In our experience, PRRT was rarely contraindicated because of insufficient PET DOTATOC uptake. Several retrospective studies and trials have been performed to analyze PRRT efficacy in meningiomas [96-104]. Data analysis remains complex; however, it was clear that PFS6 at 6 months is close to 0%, highlighting an insufficient

activity in WHO grade 3 meningiomas [105]. In contrast, in WHO grade 2 meningiomas with reasonable growth rate, PRRT seems to be of interest. In France, ¹⁷⁷Lu-DOTATATE (Lutathera[®], Novartis, Switzerland) is mostly used PRRT to treat meningiomas (. Currently, the protocol is limited to 4 cycles of 7.4 GBq of Lutathera[®] every 8 weeks because of potential hematological toxicity. Myelodysplastic syndrome (MDS) or acute leukemia (AL) have been observed after treatment and occur in an average of 30 and 60 months, respectively, after the first cycle. Both are difficult to predict but certain risk factors have been identified that may increase the likelihood of developing hematotoxicity, such as age or previous systemic therapy. Today, the selection of PRRT indications should therefore integrate the risk of MDS and AL and the treatment of young patients with benign meningiomas and who likely have long-term survival should be avoided. More safety data are needed.

4.2.2. PRRT: Future perspectives and ongoing clinical trials.

Two clinical trials (NCT03971461 and NCT04082520) are ongoing to evaluate PRRT in refractory meningiomas and will help determine the PRRT antitumoral activity and therefore the best clinical indications.

Another clinical trial (NCT05278208) in pediatric and young adult patients will soon be evaluating the safety and efficacy of ¹⁷⁷Lu-DOTATATE in progressive or recurrent high-grade CNS tumors and meningiomas. These data should help determine the safety of offering PRRT to young patients with NF2-related multiple meningioma.

PRRT targeting SSTR2A remains particularly of interest in meningiomas but drug radioactivity and cell toxicity needs to be stronger in order to accomplish cell apoptosis. In future perspective, higher doses of Lutathera[®] could be considered particularly for the most aggressive meningiomas, but limiting factors are present, such as cytopenia and renal toxicity.

As previously mentioned, PRRT in combination with external radiation therapy could be an option to increase the applied dose to the tumor [94].

Targeted alpha particle therapy has emerged as an alternative for PRRT to beta emitters such as lutetium-177. The use of alpha emitters for cancer treatment has two advantages over beta emitter PRRT: a short range of alpha particles sparing surrounding healthy tissue, and a higher linear energy transfer to break DNA double strand. Another promising approach is the use of a radiosensitizing agent in combination with PRRT. Both approaches could be a very interesting prospect for meningiomas, but published data on their safety and efficacy are still limited.

4.3. Targeted therapy

4.3.1. Current active drugs

Today, anti-VEGF and mTOR inhibitors are the most used drugs in clinical practices for multi-recurrent high-grade meningiomas in case of surgery and radiation therapy failure with a progressing tumor and despite the lack of strong literature evidence (Table 1). Bevacizumab and octreotide-everolimus combination are currently the most prescribed drugs in France for aggressive meningiomas [106].

Anti-VEGF drugs (bevacizumab and sunitinib) are currently largely prescribed, providing variable PFS6 but seem to improve PFS6 [106-110]. Moreover, these anti-VEGF drugs could be helpful in case of tumor-associated radionecrosis phenomenon, which is classical after multiple sessions of radiation therapy [111]. Anti-VEGF agents are currently the most active drugs in very aggressive WHO grade 3 meningiomas. Adverse events are now well-known.

Brain hemorrhages were reported as adverse events under sunitinib and bevacizumab [108, 109].

Recently, we demonstrated that the combination of mTOR inhibitor everolimus and the somatostatin agonist octreotide was active in aggressive meningiomas. This drug combination was initially set up for neuroendocrine tumors, then tested in meningiomas. It was found that this co-targeting therapy decreased *in vitro* meningioma cell viability and proliferation, but also clinically, via the CEVOREM clinical trial, has been shown to improve the PFS6 and induce a tumor stabilization/growth rate slowdown [30, 112, 113]. Twenty patients were included in the study and the drug combination was well-tolerated. PFS6 was at 55%; the response, as defined by the RANO criteria, was rare, but tumor volume growth rate stabilization was observed in 75% of tumors. Everolimus and bevacizumab were combined in 5, 7, and 4 WHO grades 1, 2, and 3 meningiomas, respectively, providing an interesting PFS6 at 69% [114]. Nevertheless, the interest to combine both drugs remains uncertain despite acceptable clinical tolerance.

The recently discovered mutations, *AKT1*, *SMO*, and *PI3KCA* are potentially targetable. Nevertheless, literature data on these targeted therapies in meningiomas are scarce, confirming that these mutations, which are mostly observed in low-grade meningiomas, have a limited clinical impact. Nevertheless, tumor genomic analysis should be recommended in aggressive meningioma, particularly when arising from the skull base because a case-by-case tailored targeted therapy could provide a clinical benefit [115].

4.3.2. How to improve drug activity assessment ?

Drug activity assessment remains difficult in meningiomas because of the rarity of clinical trials, particularly randomized clinical trials, patient population heterogeneity (3 different

WHO grades with various aggressiveness patterns, growth rates, and heterogeneity of genomic profiling), and the lack of drug response. PFS6, which is based on the Mac Donald or RANO criteria, remains the most consensual criteria to assess drug activity in meningioma. Kaley *et al.* determined PFS6 thresholds, which are useful in setting up clinical trials or in the analysis of a retrospective series [116]. To improve the drug response assessment and the drug activity analysis, we recently proposed a drug response classification based on 3D volume enlarging the definition of response (as a decrease in volume $\geq 25\%$) compared with the RANO criteria (decrease in surface $\geq 50\%$ for partial response) [112, 117]. We defined tumor stabilization as a growth rate of $\leq 10\%/6$ months and a lack of response. We introduced the notion of growth rate slowdown in an aggressive meningioma with a high growth rate ($\geq 30\%/6$ months), which is severely decreased under treatment ($10\% < \text{growth rate} \leq 30\%/6$ months). The antitumoral activity is not enough to get stabilization but probably remains of benefit for the patient given the lack of alternative treatment. This may help in appreciating drug activity better as well as compare drug activity. The added value of this classification needs to be confirmed and validated in further studies.

4.3.3. Targeted therapies: ongoing clinical trials and future perspectives

Multiple clinical trials are ongoing, targeting receptors and numerous transduction signal effectors or cell cycle proteins (Table 2).

In France, the ongoing ALTREM phase 1 clinical trial aims to test the safety of the combination of PI3KCA inhibitor, alpelisib with the ERK inhibitor, trametinib. Both pathways were demonstrated to be hyperactivated in meningioma, and their inhibition *in vitro* decreased cell proliferation and promoted apoptosis [32]. Another MEK 1/2 inhibitor, selumetinib is under investigation in a phase 2 study.

Anti-VEGF drug bevacizumab is currently the most used drug worldwide in aggressive meningiomas. Other tyrosine kinase drugs are currently under investigation. Anti-VEGF drugs vatalanib and sunitinib were previously tested, with PFS6 at 64% and 37.5% in WHO grade 2 and grade 3 meningiomas, respectively, under Vatalanib, and 42% in WHO grades 2–3 under sunitinib, showing probable antitumoral activities (Table 1) [109, 118]. VEGFR-2 inhibitor apatinib and other tyrosine kinase inhibitors such as dasatinib and afatinib are currently investigated in ongoing trials.

MTOR currently appears as one of the most relevant targets in meningiomas. Clinical trials testing the dual inhibitor of mTORC1–mTORC2, vistusertib are currently ongoing (NCT03071874 and NCT02831257) and will probably help to better define and predict the activity of mTOR inhibitors in meningiomas. PI3K and Akt could also be targeted. GSK3, which interacts with the Pi3K-Akt-mTOR pathway, could be targeted by 9-ING-41.

Tailored targeted therapies based on tumor mutations are promising perspectives in meningioma even though *NF2* remains the most frequent genomic alteration to target. Umbrella trials are currently ongoing targeting various mutations, such as *SMO* mutation with *SMO* inhibitor vismodegib, *Akt* mutation with AKT inhibitor capivasertib, *CDKN2A* alterations with CDK4/6 inhibitors, and *NF2* mutations with FAK inhibitor GSK2256098. FAK inhibitor trial results highlight a PFS6 at 83% in 12 *NF2*-mutated WHO grade 1 meningiomas and a PFS6 at 33% in 24 *NF2*-mutated WHO grade 2–3 meningiomas [119].

Recent studies strongly suggest to target cell cycle proteins in most aggressive meningiomas named “hypermitotic” by Choudhury *et al.* [26, 120]. Trials with CDK4/6 inhibitors, ribociclib and abemaciclib are ongoing [121]. The best indications remain to be defined.

Moreover, the most effective combinations of targeted therapies need to be determined for a stronger and synergic antitumoral effect and optimizing drugs tolerance.

Dopamine receptor D2DR is variously expressed in meningioma [51, 52]. The impact of D2DR activation on meningioma proliferation remains unknown. A phase 1 clinical trial targeting D2DR with ONC 206 is ongoing.

In 2023, the challenge remains to find out the most effective combinations among all these targeted therapies to obtain the stronger antitumoral effect activity with a clinically acceptable drug tolerance thanks to the synergistic effect of the combined drugs.

4.3.4. How to target *NF2* mutation ?

NF2 remains the most frequent driver mutation in aggressive meningiomas [19]. Targeting Merlin and its interactors is one of the most important challenges in meningioma therapeutics research. *NF2* mutation was demonstrated to be related to mTOR activation in meningiomas suggesting targeting the mTOR pathway [27]. FAK inhibitors are currently tested in *NF2*-mutated meningiomas. FAK inhibitors (GSK2256098) aim to inhibit cell progression and mobility, induced by the lack of Merlin as previously mentioned [119]. The Hippo pathway could also be an interesting pathway to be targeted in meningioma. *NF2* interacts through LATS phosphorylation with the Hippo pathway; YAP1 was demonstrated to be highly expressed in meningiomas, showing YAP-TEAD complex inhibitors as a putative relevant therapy [40]. Previous studies on *NF2*-mutated mesotheliomas *in vitro* are promising [42]. Some *in vitro* data showed the effect of the YAP/TEAD complex inhibitor in meningioma cell lines [39]. Currently, a phase 1 study testing IAG933 on *NF2*-mutated tumors as meningiomas is ongoing (NCT04857372).

4.4. Immunotherapy

Despite the important recent advances to understand the immune landscape of meningioma, clinical applications remain limited but promising.

Dunn *et al.* reported a long-term remission in a patient with a recurrent high-grade meningioma under nivolumab. His tumor harbored an MSH2 mutation leading to a high tumor mutational burden (TMB) particularly relevant for immunotherapy [23]. Another patient with high TMB presented a long-term PFS reinforcing the use of TMB to predict immunotherapy activity in meningiomas. In this trial, other patients treated with nivolumab presented a poor outcome with a lack of efficacy of nivolumab [122]. Another anti-PD-1 drug, pembrolizumab, was tested in high-grade meningiomas (3 WHO grade 3 meningiomas and 23 WHO grade 2 meningiomas) in a phase 2 clinical trial. Among the 26 patients included, 15 harbored a progressive disease and 11 a postoperative residual tumor [123]. PFS6 was at 48%. Tumor growth rate was stabilized in 6/15 progressive patients with stable disease with a lack of response based on the RANO criteria. No obvious benefit of previous RT was observed. Correlation with PD-L1 expression was not observed. In contrast, the results were interesting in extracranial disease extension [123]. One perspective to improve immunotherapy efficacy is to increase TMB. Concomitant or prevalent radiation therapy could be a promising option to increase TMB and improve immunotherapy activity.

Therefore, based on the lack of antitumoral activity of Anti-PD-1 agents alone, multiple trials are currently testing the combination of different radiation therapy modalities (proton beam therapy, radiosurgery, and conventional RT) with various immunotherapy drugs, including pembrolizumab (anti-PD-1) and nivolumab (anti-PD-1) alone or in association with ipilimumab (anti-CTLA4). CTLA-4 was shown to be expressed in meningiomas [58]. It will be

of great interest to analyze the results of these studies and determine the benefit brought about by the combination with immunotherapy *versus* radiation therapy alone.

At a longer term, CAR T-cell therapy may offer a promising perspective in meningioma [124]. Furthermore, a better knowledge of meningioma immune landscape will probably help to determine the best immune target and therefore the best therapeutic strategy.

4.5. Surgical improvement and innovations

Unfortunately, surgical advances in the last 20 years are not multiple and major. The development of neuronavigation techniques, which could be implemented with TEP DOTATOC, with intraoperative CT scan or MRI may improve the quality of resection and safety but does not really modify the limits of the surgery, particularly in aggressive and/or invasive meningiomas. An imaging agent inducing fluorescence, 5-Aminolevulinic Acid (ALA) Gleolan TM is currently tested in a phase 3 study in the surgical resection of meningioma (NCT 04305470). Despite a reported benefit in improving glioblastoma removal, 5-ALA interest in meningioma remains unknown [125] .

Different studies have been performed with brachytherapy and variable results.

Brachytherapy is performed by applying radioactive agent *in situ* in the operative bed during the surgery to avoid meningioma local recurrence. Iodine 125, which is first used, is replaced today by Cesium 131. The concept of brachytherapy seems particularly relevant in parasagittal meningioma with suspected superior longitudinal sinus invasion [126]. The main problem is the difficulty to analyze the results of such studies given the lack of reliable control. Complication rates seem to be high, particularly the risk of local infection and radionecrosis with in contrast an uncertain antitumoral activity [127, 128]. Nevertheless, in parasagittal area meningioma with superior longitudinal sinus invasion and lack of distant

tumor extension, the concept of brachytherapy remains relevant and deserves further studies.

5. Conclusions

Today, surgery remains the reference treatment for most meningiomas. Therapeutic management of multi-recurrent high-grade meningiomas is still particularly challenging. Bevacizumab and everolimus–octreotide combination are currently the most used and probably the most active drugs with a proved but insufficient antitumoral activity. PRRT is a very promising concept for meningiomas given the strong SSTR2A expression even in high-grade meningiomas. Nevertheless, current PRRT does not provide sufficient antitumoral activity for most aggressive meningiomas. PRRT protocols to increase the dose applied to the tumors while maintaining good clinical tolerance are needed. Advances in understanding meningioma tumorigenesis led to highlight multiple potential therapeutic targets. Many targeted therapies are currently assessed in ongoing trials. But most of the targetable meningioma driver mutations are found in benign meningiomas, limiting their clinical impact. *NF2* remains the main mutation to target FAK and YAP-TEAD inhibitors are promising perspectives. The mTOR-Akt-PI3K pathway is currently the main targeted intracellular signaling pathway in meningiomas. Co-inhibition of signaling pathways could be an option to improve cell proliferation inhibition. Immunotherapy opens new perspectives despite insufficient results of nivolumab and pembrolizumab in monotherapy. Exceptional *MSH2/6* gene mutations should lead to propose nivolumab. Combination with radiation therapy and other checkpoint inhibitors other than PD-1 constitutes promising perspectives.

References

- [1] Ostrom QT, Price M, Neff C, Cioffi G, Waite KA, Kruchko C, et al. CBTRUS Statistical Report: Primary Brain and Other Central Nervous System Tumors Diagnosed in the United States in 2015-2019. *Neuro Oncol* 2022;24(Suppl 5):v1-v95.
- [2] Zouaoui S, Darlix A, Rigau V, Mathieu-Daude H, Bauchet F, Bessaoud F, et al. Descriptive epidemiology of 13,038 newly diagnosed and histologically confirmed meningiomas in France: 2006-2010. *Neurochirurgie* 2018;64(1):15-21.
- [3] Pouchieu C, Gruber A, Berteaud E, Menegon P, Monteil P, Huchet A, et al. Increasing incidence of central nervous system (CNS) tumors (2000-2012): findings from a population based registry in Gironde (France). *BMC Cancer* 2018;18(1):653.
- [4] Baldi I, Engelhardt J, Bonnet C, Bauchet L, Berteaud E, Gruber A, et al. Epidemiology of meningiomas. *Neurochirurgie* 2018;64(1):5-14.
- [5] Recker MJ, Kuo CC, Prasad D, Attwood K, Plunkett RJ. Incidence trends and survival analysis of atypical meningiomas: a population-based study from 2004 to 2018. *J Neurooncol* 2022;160(1):13-22.
- [6] Santacrose A, Walier M, Regis J, Liscak R, Motti E, Lindquist C, et al. Long-term tumor control of benign intracranial meningiomas after radiosurgery in a series of 4565 patients. *Neurosurgery* 2012;70(1):32-9; discussion 9.
- [7] Pollock BE, Stafford SL, Utter A, Giannini C, Schreiner SA. Stereotactic radiosurgery provides equivalent tumor control to Simpson Grade 1 resection for patients with small- to medium-size meningiomas. *Int J Radiat Oncol Biol Phys* 2003;55(4):1000-5.
- [8] Lee CC, Trifiletti DM, Sahgal A, DeSalles A, Fariselli L, Hayashi M, et al. Stereotactic Radiosurgery for Benign (World Health Organization Grade I) Cavernous Sinus Meningiomas- International Stereotactic Radiosurgery Society (ISRS) Practice Guideline: A Systematic Review. *Neurosurgery* 2018;83(6):1128-42.
- [9] Mantziaris G, Pikis S, Bunevicius A, Peker S, Samanci Y, Nabeel AM, et al. Stereotactic radiosurgery for asymptomatic petroclival region meningiomas: a focused analysis from the IMPASSE study. *Acta Neurochir (Wien)* 2022;164(1):273-9.
- [10] Santacrose A, Tuleasca C, Liscak R, Motti E, Lindquist C, Radatz M, et al. Stereotactic Radiosurgery for Benign Cavernous Sinus Meningiomas: A Multicentre Study and Review of the Literature. *Cancers (Basel)* 2022;14(16).
- [11] Corniola MV, Roche PH, Bruneau M, Cavallo LM, Daniel RT, Messerer M, et al. Management of cavernous sinus meningiomas: Consensus statement on behalf of the EANS skull base section. *Brain Spine* 2022;2:100864.
- [12] Louis DN, Perry A, Wesseling P, Brat DJ, Cree IA, Figarella-Branger D, et al. The 2021 WHO Classification of Tumors of the Central Nervous System: a summary. *Neuro Oncol* 2021;23(8):1231-51.
- [13] Tauziède-Espariat A, Parfait B, Besnard A, Lacombe J, Pallud J, Tazi S, et al. Loss of SMARCE1 expression is a specific diagnostic marker of clear cell meningioma: a comprehensive immunophenotypical and molecular analysis. *Brain Pathol* 2018;28(4):466-74.
- [14] Williams EA, Wakimoto H, Shankar GM, Barker FG, 2nd, Brastianos PK, Santagata S, et al. Frequent inactivating mutations of the PBAF complex gene PBRM1 in meningioma with papillary features. *Acta Neuropathol* 2020;140(1):89-93.
- [15] Shankar GM, Abedalthagafi M, Vaubel RA, Merrill PH, Nayyar N, Gill CM, et al. Germline and somatic BAP1 mutations in high-grade rhabdoid meningiomas. *Neuro Oncol* 2017;19(4):535-45.
- [16] Vaubel RA, Chen SG, Raleigh DR, Link MJ, Chicoine MR, Barani I, et al. Meningiomas With Rhabdoid Features Lacking Other Histologic Features of Malignancy: A Study of 44 Cases and Review of the Literature. *J Neuropathol Exp Neurol* 2016;75(1):44-52.
- [17] Sievers P, Hielscher T, Schimpf D, Stichel D, Reuss DE, Berghoff AS, et al. CDKN2A/B homozygous deletion is associated with early recurrence in meningiomas. *Acta Neuropathol* 2020;140(3):409-13.

- [18] Sahm F, Schrimpf D, Olar A, Koelsche C, Reuss D, Bissel J, et al. TERT Promoter Mutations and Risk of Recurrence in Meningioma. *J Natl Cancer Inst* 2016;108(5).
- [19] Bi WL, Greenwald NF, Abedalthagafi M, Wala J, Gibson WJ, Agarwalla PK, et al. Genomic landscape of high-grade meningiomas. *NPJ Genom Med* 2017;2.
- [20] Boetto J, Bielle F, Sanson M, Peyre M, Kalamarides M. SMO mutation status defines a distinct and frequent molecular subgroup in olfactory groove meningiomas. *Neuro Oncol* 2017;19(3):345-51.
- [21] Clark VE, Erson-Omay EZ, Serin A, Yin J, Cotney J, Ozduman K, et al. Genomic analysis of non-NF2 meningiomas reveals mutations in TRAF7, KLF4, AKT1, and SMO. *Science* 2013;339(6123):1077-80.
- [22] Clark VE, Harmanci AS, Bai H, Youngblood MW, Lee TI, Baranoski JF, et al. Recurrent somatic mutations in POLR2A define a distinct subset of meningiomas. *Nat Genet* 2016;48(10):1253-9.
- [23] Dunn IF, Du Z, Touat M, Sisti MB, Wen PY, Umeton R, et al. Mismatch repair deficiency in high-grade meningioma: a rare but recurrent event associated with dramatic immune activation and clinical response to PD-1 blockade. *JCO Precis Oncol* 2018;2018.
- [24] Sahm F, Schrimpf D, Stichel D, Jones DTW, Hielscher T, Schefzyk S, et al. DNA methylation-based classification and grading system for meningioma: a multicentre, retrospective analysis. *Lancet Oncol* 2017;18(5):682-94.
- [25] Nassiri F, Mamatjan Y, Suppiah S, Badhiwala JH, Mansouri S, Karimi S, et al. DNA methylation profiling to predict recurrence risk in meningioma: development and validation of a nomogram to optimize clinical management. *Neuro Oncol* 2019;21(7):901-10.
- [26] Choudhury A, Magill ST, Eaton CD, Prager BC, Chen WC, Cady MA, et al. Meningioma DNA methylation groups identify biological drivers and therapeutic vulnerabilities. *Nat Genet* 2022;54(5):649-59.
- [27] Pachow D, Andrae N, Kliese N, Angenstein F, Stork O, Wilisch-Neumann A, et al. mTORC1 inhibitors suppress meningioma growth in mouse models. *Clin Cancer Res* 2013;19(5):1180-9.
- [28] Johnson MD, O'Connell MJ, Pilcher W, Reeder JE. Fibroblast growth factor receptor-3 expression in meningiomas with stimulation of proliferation by the phosphoinositide 3 kinase-Akt pathway. *J Neurosurg* 2010;112(5):934-9.
- [29] James MF, Han S, Polizzano C, Plotkin SR, Manning BD, Stemmer-Rachamimov AO, et al. NF2/merlin is a novel negative regulator of mTOR complex 1, and activation of mTORC1 is associated with meningioma and schwannoma growth. *Mol Cell Biol* 2009;29(15):4250-61.
- [30] Graillon T, Defilles C, Mohamed A, Lisbonis C, Germanetti AL, Chinot O, et al. Combined treatment by octreotide and everolimus: Octreotide enhances inhibitory effect of everolimus in aggressive meningiomas. *J Neurooncol* 2015;124(1):33-43.
- [31] Graillon T, Romano D, Defilles C, Lisbonis C, Saveanu A, Figarella-Branger D, et al. Pasireotide is more effective than octreotide, alone or combined with everolimus on human meningioma in vitro. *Oncotarget* 2017;8(33):55361-73.
- [32] Mondielli G, Mouguel G, Darriet F, Roche C, Querdray A, Lisbonis C, et al. Co-Targeting MAP Kinase and Pi3K-Akt-mTOR Pathways in Meningioma: Preclinical Study of Alpelisib and Trametinib. *Cancers (Basel)* 2022;14(18).
- [33] Das A, Miller R, Lee P, Holden CA, Lindhorst SM, Jaboin J, et al. A novel component from citrus, ginger, and mushroom family exhibits antitumor activity on human meningioma cells through suppressing the Wnt/beta-catenin signaling pathway. *Tumour Biol* 2015;36(9):7027-34.
- [34] Johnson MD, O'Connell M, Vito F, Bakos RS. Increased STAT-3 and synchronous activation of Raf-1-MEK-1-MAPK, and phosphatidylinositol 3-Kinase-Akt-mTOR pathways in atypical and anaplastic meningiomas. *J Neurooncol* 2009;92(2):129-36.

- [35] Mawrin C, Sasse T, Kirches E, Kropf S, Schneider T, Grimm C, et al. Different activation of mitogen-activated protein kinase and Akt signaling is associated with aggressive phenotype of human meningiomas. *Clin Cancer Res* 2005;11(11):4074-82.
- [36] Wu Y, Li N, Ye C, Jiang X, Luo H, Zhang B, et al. Focal adhesion kinase inhibitors, a heavy punch to cancer. *Discov Oncol* 2021;12(1):52.
- [37] Shapiro IM, Kolev VN, Vidal CM, Kadariya Y, Ring JE, Wright Q, et al. Merlin deficiency predicts FAK inhibitor sensitivity: a synthetic lethal relationship. *Sci Transl Med* 2014;6(237):237ra68.
- [38] Harvey KF, Zhang X, Thomas DM. The Hippo pathway and human cancer. *Nat Rev Cancer* 2013;13(4):246-57.
- [39] Mougel G, Mondielli G, Appay R, Querdray A, Roche C, Jijon A, et al. P18.07.A Hippo signaling pathway is strongly involved in meningioma tumorigenesis. *Neuro-Oncology* 2022;24(Supplement_2):ii95-ii.
- [40] Baia GS, Caballero OL, Orr BA, Lal A, Ho JS, Cowdrey C, et al. Yes-associated protein 1 is activated and functions as an oncogene in meningiomas. *Mol Cancer Res* 2012;10(7):904-13.
- [41] Striedinger K, VandenBerg SR, Baia GS, McDermott MW, Gutmann DH, Lal A. The neurofibromatosis 2 tumor suppressor gene product, merlin, regulates human meningioma cell growth by signaling through YAP. *Neoplasia* 2008;10(11):1204-12.
- [42] Tang TT, Konradi AW, Feng Y, Peng X, Ma M, Li J, et al. Small Molecule Inhibitors of TEAD Auto-palmitoylation Selectively Inhibit Proliferation and Tumor Growth of NF2-deficient Mesothelioma. *Mol Cancer Ther* 2021;20(6):986-98.
- [43] Graillon T, Romano D, Defilles C, Saveanu A, Mohamed A, Figarella-Branger D, et al. Octreotide therapy in meningiomas: in vitro study, clinical correlation, and literature review. *J Neurosurg* 2017;127(3):660-9.
- [44] Silva CB, Ongaratti BR, Trott G, Haag T, Ferreira NP, Leaes CG, et al. Expression of somatostatin receptors (SSTR1-SSTR5) in meningiomas and its clinicopathological significance. *Int J Clin Exp Pathol* 2015;8(10):13185-92.
- [45] Barresi V, Alafaci C, Salpietro F, Tuccari G. Sstr2A immunohistochemical expression in human meningiomas: is there a correlation with the histological grade, proliferation or microvessel density? *Oncol Rep* 2008;20(3):485-92.
- [46] Durand A, Champier J, Jouvet A, Labrousse F, Honnorat J, Guyotat J, et al. Expression of c-Myc, neurofibromatosis Type 2, somatostatin receptor 2 and erb-B2 in human meningiomas: relation to grades or histotypes. *Clin Neuropathol* 2008;27(5):334-45.
- [47] Dutour A, Kumar U, Panetta R, Ouafik L, Fina F, Sasi R, et al. Expression of somatostatin receptor subtypes in human brain tumors. *Int J Cancer* 1998;76(5):620-7.
- [48] Jensen LR, Maier AD, Lomstein A, Graillon T, Hrachova M, Bota D, et al. Somatostatin analogues in treatment-refractory meningioma: a systematic review with meta-analysis of individual patient data. *Neurosurg Rev* 2022;45(5):3067-81.
- [49] Galldiks N, Albert NL, Sommerauer M, Grosu AL, Ganswindt U, Law I, et al. PET imaging in patients with meningioma-report of the RANO/PET Group. *Neuro Oncol* 2017;19(12):1576-87.
- [50] Norden AD, Ligon KL, Hammond SN, Muzikansky A, Reardon DA, Kaley TJ, et al. Phase II study of monthly pasireotide LAR (SOM230C) for recurrent or progressive meningioma. *Neurology* 2015;84(3):280-6.
- [51] Trott G, Pereira-Lima JF, Leaes CG, Ferreira NP, Barbosa-Coutinho LM, Oliveira MC. Abundant immunohistochemical expression of dopamine D2 receptor and p53 protein in meningiomas: follow-up, relation to gender, age, tumor grade, and recurrence. *Braz J Med Biol Res* 2015;48(5):415-9.
- [52] Schrell UM, Fahlbusch R, Adams EF, Nomikos P, Reif M. Growth of cultured human cerebral meningiomas is inhibited by dopaminergic agents. Presence of high affinity dopamine-D1 receptors. *J Clin Endocrinol Metab* 1990;71(6):1669-71.

- [53] Carroll RS, Schrell UM, Zhang J, Dashner K, Nomikos P, Fahlbusch R, et al. Dopamine D1, dopamine D2, and prolactin receptor messenger ribonucleic acid expression by the polymerase chain reaction in human meningiomas. *Neurosurgery* 1996;38(2):367-75.
- [54] Schrell UM, Nomikos P, Fahlbusch R. Presence of dopamine D1 receptors and absence of dopamine D2 receptors in human cerebral meningioma tissue. *J Neurosurg* 1992;77(2):288-94.
- [55] Adams EF, Schrell UM, Fahlbusch R, Thierauf P. Hormonal dependency of cerebral meningiomas. Part 2: In vitro effect of steroids, bromocriptine, and epidermal growth factor on growth of meningiomas. *J Neurosurg* 1990;73(5):750-5.
- [56] Castelo-Branco C, Martinez MJ, Balasch J. Further data favouring hormonal dependency of cerebral meningiomas: evidence from a patient treated with cabergoline. *Gynecol Endocrinol* 2011;27(2):134-7.
- [57] Wang AZ, Bowman-Kirigin JA, Desai R, Kang LI, Patel PR, Patel B, et al. Single-cell profiling of human dura and meningioma reveals cellular meningeal landscape and insights into meningioma immune response. *Genome Med* 2022;14(1):49.
- [58] Proctor DT, Patel Z, Lama S, Resch L, van Marle G, Sutherland GR. Identification of PD-L2, B7-H3 and CTLA-4 immune checkpoint proteins in genetic subtypes of meningioma. *Oncoimmunology* 2019;8(1):e1512943.
- [59] Golub D, Kwan K, Knisely JPS, Schulder M. Possible Abscopal Effect Observed in Frontal Meningioma After Localized IMRT on Posterior Meningioma Resection Cavity Without Adjuvant Immunotherapy. *Front Oncol* 2019;9:1109.
- [60] Han SJ, Reis G, Kohanbash G, Shrivastav S, Magill ST, Molinaro AM, et al. Expression and prognostic impact of immune modulatory molecule PD-L1 in meningioma. *J Neurooncol* 2016;130(3):543-52.
- [61] Karimi S, Mansouri S, Nassiri F, Bunda S, Singh O, Brastianos PK, et al. Clinical significance of checkpoint regulator "Programmed death ligand-1 (PD-L1)" expression in meningioma: review of the current status. *J Neurooncol* 2021;151(3):443-9.
- [62] Hoisnard L, Laanani M, Passeri T, Duranteau L, Coste J, Zureik M, et al. Risk of intracranial meningioma with three potent progestogens: A population-based case-control study. *Eur J Neurol* 2022;29(9):2801-9.
- [63] Graillon T, Boissonneau S, Appay R, Boucekine M, Peyriere H, Meyer M, et al. Meningiomas in patients with long-term exposition to progestins: Characteristics and outcome. *Neurochirurgie* 2021;67(6):556-63.
- [64] Peyre M, Gaillard S, de Marcellus C, Giry M, Bielle F, Villa C, et al. Progestin-associated shift of meningioma mutational landscape. *Ann Oncol* 2018;29(3):681-6.
- [65] Chamberlain MC, Tsao-Wei DD, Groshen S. Temozolomide for treatment-resistant recurrent meningioma. *Neurology* 2004;62(7):1210-2.
- [66] Reardon DA, Norden AD, Desjardins A, Vredenburgh JJ, Herndon JE, 2nd, Coan A, et al. Phase II study of Gleevec(R) plus hydroxyurea (HU) in adults with progressive or recurrent meningioma. *J Neurooncol* 2012;106(2):409-15.
- [67] Preusser M, Silvani A, Rhun EL, Soffietti R, Lombardi G, Sepúlveda JM, et al. Trabectedin for recurrent WHO grade II or III meningioma: A randomized phase II study of the EORTC Brain Tumor Group (EORTC-1320-BTG). *Journal of Clinical Oncology* 2019;37(15_suppl):2007-.
- [68] Norden AD, Raizer JJ, Abrey LE, Lamborn KR, Lassman AB, Chang SM, et al. Phase II trials of erlotinib or gefitinib in patients with recurrent meningioma. *J Neurooncol* 2010;96(2):211-7.
- [69] Chamberlain MC. Hydroxyurea for recurrent surgery and radiation refractory high-grade meningioma. *J Neurooncol* 2012;107(2):315-21.
- [70] Fuentes S, Chinot O, Dufour H, Paz-Paredes A, Metellus P, Barrie-Attarian M, et al. [Hydroxyurea treatment for unresectable meningioma]. *Neurochirurgie* 2004;50(4):461-7.
- [71] Hahn BM, Schrell UM, Sauer R, Fahlbusch R, Ganslandt O, Grabenbauer GG. Prolonged oral hydroxyurea and concurrent 3d-conformal radiation in patients with progressive or recurrent meningioma: results of a pilot study. *J Neurooncol* 2005;74(2):157-65.

- [72] Kim MS, Yu DW, Jung YJ, Kim SW, Chang CH, Kim OL. Long-term follow-up result of hydroxyurea chemotherapy for recurrent meningiomas. *J Korean Neurosurg Soc* 2012;52(6):517-22.
- [73] Mason WP, Gentili F, Macdonald DR, Hariharan S, Cruz CR, Abrey LE. Stabilization of disease progression by hydroxyurea in patients with recurrent or unresectable meningioma. *J Neurosurg* 2002;97(2):341-6.
- [74] Newton HB. Hydroxyurea chemotherapy in the treatment of meningiomas. *Neurosurg Focus* 2007;23(4):E11.
- [75] Schrell UM, Rittig MG, Anders M, Kiesewetter F, Marschalek R, Koch UH, et al. Hydroxyurea for treatment of unresectable and recurrent meningiomas. I. Inhibition of primary human meningioma cells in culture and in meningioma transplants by induction of the apoptotic pathway. *J Neurosurg* 1997;86(5):845-52.
- [76] Graillon T, Tabouret E, Chinot O. Chemotherapy and targeted therapies for meningiomas: what is the evidence? *Curr Opin Neurol* 2021;34(6):857-67.
- [77] Ji Y, Rankin C, Grunberg S, Sherrod AE, Ahmadi J, Townsend JJ, et al. Double-Blind Phase III Randomized Trial of the Antiprogesterin Agent Mifepristone in the Treatment of Unresectable Meningioma: SWOG S9005. *J Clin Oncol* 2015;33(34):4093-8.
- [78] Goldbrunner R, Stavrinou P, Jenkinson MD, Sahm F, Mawrin C, Weber DC, et al. EANO guideline on the diagnosis and management of meningiomas. *Neuro Oncol* 2021.
- [79] Jenkinson MD, Weber DC, Haylock BJ, Sherratt FC, Young B, Weller M, et al. Letter to the Editor. Phase III randomized controlled trials are essential to properly evaluate the role of radiotherapy in WHO grade II meningioma. *J Neurosurg* 2018;129(4):1104-5.
- [80] Jenkinson MD, Javadpour M, Haylock BJ, Young B, Gillard H, Vinten J, et al. The ROAM/EORTC-1308 trial: Radiation versus Observation following surgical resection of Atypical Meningioma: study protocol for a randomised controlled trial. *Trials* 2015;16:519.
- [81] Ueberschaer M, Vettermann FJ, Forbrig R, Unterrainer M, Siller S, Biczok AM, et al. Simpson Grade Revisited - Intraoperative Estimation of the Extent of Resection in Meningiomas Versus Postoperative Somatostatin Receptor Positron Emission Tomography/Computed Tomography and Magnetic Resonance Imaging. *Neurosurgery* 2020;88(1):140-6.
- [82] Salgues B, Graillon T, Guedj E. [(68)Ga]Ga-DOTA-TOC PET/CT fused to MRI in post-operative evaluation of olfactory groove meningioma: a case on millimetric remnants. *Eur J Nucl Med Mol Imaging* 2021;48(1):316-7.
- [83] Navarria P, Pessina F, Cozzi L, Clerici E, Villa E, Ascolese AM, et al. Hypofractionated stereotactic radiation therapy in skull base meningiomas. *J Neurooncol* 2015;124(2):283-9.
- [84] Rogers L, Barani I, Chamberlain M, Kaley TJ, McDermott M, Raizer J, et al. Meningiomas: knowledge base, treatment outcomes, and uncertainties. A RANO review. *J Neurosurg* 2015;122(1):4-23.
- [85] Imber BS, Neal B, Casey DL, Darwish H, Lin AL, Cahlon O, et al. Clinical Outcomes of Recurrent Intracranial Meningiomas Treated with Proton Beam Reirradiation. *Int J Part Ther* 2019;5(4):11-22.
- [86] Graillon T, Regis J, Barlier A, Brue T, Dufour H, Buchfelder M. Parasellar Meningiomas. *Neuroendocrinology* 2020.
- [87] Noel G, Gondi V. Proton therapy for tumors of the base of the skull. *Chin Clin Oncol* 2016;5(4):51.
- [88] Regis J, Tamura M, Guillot C, Yomo S, Muraciotte X, Nagaje M, et al. Radiosurgery with the world's first fully robotized Leksell Gamma Knife PerfeXion in clinical use: a 200-patient prospective, randomized, controlled comparison with the Gamma Knife 4C. *Neurosurgery* 2009;64(2):346-55; discussion 55-6.
- [89] Regis J, Merly L, Balossier A, Baumstarck K, Hamdi H, Mariani S, et al. Mask-Based versus Frame-Based Gamma Knife ICON Radiosurgery in Brain Metastases: A Prospective Randomized Trial. *Stereotact Funct Neurosurg* 2022;100(2):86-94.

- [90] Fu J, Zeng J, Huang M, Liang S, He Y, Xie L, et al. Primary versus postoperative gamma knife radiosurgery for intracranial benign meningiomas: a matched cohort retrospective study. *BMC Cancer* 2022;22(1):206.
- [91] Barone F, Inserra F, Scalia G, Ippolito M, Cosentino S, Crea A, et al. (68)Ga-DOTATOC PET/CT Follow Up after Single or Hypofractionated Gamma Knife ICON Radiosurgery for Meningioma Patients. *Brain Sci* 2021;11(3).
- [92] Pinzi V, Marchetti M, Viola A, Tramacere I, Cane I, Iezzoni C, et al. Hypofractionated Radiosurgery for Large or in Critical-Site Intracranial Meningioma: Results of a Phase 2 Prospective Study. *Int J Radiat Oncol Biol Phys* 2023;115(1):153-63.
- [93] Han J, Girvigian MR, Chen JC, Miller MJ, Lodin K, Rahimian J, et al. A comparative study of stereotactic radiosurgery, hypofractionated, and fractionated stereotactic radiotherapy in the treatment of skull base meningioma. *Am J Clin Oncol* 2014;37(3):255-60.
- [94] Hartrampf PE, Hanscheid H, Kertels O, Schirbel A, Kreissl MC, Flentje M, et al. Long-term results of multimodal peptide receptor radionuclide therapy and fractionated external beam radiotherapy for treatment of advanced symptomatic meningioma. *Clin Transl Radiat Oncol* 2020;22:29-32.
- [95] Strosberg J, Leeuwenkamp O, Siddiqui MK. Peptide receptor radiotherapy re-treatment in patients with progressive neuroendocrine tumors: A systematic review and meta-analysis. *Cancer Treat Rev* 2021;93:102141.
- [96] Minutoli F, Amato E, Sindoni A, Cardile D, Conti A, Herberg A, et al. Peptide receptor radionuclide therapy in patients with inoperable meningiomas: our experience and review of the literature. *Cancer Biother Radiopharm* 2014;29(5):193-9.
- [97] Marincek N, Radojewski P, Dumont RA, Brunner P, Muller-Brand J, Maecke HR, et al. Somatostatin receptor-targeted radiopeptide therapy with 90Y-DOTATOC and 177Lu-DOTATOC in progressive meningioma: long-term results of a phase II clinical trial. *J Nucl Med* 2015;56(2):171-6.
- [98] van Essen M, Krenning EP, Kooij PP, Bakker WH, Feelders RA, de Herder WW, et al. Effects of therapy with [177Lu-DOTA0, Tyr3]octreotate in patients with paraganglioma, meningioma, small cell lung carcinoma, and melanoma. *J Nucl Med* 2006;47(10):1599-606.
- [99] Seystahl K, Stoecklein V, Schuller U, Rushing E, Nicolas G, Schafer N, et al. Somatostatin receptor-targeted radionuclide therapy for progressive meningioma: benefit linked to 68Ga-DOTATATE/-TOC uptake. *Neuro Oncol* 2016;18(11):1538-47.
- [100] Gerster-Gillieron K, Forrer F, Maecke H, Mueller-Brand J, Merlo A, Cordier D. 90Y-DOTATOC as a Therapeutic Option for Complex Recurrent or Progressive Meningiomas. *J Nucl Med* 2015;56(11):1748-51.
- [101] Muther M, Roll W, Brokinkel B, Zinnhardt B, Sporns PB, Seifert R, et al. Response assessment of somatostatin receptor targeted radioligand therapies for progressive intracranial meningioma. *Nuklearmedizin* 2020;59(5):348-55.
- [102] Salgues B, Graillon T, Horowitz T, Chinot O, Padovani L, Taieb D, et al. Somatostatin Receptor Theranostics for Refractory Meningiomas. *Curr Oncol* 2022;29(8):5550-65.
- [103] Bartolomei M, Bodei L, De Cicco C, Grana CM, Cremonesi M, Botteri E, et al. Peptide receptor radionuclide therapy with (90)Y-DOTATOC in recurrent meningioma. *Eur J Nucl Med Mol Imaging* 2009;36(9):1407-16.
- [104] Parghane RV, Talole S, Basu S. Prevalence of hitherto unknown brain meningioma detected on (68)Ga-DOTATATE positron-emission tomography/computed tomography in patients with metastatic neuroendocrine tumor and exploring potential of (177)Lu-DOTATATE peptide receptor radionuclide therapy as single-shot treatment approach targeting both tumors. *World J Nucl Med* 2019;18(2):160-70.
- [105] Mirian C, Duun-Henriksen AK, Maier A, Pedersen MM, Jensen LR, Bashir A, et al. Somatostatin Receptor-Targeted Radiopeptide Therapy in Treatment-Refractory Meningioma: Individual Patient Data Meta-analysis. *J Nucl Med* 2021;62(4):507-13.

- [106] Le Van T, Graillon T, Jacob J, Vauleon E, Feuvret L, Boch AL, et al. Multimodal management of surgery- and radiation-refractory meningiomas: an analysis of the French national tumor board meeting on meningiomas cohort. *J Neurooncol* 2021;153(1):55-64.
- [107] Lou E, Sumrall AL, Turner S, Peters KB, Desjardins A, Vredenburgh JJ, et al. Bevacizumab therapy for adults with recurrent/progressive meningioma: a retrospective series. *J Neurooncol* 2012;109(1):63-70.
- [108] Nayak L, Iwamoto FM, Rudnick JD, Norden AD, Lee EQ, Drappatz J, et al. Atypical and anaplastic meningiomas treated with bevacizumab. *J Neurooncol* 2012;109(1):187-93.
- [109] Kaley TJ, Wen P, Schiff D, Ligon K, Haidar S, Karimi S, et al. Phase II trial of sunitinib for recurrent and progressive atypical and anaplastic meningioma. *Neuro Oncol* 2015;17(1):116-21.
- [110] Cardona AF, Ruiz-Patino A, Zatarain-Barron ZL, Hakim F, Jimenez E, Mejia JA, et al. Systemic management of malignant meningiomas: A comparative survival and molecular marker analysis between Octreotide in combination with Everolimus and Sunitinib. *PLoS One* 2019;14(6):e0217340.
- [111] Bostrom JP, Seifert M, Greschus S, Schafer N, Glas M, Lammering G, et al. Bevacizumab treatment in malignant meningioma with additional radiation necrosis. An MRI diffusion and perfusion case study. *Strahlenther Onkol* 2014;190(4):416-21.
- [112] Graillon T, Ferrer L, Siffre J, Sanson M, Peyre M, Peyriere H, et al. Role of 3-D volume growth rate for drug activity evaluation in meningioma clinical trials: the example of the CEVOREM study. *Neuro Oncol* 2021.
- [113] Graillon T, Sanson M, Campello C, Idbaih A, Peyre M, Peyriere H, et al. Everolimus and Octreotide for Patients with Recurrent Meningioma: Results from the Phase II CEVOREM Trial. *Clin Cancer Res* 2020.
- [114] Shih KC, Chowdhary S, Rosenblatt P, Weir AB, 3rd, Shepard GC, Williams JT, et al. A phase II trial of bevacizumab and everolimus as treatment for patients with refractory, progressive intracranial meningioma. *J Neurooncol* 2016;129(2):281-8.
- [115] Weller M, Roth P, Sahm F, Burghardt I, Schuknecht B, Rushing EJ, et al. Durable Control of Metastatic AKT1-Mutant WHO Grade 1 Meningothelial Meningioma by the AKT Inhibitor, AZD5363. *J Natl Cancer Inst* 2017;109(3):1-4.
- [116] Kaley T, Barani I, Chamberlain M, McDermott M, Panageas K, Raizer J, et al. Historical benchmarks for medical therapy trials in surgery- and radiation-refractory meningioma: a RANO review. *Neuro Oncol* 2014;16(6):829-40.
- [117] Huang RY, Bi WL, Weller M, Kaley T, Blakeley J, Dunn I, et al. Proposed response assessment and endpoints for meningioma clinical trials: report from the Response Assessment in Neuro-Oncology Working Group. *Neuro Oncol* 2019;21(1):26-36.
- [118] Raizer JJ, Grimm SA, Rademaker A, Chandler JP, Muro K, Helenowski I, et al. A phase II trial of PTK787/ZK 222584 in recurrent or progressive radiation and surgery refractory meningiomas. *J Neurooncol* 2014;117(1):93-101.
- [119] Brastianos PK, Twohy EL, Gerstner ER, Kaufmann TJ, Iafrate AJ, Lennerz J, et al. Alliance A071401: Phase II Trial of Focal Adhesion Kinase Inhibition in Meningiomas With Somatic NF2 Mutations. *J Clin Oncol* 2023;41(3):618-28.
- [120] Choudhury A, Chen WC, Lucas CG, Bayley JC, Harmanci AS, Maas SLN, et al. Hypermitotic meningiomas harbor DNA methylation subgroups with distinct biological and clinical features. *Neuro Oncol* 2022.
- [121] Young JS, Kidwell RL, Zheng A, Haddad AF, Aghi MK, Raleigh DR, et al. CDK 4/6 inhibitors for the treatment of meningioma. *Front Oncol* 2022;12:931371.
- [122] Bi WL, Nayak L, Meredith DM, Driver J, Du Z, Hoffman S, et al. Activity of PD-1 blockade with Nivolumab among patients with recurrent atypical/anaplastic meningioma: Phase II trial results. *Neuro Oncol* 2021.

- [123] Brastianos PK, Kim AE, Giobbie-Hurder A, Lee EQ, Wang N, Eichler AF, et al. Phase 2 study of pembrolizumab in patients with recurrent and residual high-grade meningiomas. *Nat Commun* 2022;13(1):1325.
- [124] Garzon-Muvdi T, Bailey DD, Pernik MN, Pan E. Basis for Immunotherapy for Treatment of Meningiomas. *Front Neurol* 2020;11:945.
- [125] Gerritsen JKW, Broekman MLD, De Vleeschouwer S, Schucht P, Nahed BV, Berger MS, et al. Safe surgery for glioblastoma: Recent advances and modern challenges. *Neurooncol Pract* 2022;9(5):364-79.
- [126] Mooney MA, Bi WL, Cantalino JM, Wu KC, Harris TC, Possatti LL, et al. Brachytherapy with surgical resection as salvage treatment for recurrent high-grade meningiomas: a matched cohort study. *J Neurooncol* 2020;146(1):111-20.
- [127] Magill ST, Schwartz TH, Theodosopoulos PV, McDermott MW. Brachytherapy for meningiomas. *Handb Clin Neurol* 2020;170:303-7.
- [128] Koch MJ, Agarwalla PK, Royce TJ, Shih HA, Oh K, Niemierko A, et al. Brachytherapy as an Adjuvant for Recurrent Atypical and Malignant Meningiomas. *Neurosurgery* 2019;85(5):E910-E6.

Table 1: Selected targeted therapy clinical trials in meningiomas with available PFS6, for the last 10 years.

Table 2: Ongoing clinical trials for adult patients with aggressive meningiomas.

Figure 1: Current and potential therapeutic targets in meningioma.

Figure 1

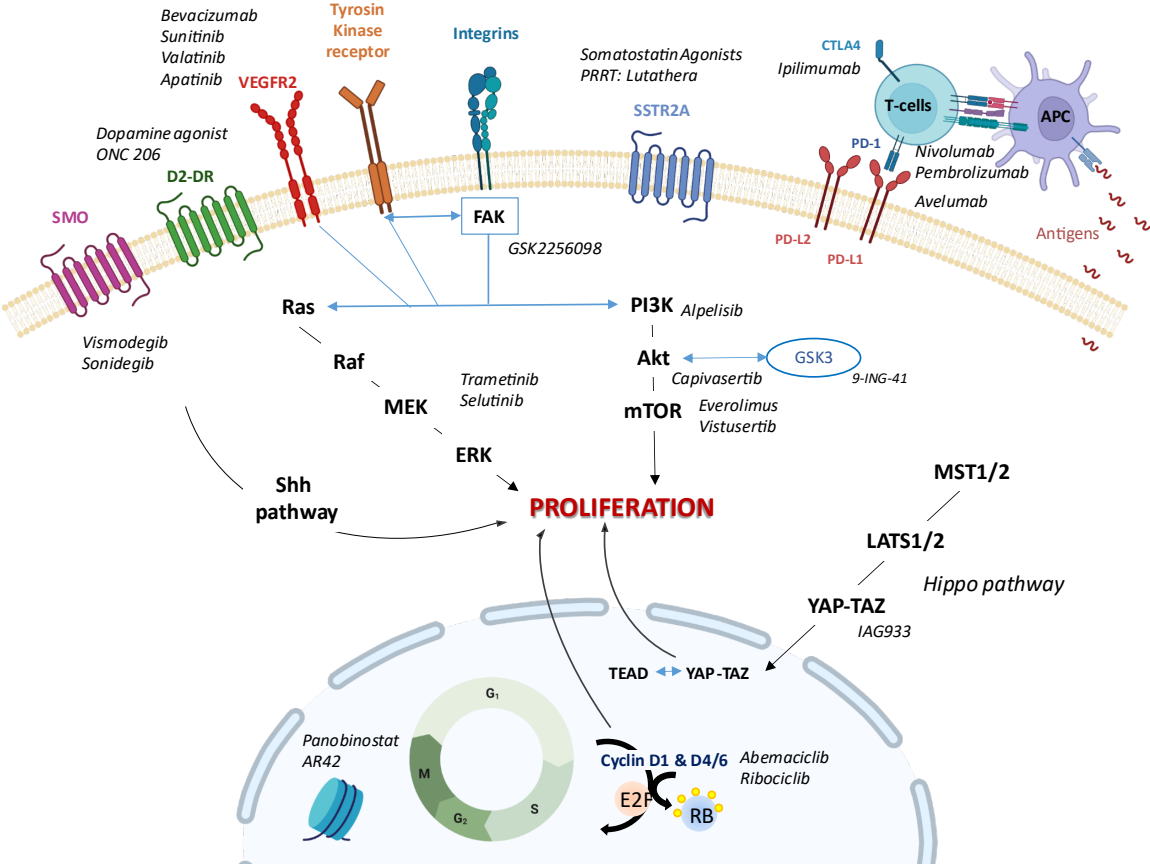


Table 1

Drugs	Class	Author and Year	Included population	Phase	Patient number	PFS6
Bevacizumab	Monoclonal anti-VEGF Antibody	Nayak <i>et al.</i> , 2012	WHO grade 2–3 meningioma	Retrospective case series	n=15 6 WHO 2 9 WHO 3	43.8%
		Lou <i>et al.</i> , 2012	Recurrent WHO grade 1–3 meningioma	Retrospective case series	n=14 5 WHO 1 5 WHO 2 1 WHO 3	86%
		Preusser <i>et al.</i> , 2022	Recurrent WHO grade 2–3 meningioma	Phase 2 unplanned post-hoc analysis	n=9 NA	44.4%
		Kumthekar <i>et al.</i> , 2022	Recurrent WHO grade 1–3 meningioma	Phase 2	n=42 10 WHO 1 20 WHO 2 12 WHO 3	WHO 1: 93% WHO 2-3: 66%
Vatalanib	Multi-tyrosine kinase inhibitor (VEGFR, PDGFR, c-kit)	Raizer <i>et al.</i> , 2014	Recurrent refractory WHO grade 1–3 meningioma	Phase 2	n=25 2 WHO 1 14 WHO 2 8 WHO 3	WHO 2: 64.3% WHO 3: 37.5%
Sunitinib	Multi-tyrosine kinase inhibitor (VEGFR, PDGFR)	Kaley <i>et al.</i> , 2015	Recurrent WHO grade 2-3 meningioma	Phase 2	n=36 30 WHO 2 6 WHO 3	42%
Bevacizumab + Everolimus	Monoclonal anti-VEGF antibody + mTOR inhibitor	Shih <i>et al.</i> , 2016	Recurrent WHO grade 1–3 meningioma	Phase 2	n=17 5 WHO 1 7 WHO 2 4 WHO 3	69%
Octreotide + Everolimus	Somatostatin analog + mTOR inhibitor	Graillon <i>et al.</i> , 2020	Recurrent WHO grade 1–3 meningioma	Phase 2	n=20 2 WHO 1 10 WHO 2 8 WHO 3	55%
Vistusertib	mTORC1-2 inhibitor	Plotkin <i>et al.</i> , 2021	Progressive or recurrent grade II/III meningiomas	Phase 2	n=28 NA	51.5%
		Plotkin <i>et al.</i> , 2022	NF2 patients with progressive or symptomatic meningiomas	Phase 2	n=18 NA	88.9%
Trabectedin	Cytotoxic agent	Preusser <i>et al.</i> ,	Recurrent WHO grade 2-3 meningioma	Phase 3	n=90 55 WHO 2 35 WHO 3	Arm Trabectedin: 21.1% Arm local standard of care: 29.1%
GSK2256098	FAK inhibitors	Brastianos <i>et al.</i> , 2023	NF2-mutated Recurrent or progressive WHO grade 1–3 meningioma	Phase 2	n=36 2 WHO 1 24 WHO 2-3	WHO 1: 83% WHO 2-3: 33%
Nivolumab	Monoclonal anti-PD-1 antibody	Bi <i>et al.</i> , 2022	Recurrent and progressive WHO grade 2–3 meningioma	Phase 2	n=25 18 WHO 2 7 WHO 3	42.4%
Pembrolizumab	Monoclonal anti-PD-1 antibody	Brastianos <i>et al.</i> , 2022	Recurrent and progressive WHO grade 2–3 meningioma	Phase 2	n=25 22 WHO 2 3 WHO 3	48%

Table 1: Selected targeted therapy clinical trials in meningiomas with available PFS6, for the last 10 years.

Table 2

Treatment	Target	Phase	NCT Number	Country
Targeted therapy				
Vistusertib (AZD2014)	mTOR	2	03071874	USA
Alpelisib + Trametinib	Pi3K & MEK	1	03631953	France
Apatinib	VEGFR-2	NA	04501705	China
Ribociclib	CDK 4/6 Cyclin D1	1	02933736	USA
AR-42	Histone deacetylase	2/3	05130866	NA
Panobitostat+Stereotactic RT	Histone deacetylase	1	01324635	USA
Cabozantinib	MultiTKR and VEGFR-2	2	05425004	USA
9-ING-41 & Irinotecan	GSK3	1	04239092	USA
Brigatinib	TKR	2	04374305	USA
Selumetinib	MEK1-2	2	03095248	USA

ONC206	D2DR	1	04541082	USA
Ribociclib + Trametinib (Stratum B)	CDK 4/6			
	CyclinD1 & MEK1-2	1	03434262	USA
Visomedgib Or GSK2256098 Or Capivasertib Or Abemaciclib	SMO/SHH			
	FAK	2	02523014	USA
	AKT			
	CDK 4/6			
Abemaciclib	CDK 4/6	2	03220646	USA
Afatinib	TKR	1	02423525	USA
NEO100	CDK pathway	2	05023018	NA
IAG933	Hippo pathway	1	04857372	NA
PRRT				
Lutathera	SSTR2A	1	04997317	Switzerland
Lutathera	SSTR2A	2	04082520	USA
Lutathera	SSTR2A	1/2	05278208	USA
Lutathera	SSTR2A	2	039711461	USA

Immunotherapy (alone and combined)				
Cohort 1 : Nivolumab	PD-1			
Cohort 2 : EBRT then Nivolumab+ Ipilimumab	PD-1 and CTLA4	2	02648997	USA
Pembrolizumab	PD-1	2	03279692	USA
Sintilimab	PD-1	NA	04728568	China
Avelumab + Proton beam therapy	PD-L1	1	03267836	USA
Nivolumab+Stereotactic multifraction SRS or Nivolumab+Ipilimumab+ multifractionned SRS	PD-1 or PD-1 and CTLA4	1/2	03604978	USA
Pembrolizumab + SRS	PD-1	2	04659811	USA
Nivolumab	PD-1	2	03173950	USA