



**HAL**  
open science

## Interest of eye movement study in early diagnosis of posterior cortical atrophy: A case-report

G. Pin, C. Trompette, M. Ceccaldi, O. Felician, L. Koric

### ► To cite this version:

G. Pin, C. Trompette, M. Ceccaldi, O. Felician, L. Koric. Interest of eye movement study in early diagnosis of posterior cortical atrophy: A case-report. *Revue Neurologique*, 2023, 179 (3), pp.246-248. 10.1016/j.neurol.2022.10.007 . hal-04415637

**HAL Id: hal-04415637**

**<https://cnrs.hal.science/hal-04415637>**

Submitted on 15 Apr 2024

**HAL** is a multi-disciplinary open access archive for the deposit and dissemination of scientific research documents, whether they are published or not. The documents may come from teaching and research institutions in France or abroad, or from public or private research centers.

L'archive ouverte pluridisciplinaire **HAL**, est destinée au dépôt et à la diffusion de documents scientifiques de niveau recherche, publiés ou non, émanant des établissements d'enseignement et de recherche français ou étrangers, des laboratoires publics ou privés.

## Letter to the editor

### Interest of Eye Movement Study in early diagnosis of Posterior Cortical Atrophy: A case-report

We report the case of M.A, a 64 years old male who was referred to our memory clinic for word finding and concentration difficulties. These complaints started seven years ago in a context of low mood and had worsened over time. At that time, he did not have any significant medical history and did not take any medication. He had no family history of neurodegenerative disease but his sister was followed for a Major Depressive Disorder. His level of autonomy was maintained. However, his wife noticed spatial disorientation while crossing the street or driving. A neuropsychological assessment showed mild executive disorders and attentional fluctuations (Fig.1A) Visuo-perceptive and visuospatial tests were normal as well as complete neurological examination. Further explorations including brain MRI and standard blood tests were without particularity. Therefore, the diagnosis of Mild Cognitive Impairment related to mood disorder was initially considered. However, taking in consideration his wife's complaints, the eye movement study using a Video-Oculo-Graphy (VOG) was undertaken (Fig.1B). The important increase of horizontal prosaccades latencies was found in both directions. Saccadic velocity and gain were normal in both horizontal and vertical directions. Suggesting a possible posterior parietal dysfunction, those results led to further investigations such as:

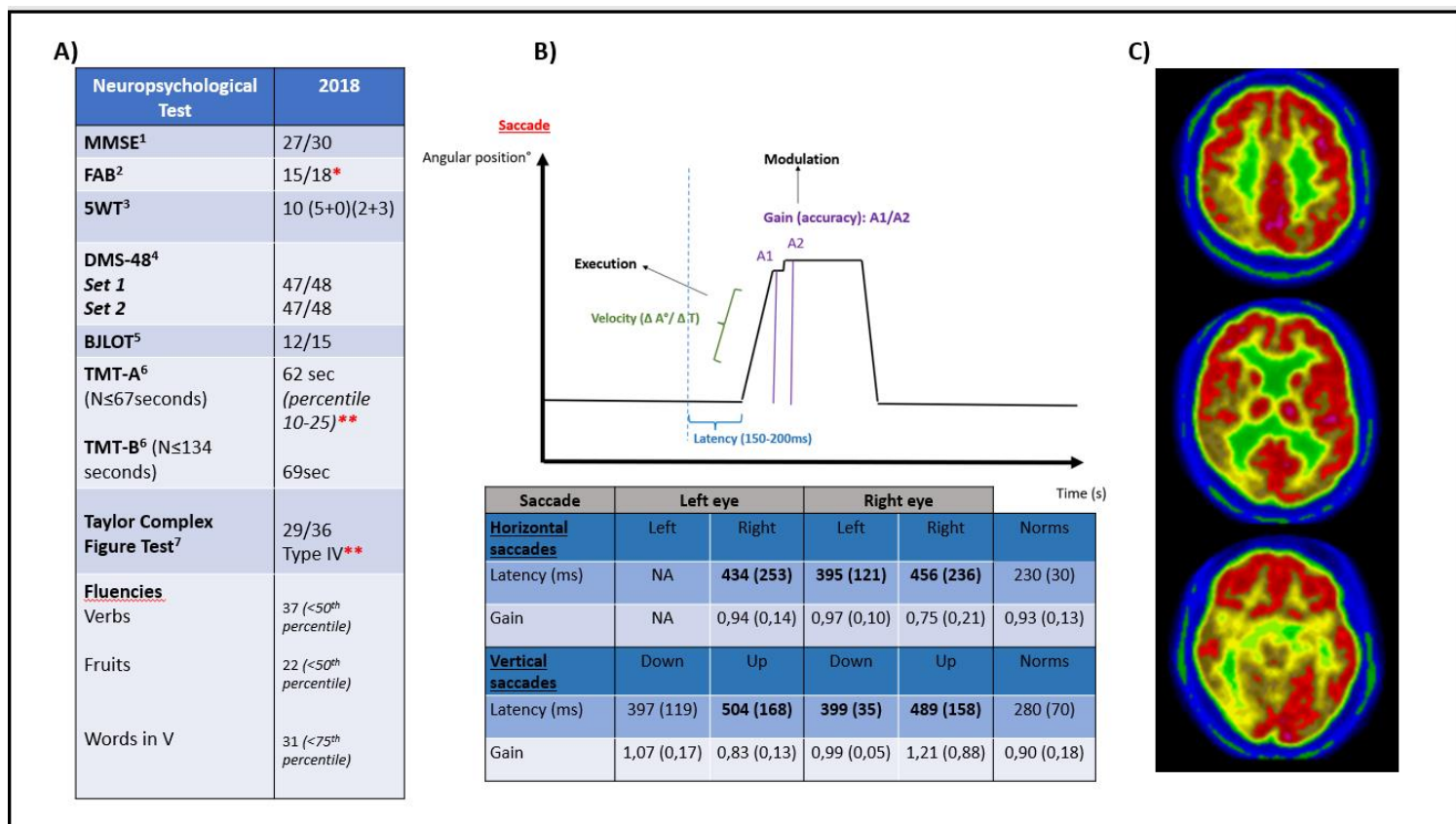
- A fluorodeoxyglucose PET-scan showing a hypometabolism in the associative parieto-occipital cortex (Fig.1C).
- A lumbar puncture showing a biomarker profile consistent with the diagnosis of Alzheimer disease (1).

The final diagnosis was Posterior Cortical Atrophy (PCA) due to Alzheimer Disease.

PCA is a clinico-radiological syndrome initially described by Benson and al. in 1988. The original description insisted on the impairment of higher-order neuro-visual functions with relative sparing of memory and semantic knowledge (2). Less interest has been given to the VOG studies of the impact of neurovisual impairment on oculomotor behavior in basic oculomotor tasks:

- Impaired saccade, smooth pursuit and fixation parameters have nearly always been observed in PCA. (3). The greatest differences between PCA- and typical AD-patients were seen on the saccadic tasks with greater latency and shorter saccades in the PCA-group. The increase of saccadic latency is due to defective ability to disengage, shift and reengage visual attention. The Parietal Eye Field (PEF) located in posterior parietal cortex is directly involved in programming saccades to visual targets. Lesions involving the PEF in human cause prolonged latency of visually guided saccades (4). It is noteworthy that only a third of PCA-patients showed clinically-relevant neuro-visual deficits on neuropsychological assessment while the eye movement abnormalities were present in 80% of patients on VOG records (3). Concordantly, M.A. performed above the norms expected in the visuo-spatial tasks and showed impairments in VOG eye movement study too.

In conclusion, the case of M.A. illustrates the interest of VOG in the early diagnosis of PCA, when the visual complaint is mild, atypical or even absent and the structural brain imaging not contributive. Finding abnormalities such as an increased saccadic latency can guide the clinician's decision to undergo or not further investigations.



**Fig 1. A)** Initial neuropsychological assesment of M.A. in 2018. Global cognition was preserved (Mini-Mental State Examination<sup>1</sup>) as well as anterograde verbal (Five Word-Test<sup>3</sup>) and visual (Delayed Matching to Sample 48<sup>4</sup>) memory. Visuo-spatial skills (Benton Judgment of Line Orientation Test<sup>5</sup>) and Fluencies were operant. In contrast, a mild executive impairment was found on the Frontal Assesment Battery<sup>2</sup> and the Trail Making Test- Part A<sup>6</sup> with a score ranging between percentile 10 and percentile 25. The Taylor Complex Figure Test<sup>7</sup> was poorly planned (Type IV). **B)** Video-Oculo-Graphy showing increased saccadic latencies in both directions with normal gain, suggesting a dysfunction in the Parietal Eye Field located in posterior parietal cortex. **C)** FDG PET Scan revealing a hypometabolism predominant in the right parieto-occipital associative cortex.

## References

1. Lehmann S, Dumurgier J, Schraen S, Wallon D, Blanc F, Magnin E, et al. A diagnostic scale for Alzheimer's disease based on cerebrospinal fluid biomarker profiles. *Alzheimers Res Ther.* 26 juin 2014;6(3):38.
2. Benson DF, Davis RJ, Snyder BD. Posterior cortical atrophy. *Arch Neurol.* juill 1988;45(7):789- 93.
3. Shakespeare TJ, Kaski D, Yong KXX, Paterson RW, Slattery CF, Ryan NS, et al. Abnormalities of fixation, saccade and pursuit in posterior cortical atrophy. *Brain J Neurol.* juill 2015;138(Pt 7):1976- 91.
4. Panouillères M, Habchi O, Gerardin P, Salemm R, Urquizar C, Farne A, et al. A Role for the Parietal Cortex in Sensorimotor Adaptation of Saccades. *Cereb Cortex.* 1 févr 2014;24(2):304- 14.