



HAL
open science

Clinical and radiological assessment of scoliosis in Koolen-de Vries syndrome

Arianne Bouman, Romy N Bouwmeester, Leo A van Vlimmeren, Pauline Burger, Jean-louis Mandel, Bert B A de Vries, Marinus de Kleuver, Willemijn M Klein, Joyce M Geelen, David A Koolen

► **To cite this version:**

Arianne Bouman, Romy N Bouwmeester, Leo A van Vlimmeren, Pauline Burger, Jean-louis Mandel, et al.. Clinical and radiological assessment of scoliosis in Koolen-de Vries syndrome. *American Journal of Medical Genetics Part A*, 2023, 191 (9), pp.2346 - 2355. 10.1002/ajmg.a.63334 . hal-04567566

HAL Id: hal-04567566

<https://cnrs.hal.science/hal-04567566>

Submitted on 3 May 2024

HAL is a multi-disciplinary open access archive for the deposit and dissemination of scientific research documents, whether they are published or not. The documents may come from teaching and research institutions in France or abroad, or from public or private research centers.

L'archive ouverte pluridisciplinaire **HAL**, est destinée au dépôt et à la diffusion de documents scientifiques de niveau recherche, publiés ou non, émanant des établissements d'enseignement et de recherche français ou étrangers, des laboratoires publics ou privés.

Clinical and radiological assessment of scoliosis in Koolen-de Vries syndrome

Ariane Bouman¹  | Romy N. Bouwmeester² | Leo A. van Vlimmeren³  |
Pauline Burger⁴  | Jean-Louis Mandel^{4,5}  | Bert B. A. de Vries¹  |
Marinus de Kleuver⁶  | Willemijn M. Klein⁷ | Joyce M. Geelen⁸ |
David A. Koolen¹ 

¹Department of Human Genetics, Donders Institute for Brain, Cognition and Behavior, Radboud University Medical Center, Nijmegen, The Netherlands

²Department of Pediatric Nephrology, Radboud Institute for Molecular Life Sciences, Radboud University Medical Center, Amalia Children's Hospital, Nijmegen, The Netherlands

³Department of Rehabilitation and Pediatric Physical Therapy, Radboud University Medical Center, Amalia Children's Hospital, Nijmegen, The Netherlands

⁴Institut de Génétique et de Biologie Moléculaire et Cellulaire (IGBMC), Department of Neurogenetics and Translational Medicine, Centre National de la Recherche Scientifique (CNRS UMR7104), Institut National de la Santé et de la Recherche Médicale (INSERM U1258), Université de Strasbourg, Illkirch, France

⁵University of Strasbourg, Institute for Advanced Studies (USIAS), Strasbourg, France

⁶Department of Orthopedic Surgery, Radboud University Medical Center, Nijmegen, The Netherlands

⁷Department of Medical Imaging, Radboud University Medical Center, Nijmegen, The Netherlands

⁸Developmental and Genetic Pediatrics, Amalia Children's Hospital, Radboud University Medical Center, Nijmegen, The Netherlands

Correspondence

David A. Koolen, Department of Human Genetics, Radboud University Medical Center, PO Box 9101, Nijmegen 6500 HB, The Netherlands.

Email: david.koolen@radboudumc.nl

Abstract

The Koolen-de Vries syndrome (KdVS) is a multisystem disorder characterized by developmental delay, intellectual disability, characteristic facial features, epilepsy, cardiovascular and urogenital malformations, and various musculoskeletal disorders. Scoliosis is a common feature. The aim of this study is to fill the gap in the current knowledge about scoliosis in individuals with KdVS and to provide recommendations for management and follow-up. In total, 54 individuals with KdVS were included in the study, with a mean age of 13.6 years (range 1.9–38.8 years). Spine radiographs, MR scans, and corresponding radiology reports were analyzed retrospectively for scoliosis and additional anomalies. The presence of scoliosis-related clinical conditions was assessed in participants' medical records and by use of a parent survey. Scoliosis was present in 56% of the participants (30/54) with a mean age of onset of 10.6 years and curve progression during the growth spurt. Prevalence at age 6, 10, and 18 years was, respectively, 9%, 41%, and 65%. Most participants were diagnosed with a single curve (13/24, 54%), of which five participants had a long C-curve type scoliosis. No significant risk factors for development of scoliosis could be identified. Severity was mostly classified as mild, although 29% (7/24) of the curves were larger than 30° at last follow-up. Bracing

Abbreviations: AIS, adolescent idiopathic scoliosis; BMI, body mass index; CA, Cobb angle; CB, coronal balance; KdVS, Koolen-de Vries syndrome; LCS, long C-curve type scoliosis; LL, lumbar lordosis; MR scans, magnetic resonance scans; NMS, neuromuscular scoliosis; PT, physical therapy; SB, sagittal balance; TK, thoracic kyphosis.

This is an open access article under the terms of the [Creative Commons Attribution-NonCommercial](https://creativecommons.org/licenses/by-nc/4.0/) License, which permits use, distribution and reproduction in any medium, provided the original work is properly cited and is not used for commercial purposes.

© 2023 The Authors. *American Journal of Medical Genetics Part A* published by Wiley Periodicals LLC.

therapy was received in 13% (7/54), and surgical spinal fusion was warranted in 6% (3/54). Remarkably, participants with scoliosis received less often physical therapy compared to participants without scoliosis ($P = 0.002$). Scoliosis in individuals with KdVS should be closely monitored and radiologic screening for scoliosis and vertebrae abnormalities is recommended at diagnosis of KdVS, and the age of 10 and 18 years.

KEYWORDS

17q21.31, diagnostic imaging, *KANSL1*, Koolen-de Vries syndrome, scoliosis

1 | INTRODUCTION

The Koolen-de Vries syndrome (KdVS, MIM no. 610443) is a rare neurodevelopmental disorder with multi-system involvement, caused by a (micro)deletion at chromosome 17q21.31 or by a pathogenic variant in the *KANSL1* gene (Koolen et al., 2006, 2010, 2012; Sharp et al., 2006; Shaw-Smith et al., 2006; Zollino et al., 2012). The syndrome is characterized by developmental delay, intellectual disability, characteristic facial features, epilepsy, cardiovascular, and urogenital malformations. In addition, KdVS is associated with various musculoskeletal conditions, including hypotonia, hip dysplasia, joint hypermobility, foot deformities, and abnormal spinal curvatures, including scoliosis (Koolen et al., 2010, 2016). Since the first description of KdVS, there have been several clinical studies focusing on specific clinical features of the syndrome, such as language and speech development delay (Morgan et al., 2018), epilepsy (Myers et al., 2017), and behavioral characteristics (Egger et al., 2013). These studies are important for the management of individuals with KdVS and can lead to awareness, disease specific treatment and recommendations. In depth clinical research also provides a better picture of the natural history and is necessary for defining treatment outcome measures.

Scoliosis is one of the important features in KdVS that is still little known, even though it is a common problem. In small studies, scoliosis has been reported in 31%–38% of the individuals with KdVS (Koolen et al., 2016; Zollino et al., 2015), which is in line with data from GenIDA, an international patient registry showing that the prevalence of scoliosis is 26% among 200 individuals with KdVS (Burger et al., 2022). Scoliosis is defined as a complex three-dimensional torsional deformity affecting the spine and the trunk (Negrini et al., 2018), and can give rise to a substantial burden on health-related quality of life. In KdVS little is known about the clinical and radiologic characteristics, age at diagnosis, progression over time, associated clinical conditions, severity, risk factors, and therapy, hampering proper care and surveillance of KdVS patients. The aim of this study is to fill these gaps in knowledge about scoliosis in individuals with KdVS and to provide recommendations for management and follow-up.

2 | MATERIALS AND METHODS

2.1 | Recruitment

In this international retrospective cohort study 54 participants were included. Inclusion criterion was a molecular diagnosis of KdVS, either

a 17q21.31 (micro)deletion or a *KANSL1* pathogenic variant. Three individuals were excluded due to an additional genetic diagnosis and/or tethered cord syndrome. Participants were recruited through the Radboudumc biobank “Genetic Rare Disease” ($n = 16$), GenIDA ($n = 16$), and the KdVS foundation ($n = 22$). Parents/caregivers of participants recruited through the Radboudumc biobank gave explicit permission to use the medical data for research purposes (registration number: 2018-4985). Moreover, this specific study is approved by the ethical committee of the Radboudumc (registration number: 2020-6413) and is conducted according to ethical requirements of the GenIDA database, which is approved by the institutional Review Board of the French Institute of Medical Research and Health (INSERM).

2.2 | Clinical characteristics

The presence of scoliosis and associated clinical conditions was studied by a retrospective review of radiology, medical records, and by the distribution of a parent survey, written in Dutch, English, German, and French (Supplementary File S1). Parent-reported outcomes were used if clinical information was missing in the medical records or medical records were not available.

Evaluated clinical conditions were the presence of past and/or current hypotonia, hypertonia, joint hypermobility, hip dysplasia, leg length discrepancy, back pain, neurologic symptoms, foot deformities, walking ability, and received spine therapies (physical therapy [PT], bracing, casting, and surgical spinal fusion). In addition, body mass index (BMI) was evaluated (current and at time of diagnosis). BMI charts of Nemours were used for comparison with age- and sex-matched references (Gavin, 2020). Underweight was defined as a BMI below the 5th percentile for age, gender, and height. Overweight was defined as a BMI above the 85th percentile. The χ^2 -test, ANOVA, and Bonferroni correction were used in statistics, a P value <0.05 was considered as significant.

2.3 | Radiologic characteristics

After informed consent was given, physicians were requested to disclose participants' radiographs and MR scans of the spine, including corresponding radiology reports, if available. Radiographs of low

quality, because of motion artifacts, were excluded. We performed measurements on standing full spine radiographs. Measurements were performed three times by one researcher (AB) and mean values were used for further analysis. The mean intra-observer difference in measurement of Cobb angle was 2.1° (SD 1.1). The assessment of radiographs and MR scans for vertebrae and disc anomalies (e.g., hemivertebrae, fused vertebrae, antero- and retrolisthesis, and spondylolisthesis) was performed by a second researcher (WK). Radiology reports were used to describe radiologic characteristics if images were not available. Radiographs in this report are published with permission of the participant concerned and their legal representative. Radiology was assessed retrospectively using a DICOM viewer (Philips healthcare, Best, the Netherlands, version R3.0-SP03), and all measurements were stored.

2.4 | Definitions of measurements

On radiographs, measurements were performed according to the methods described by Kim et al. (2010; Figure 1). The degree of scoliosis, thoracic kyphosis, and lumbar lordosis was measured by the Cobb angle. Coronal and sagittal balance were measured by use of a plumb line drawn downward from the center of the C7 vertebral body (Figure 1). Balance and pelvic obliquity could only be assessed if a radiograph of the entire spine was available.

Scoliosis was defined as a coronal curve over 10° (Horne et al., 2014; Negrini et al., 2018). Thoracic kyphosis (T4–T12) was considered as normal between 10° and 33° , lumbar lordosis (L1–S1) between 24° and 53° (Fon et al., 1980; Shefi et al., 2013). Curve type was classified according to the location of the major curve and the

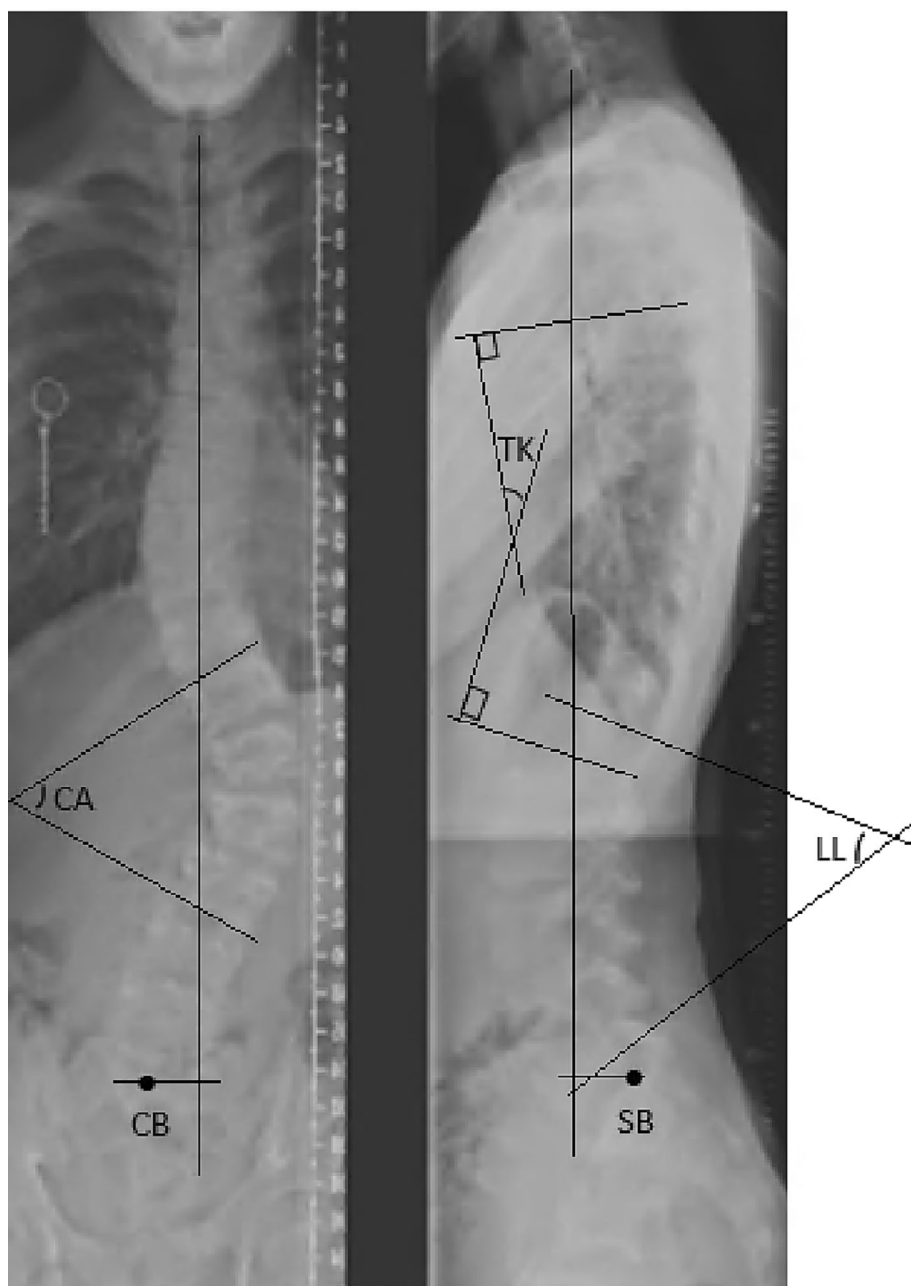


FIGURE 1 Methods of radiological assessment. CA, Cobb Angle (formed by perpendiculars to the superior endplate and the inferior endplate of end vertebrae); CB, Coronal Balance (C7-midline of sacrum, normal <2 cm); TK, Thoracic Kyphosis (angle between superior endplate T4 and inferior endplate T12); LL, Lumbar Lordosis (angle between superior endplate L1 and inferior endplate S1); SB, Sagittal Balance (C7-Posterosuperior aspect of S1, normal <2 cm).

number of scoliotic curvatures (single, double, triple curve). A subclass of the single scoliotic curve is the long C-curve type scoliosis (LCS; Horne et al., 2014; Lenke, 2005). Measurements were done at initial diagnosis and during follow-up.

3 | RESULTS

3.1 | Prevalence

In total, 54 participants were included, of whom 44% was male (24/54). At inclusion, the mean age was 13.6 years (1.9–38.8 years), and 13 participants were older than 18 years (24%) (Table 1). Clinical information was received from all participants. In the current study cohort, scoliosis was diagnosed in 56% (30/54) of which 26/30 was radiologically confirmed. Of the latter, radiology data could be obtained in 24. In the participants without scoliosis (24/54), the absence of scoliosis was radiologically confirmed in 2 participants, whereas in the remaining 22 participants the absence of scoliosis was based on clinical examination and report. Individuals were more commonly affected with increasing age, as shown in Figure 2. Prevalence at age 6, 10, and 18 years was 9%, 41%, and 65%, respectively. There was no significant difference in scoliosis' prevalence between individuals with a 17q21.31

microdeletion versus a *KANSL1* variant ($P = 0.887$), or between males and females ($P = 0.854$).

3.2 | Clinical characteristics

Participants' clinical characteristics are shown in Tables 1 and S1. Hypotonia was anamnestic present at birth in 96% (51/53), and at the time of inclusion in 83% (43/52). Hypertonia was not present, neither at birth nor at the time of inclusion. Joint hypermobility was present in 86% (38/44). Although all participants could walk, 38% (20/53) of them were only able to walk for limited time or distance. After Bonferroni correction, there was no significant difference in the presence of hypotonia, joint hypermobility and walking ability between the scoliosis and the non-scoliosis group. Most participants had a normal BMI corrected for their age (43/52, 83%), and weight (percentile, underweight, normal weight, or overweight) did not influence the occurrence of scoliosis (Table 1).

In the scoliotic group, 13% reported daily or weekly back pain (3/23), which was associated with paresthesia in the legs in one participant, whereas in the non-scoliotic group, only one participant (6%) reported daily back pain, without neurologic symptoms.

In participants with scoliosis, hip dysplasia was reported in 17% (4/24), leg length discrepancy in 21% (5/24), pedes plani in 46%

TABLE 1 Characteristics of participants (at inclusion).

	All participants (%)	Participants with scoliosis (%)	Participants without scoliosis (%)	P-value
All participants (N) ^a	54 (100%)	30 (56%)	24 (44%)	
Gender (male)	24/54 (44%)	13/30 (43%)	11/24 (46%)	0.854
Mean age in years (range)	13.6 (1.9–38.8)	16.6 (5.3–38.8)	9.8 (1.9–25.3)	0.003
17q21.31 microdeletion	41/54 (76%)	23/30 (77%)	18/24 (75%)	0.887
<i>KANSL1</i> mutation	13/54 (24%)	7/30 (23%)	6/24 (25%)	
Hypotonia first year after birth	51/53 (96%)	28/30 (93%)	23/23 (100%)	0.499
Currently hypotonia	43/52 (83%)	24/29 (83%)	19/23 (83%)	1.000
Joint hypermobility	38/44 (86%)	20/23 (87%)	18/21 (86%)	1.000
Able to walk	54/54 (100%)	30/30 (100%)	24/24 (100%)	1.000
Medical history of back pain	11/40 (28%)	9/23 (39%)	2/17 (12%)	0.079
Currently daily or weekly back pain	4/40 (10%)	3/23 (13%)	1/17 (6%)	0.624
Weight				
Underweight	4/52 (8%)	1/30 (3%)	3/22 (14%)	0.063
Normal weight	43/52 (83%)	24/30 (80%)	19/22 (86%)	
Overweight	5/52 (10%)	5/30 (17%)	0/22 (0%)	
Mean percentile of weight in children (N = 41) (SD)	38.0 (25.5)	38.4 (25.5)	37.9 (26.1)	0.950
Physical therapy (PT)				
Received PT	38/54 (70%)	16/30 (53%)	22/24 (92%)	0.002
Mean starting age in years (range)	1.7 (0.0–9.1)	2.8 (0.0–9.1)	0.9 (0.0–5.2)	0.017
PT once or more times a week	25/32 (78%)	12/13 (92%)	13/19 (68%)	0.195

^aOrigin: 4 Australia, 1 Belgium, 1 Canada, 4 France, 6 Germany, 1 Hungary, 16 Netherlands, 1 United Kingdom, and 20 United States.

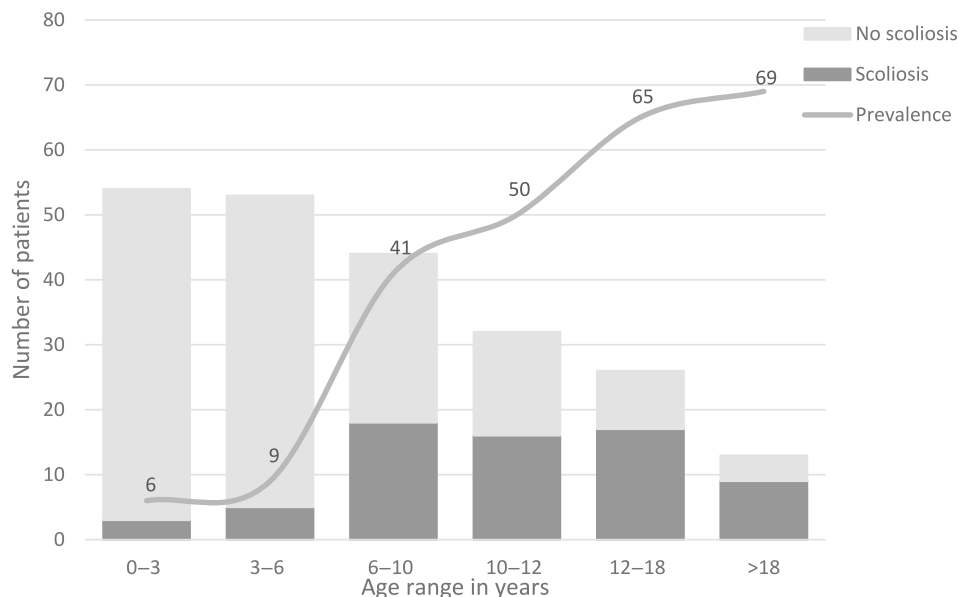


FIGURE 2 The prevalence of scoliosis in KdVS. It is shown that prevalence increases with age.

TABLE 2 Radiologic characteristics at diagnosis.

	N (%)	Mean age at diagnosis in years (range)	Mean magnitude of the major curve in degrees (range)
Participants with radiologically confirmed scoliosis	24 (100%)	10.6 (1.1–22.8)	21 (10–48)
Single lumbar curve	13 (54%)	9.0 (1.1–22.8)	20 (13–32)
Long C-curve scoliosis	5 (21%)	7.7 (6.8–9.7)	16 (10–22)
Double curve	10 (42%)	12.4 (6.3–17.3)	22 (13–42)
Triple curve	1 (4%)	14.4	26
Thoracic kyphosis (T4–T12) ^a		11.9 (6.8–22.8)	32 (6–63)
Lumbar lordosis (L1–S1) ^b		11.5 (6.3–22.8)	56 (32–84)

^aMagnitude assessable in N = 14.

^bMagnitude assessable in N = 15.

(11/24), and valgus deformity of hips, knees, and/or ankle in 21% (5/24).

3.3 | Radiologic characteristics

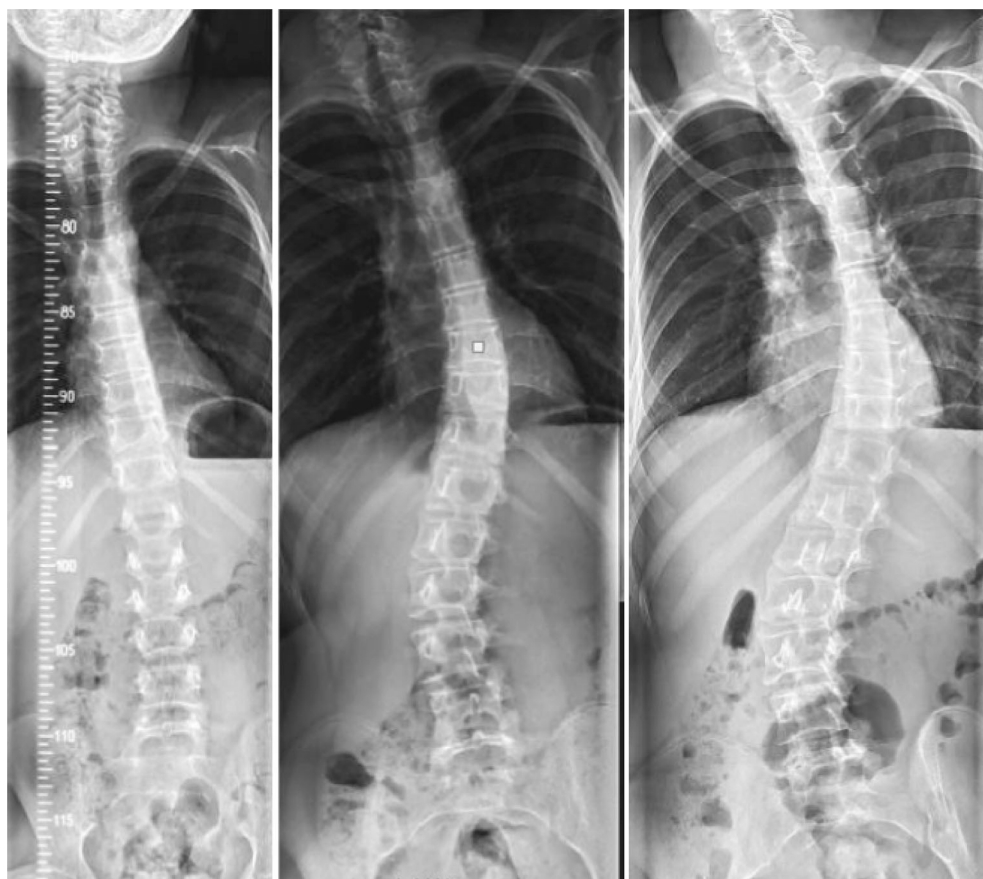
3.3.1 | Initial presentation

Out of 24 participants in which radiology data were available, the mean age at diagnosis was 10.6 years (range 1.1–22.8 years; Table S1). The magnitude of the major curve was greater and the number of scoliotic curvatures was higher if the scoliosis was diagnosed at later age (Table 2). The mean curve magnitude was 21° (range 10°–48°). At diagnosis, 13% of participants (3/24, mean age 12.7 years, range 10.1–15.5 years) presented with a curve magnitude >30° (range 30°–42°). Most participants were diagnosed with a single curve (13/24, 54%), of which five participants had a LCS (Table 2; Figure 3). Of all participants with a thoracic curve, only one had a curve convex to the left (1/11, 9%). A thoracic sagittal radiograph was

available in 17/24 participants, a lumbar sagittal radiograph in 16/24 participants. Scoliosis was associated with hyperkyphosis in 47% (8/17) and/or with hyperlordosis in 50% (8/16). In five cases, both hyperkyphosis and hyperlordosis were present (31%). Rarely, scoliosis was seen in combination with hypokyphosis (3/17, 18%) or hypolor-dosis (2/16, 13%). No difference was found between curve type and occurrence of abnormal sagittal curves ($P = 1.000$).

Coronal imbalance at initial diagnosis was present in 45% (9/20) and was associated with a single curve in 56% of cases. Sagittal imbalance was present in 47% (7/15). Pelvic obliquity was a common condition in scoliosis (8/20, 40%), and was associated with leg length discrepancy in 50% (4/8). All participants with pelvic obliquity had hypotonia (Table S1). Mild subluxation of cervical vertebral bodies (3 mm retrolisthesis, 2 mm anterolisthesis) was found in one participant with scoliosis (1/30, 3%), in whom “watchful waiting” was practiced. In two participants with scoliosis, severe vertebral body wedging was present (2/24, 8%; Table S1). No other vertebral anomalies were reported in the participants with and without scoliosis.

FIGURE 3 Long C-curve scoliosis and scoliotic curve progression. (1) Age 11.9, Long C-curve type scoliosis. (2) Age 15.2, Double curve, major curve thoracolumbar/lumbar. (3) Age 16.0, Curve progression. Published after consent for publication.



3.3.2 | During follow-up

Follow-up data in the scoliosis group were present in 15/30 participants (50%). The mean time between diagnosis and last follow-up was 4.5 years (0.4–17.6 years). During follow-up there was an increase in curve magnitude of $>10^\circ$ in seven participants (mean age at follow-up 16.8 years, range 10.9–33.1 years), and a decrease of $>10^\circ$ in one participant (age 8.9 years) without bracing or surgery. Overall, 29% of the curves (of the patients for whom radiological data were available) were larger than 30° (7/24). In two participants, a LCS progressed to a double, major thoracic curve. In another two participants, a single lumbar curve progressed to a thoracolumbar/lumbar curve (Figure 3). The mean age of progression to another curve type was 12.5 years (range 11.8–14.1 years). At last follow-up, 93% had a double scoliotic curve (14/15), of which the thoracic curve was convex to left in 14% (2/14).

3.4 | Therapy

A majority of the participants received physical therapy (PT) (38/54, 70%); however, it was not clear what this therapy was aimed at (Table 1). At the time of inclusion, 41% of participants still received regular PT. Compared to the scoliotic group, the participants without scoliosis received PT more often ($P = 0.002$), which remains significant after Bonferonni correction was performed. In addition, participants

without scoliosis started PT at a younger age ($P = 0.017$). The mean starting age in the non-scoliotic group was 0.9 years (range 0.0–5.2 years) compared to 2.8 years (0.0–9.1 years) in the scoliotic group. Most participants received PT one or more times a week (25/32, 78%) and the mean duration of received PT was 7.4 years (1.0–20.0 years). 13% of participants received bracing therapy (7/54) and radiology data were available in six of them (Table 3). Mean starting age of bracing therapy was 11.2 years (7.9–15.5 years), and the mean duration of received therapy was 3.4 years (1.1–6.9 years). During bracing therapy, the average change of the initial major curve was 3° (varying from 15° decrease to 20° increase in curve magnitude). Because of curve progression beyond 40° , surgical spinal fusion was required in three participants (3/54, 6%) (Table 3; Figure 4). Spinal fusion reduced their major curve with a mean of 37° (29° – 49°). In addition, one participant underwent lumbar L3–S1 spinal fusion because of retrolisthesis of L5.

4 | DISCUSSION

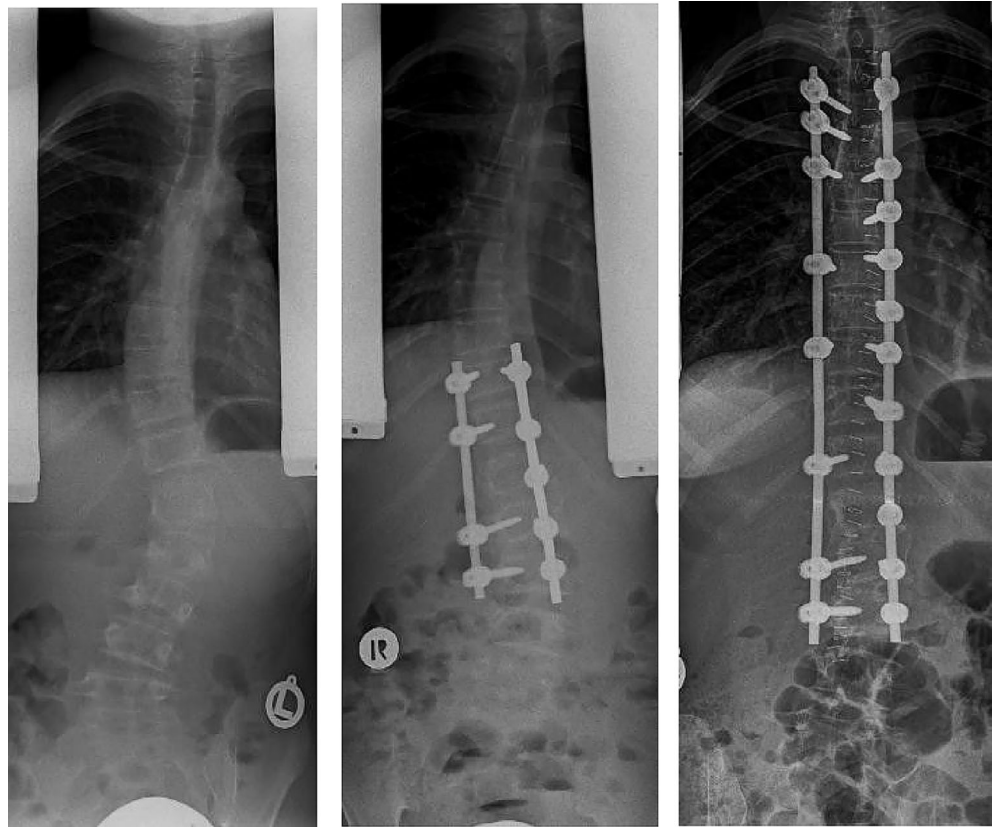
4.1 | Prevalence

This study confirms the high prevalence of scoliosis among individuals with KdVS. In the present study scoliosis is present in more than half of all patients (56%), which is higher than reported in the medical literature and in the GenIDA registry (Burger et al., 2022; Koolen

TABLE 3 Effect of bracing therapy and surgery.

Study ID	Sex	Therapy	Age at start of therapy (years)	Reason	Levels fused	Before therapy		Directly after therapy		At last visit		Duration of bracing therapy (months)	Duration of follow-up (months)
						Thoracic magnitude (°)	Lumbar magnitude (°)	Thoracic magnitude (°)	Lumbar magnitude (°)	Thoracic magnitude (°)	Lumbar magnitude (°)		
16	Female	Brace	15.5	Double curve		42	48	47	60	30	57	24	
		Surgery	33.1	thoracolumbar/lumbar	T4-L4	62	84	30	52	30	57		2
19	Female	Brace	11.4	Double curve		15	24	31	44			13	
				thoracolumbar/lumbar									
		Surgery	12.5	Lumbar curve	T11-L3	44	44		14		23		29
			15.0	Thoracic curve	T3-T12	40		11		Data not available		Data not available	
20	Female	Brace	10.4	Lumbar curve		<10	37	23	45			83	
23	Male	Brace	7.9	Double curve with major curve thoracic		23	13	16	20			42	
40	Female	Surgery	10.2	Congenital retrolisthesis of L5 (with anterior vertebral body wedging)	L3-S1		13		13		23		32
		Brace	12.1	Double curve thoracolumbar/lumbar		Data not available	23	Data not available	23			40	
44	Female	Brace	10.0	Double curve with major curve thoracic		33	26	18	23			41	
56	Female	Surgery	11.7	Double curve thoracolumbar/lumbar	T2-T5 and L2-L4	83	45	34	15	43	32		8
				Spinal rod extension									
			13.2	Spinal rod extension									

FIGURE 4 Surgical T3–L3 instrumented spinal fusion. (1) Age 12.3, pre-surgery; (2) Age 12.5, post-surgery T11–L3 instrumented spinal fusion; (3) Age 15.0, post-surgical revision T3–L3 instrumented spinal fusion. Published after consent for publication.



et al., 2010, 2016; Zollino et al., 2015). The GenIDA database, is based on patient reported outcomes and reports a prevalence of scoliosis in KdVS of 26% (51/200). It is likely that parents of a child with scoliosis were more likely to participate in the present study, even though all parents were approached and it was explicitly indicated that all children could participate, regardless of the presence of scoliosis. The higher prevalence in the current study can also be explained because asymptomatic scoliotic curves were included. Comparison of data from medical records and radiology with parent-reported outcomes, showed that both parents and physicians underestimate the presence of scoliosis when asymptomatic. In this study, the included participants without scoliosis were significantly younger than the ones with scoliosis, which might result in an underestimation of the prevalence. Moreover, in 22 participants the absence of scoliosis was based on clinical examination, which does not exclude a mild abnormal sideways curvature of the spine.

The age of onset of scoliosis in KdVS and the progression during the growth spurt is similar to what is described in patients with adolescent idiopathic scoliosis (AIS; Lonstein, 1994; Negrini et al., 2018). In the current study cohort, the primary age of onset for scoliosis is 10.6 years, although the range is rather broad. The prevalence of scoliosis increases with age from 41% at age 10 years to 65% at age 18 years (Figure 2).

4.2 | Clinical and radiologic characteristics

At diagnosis, the mean curve magnitude was 21° (range 10°–48°). In 13% of participants (3/24) the curve magnitude at diagnosis exceeded

30°. Data on follow-up data were available in 15 participants, of whom four showed progression over >30° during follow-up. In most participants, scoliotic curves remained <30° (17/24). From previous studies we know that in AIS curves below 30° are mainly asymptomatic and the least prone to progression (Horne et al., 2014; Negrini et al., 2018). However, whether the course of the scoliosis in KdVS is similar to AIS, requires more data.

More complex scoliotic curves (double and triple curve type) were more prevalent in children diagnosed at later age. In general, at the time of diagnosis most participants had a single curve (54%), whereas the double thoracolumbar/lumbar curve was the most prevalent (42%) at last visit. This increase in the number of scoliotic curvatures, might be caused by the frequent association of scoliosis with coronal imbalance (45%) and sagittal imbalance (47%). It is previously described that spinal imbalance is self-corrected by the development of additional curves (Kim et al., 2010).

Clinical neuromuscular conditions commonly present in KdVS are hypotonia (83%–96%), and joint hypermobility (86%). Remarkable was the frequent association of scoliosis with hyperkyphosis and hyperlordosis (47% vs. 50%) and the presence of a LCS in 21%. LCS is often associated with neuromuscular scoliosis (NMS; Rolton et al., 2014). NMS and idiopathic scoliosis are the two main types of scoliosis (Horne et al., 2014; Kim et al., 2010). Patients with NMS often develop long S- and or C-shaped curves that can involve the entire spine and sacrum, in contrast to idiopathic scoliosis where curves are generally restricted to shorter regions (Rolton et al., 2014). The scoliosis pattern in KdVS fits to what is known for NMS and syndromic

curves, based on the high number of LCS and the underlying neurological and/or myopathic condition.

The contributing factors of scoliosis in KdVS are not yet known and require further study. In 8% of the patients in this study, scoliosis could be due to the presence of wedge-shaped vertebrae, as is known from previous studies showing that osteogenic conditions, including severe wedge-shaped vertebrae, hemivertebrae, and fused vertebrae can lead to scoliosis (Kim et al., 2010). In our cohort, a left-sided thoracic curve was present in only 9%. From previous studies, it is known that a left-sided thoracic curve is associated with intraspinal pathology (Horne et al., 2014).

Moreover, also the underlying mechanism should be further studied. KdVS is caused by haploinsufficiency of the *KANSL1* gene (Koolen et al., 2012; Zollino et al., 2012), but the function of *KANSL1* does not directly provide clues about the pathogenesis. *KANSL1* is part of the non-specific lethal (NSL) complex, which regulates global transcription by histone modification (Dias et al., 2014). Haploinsufficiency of *KANSL1* leads to differences in expression of a large number of genes (Koolen et al., 2012), and probably, differentially expressing of some of these genes results in scoliosis, because of their role in neurophysiology and musculoskeletal development.

4.3 | Therapy

Therapeutic options for scoliosis include PT, bracing, casting, and surgical spinal fusion. Interestingly, in this study, the non-scoliotic participants received PT more often ($P = 0.002$) and started PT at younger age ($P = 0.017$) compared to the scoliotic group. These results are still significant after Bonferroni correction, however, it was unclear of PT in our participants specifically targeted scoliosis. A minority of participants received bracing therapy (13%). Mean duration of bracing therapy was 3.4 years, in which total curve progression was 3° . Compared to the mean progression of 12° , this finding is consistent with previous studies regarding AIS, reporting that bracing therapy is efficient to slow down progression (Negrini et al., 2018). Eventually, in this study cohort 6% (3/54) underwent spinal surgery, which may be an underrepresentation because of limited follow up data and the fact that not all patients are mature yet.

4.4 | Recommendations and conclusions

In conclusion, based on the high prevalence of scoliosis in KdVS (56%), and the co-relation with neurologic and musculoskeletal conditions, scoliosis should be closely monitored in patients with KdVS. With remaining growth the curves tend to progress, so the incidence of curves $>30^\circ$ and/or surgery may be expected to increase over time. In this cohort, the prevalence of scoliosis increases with age to 65% at age 18 years. Radiologic screening for scoliosis and vertebrae abnormalities is recommended at diagnosis and around the age of 10 years. When scoliosis is present, follow-up should be intensified during the growth spurt, because of the expected increase in the curve magnitude. However, scoliosis in KdVS can develop at any age, and therefore,

physicians should be alert to the development of scoliosis and perform a full spine standing radiograph if there is a clinical suspicion of scoliosis. In KdVS patients without scoliosis, a second routine radiologic screening is recommended around the age of 18 years. The increase in prevalence over 18 years of age is minimal (4%). Radiographs in both anterior-posterior and sagittal view, including the assessment of spinal alignment on both are required, because of the high prevalence of abnormal kyphosis, abnormal lordosis, and coronal- and sagittal imbalance. Finally, special attention should be paid to leg length correction during full spine standing radiographs, as scoliosis associated with leg length discrepancy was found in 21%. The role of PT in scoliosis is a matter of debate. Our data suggests a positive effect of PT in children with KdVS. Therefore, PT from an early age should be considered with emphasis on individualized scoliosis-specific exercises.

AUTHOR CONTRIBUTIONS

Conceptualization and Methodology: Arianne Bouman, Romy N. Bouwmeester, Joyce M. Geelen, David A. Koolen. *Data collection:* Arianne Bouman, Joyce M. Geelen, David A. Koolen. *Investigation and data analyses:* Arianne Bouman, Willemijn M. Klein. *Writing – Original Draft:* Arianne Bouman, Romy N. Bouwmeester, Leo A. van Vlimmeren, Marinus de Kleuver, Joyce M. Geelen, David A. Koolen. *Writing – Review and Editing:* Arianne Bouman, Romy N. Bouwmeester, Leo A. van Vlimmeren, Pauline Burger, Jean-Louis Mandel, Bert B. A. de Vries, Marinus de Kleuver, Willemijn M. Klein, Joyce M. Geelen, David A. Koolen.

ACKNOWLEDGMENTS

We thank the individuals with Koolen-the Vries syndrome and their families or caregivers for their support and participation. We thank the Koolen-de Vries Syndrome Foundation and GenIDA for raising awareness and distributing our research surveys. This work is generated within the European Reference Network for Intellectual disability, TeleHealth, Autism and Congenital Anomalies (ITHACA).

CONFLICT OF INTEREST STATEMENT

The authors declare that they have no competing interests.

DATA AVAILABILITY STATEMENT

The data that support the findings of this study are available on request from the corresponding author. The data are not publicly available due to privacy or ethical restrictions. The original contributions presented in the study are included in the article/supplementary material. Further inquiries can be directed to the corresponding author.

ORCID

Arianne Bouman  <https://orcid.org/0000-0002-1138-8026>
 Leo A. van Vlimmeren  <https://orcid.org/0000-0002-3511-3393>
 Pauline Burger  <https://orcid.org/0000-0003-2109-5451>
 Jean-Louis Mandel  <https://orcid.org/0000-0002-0535-6589>
 Bert B. A. de Vries  <https://orcid.org/0000-0002-0000-2917>
 Marinus de Kleuver  <https://orcid.org/0000-0002-3506-1212>
 David A. Koolen  <https://orcid.org/0000-0002-2152-4626>

REFERENCES

- Burger, P., Colin, F., Strehle, A., Mazzucotelli, T., Collot, N., Coutelle, R., Durand, B., Bouman, A., Landau Prat, D., Kleefstra, T., Parrend, P., Piton, A., Koolen, D. A., & Mandel, J. L. (2022). GenIDA: An international participatory database to gain knowledge on health issues related to genetic forms of neurodevelopmental disorders. *Journal of Neural Transmission (Vienna)*, 1-13, 459–471. <https://doi.org/10.1007/s00702-022-02569-3>
- Dias, J., van Nguyen, N., Georgiev, P., Gaub, A., Brettschneider, J., Cusack, S., Kadlec, J., & Akhtar, A. (2014). Structural analysis of the KANSL1/WDR5/KANSL2 complex reveals that WDR5 is required for efficient assembly and chromatin targeting of the NSL complex. *Genes & Development*, 28(9), 929–942. <https://doi.org/10.1101/gad.240200.114>
- Egger, J. I., Wingbermuhle, E., Verhoeven, W. M., Dijkman, M., Radke, S., de Bruijn, E. R., de Vries, B., Kessels, R. P., & Koolen, D. (2013). Hyper-sociality in the behavioral phenotype of 17q21.31 microdeletion syndrome. *American Journal of Medical Genetics Part A*, 161A(1), 21–26. <https://doi.org/10.1002/ajmg.a.35652>
- Fon, G. T., Pitt, M. J., & Thies, A. C., Jr. (1980). Thoracic kyphosis: Range in normal subjects. *AJR. American Journal of Roentgenology*, 134(5), 979–983. <https://doi.org/10.2214/ajr.134.5.979>
- Gavin, M. L. (2020). Body mass index (BMI). <https://kidshealth.org/en/parents/bmi-charts.html>
- Horne, J. P., Flannery, R., & Usman, S. (2014). Adolescent idiopathic scoliosis: Diagnosis and management. *American Family Physician*, 89(3), 193–198.
- Kim, H., Kim, H. S., Moon, E. S., Yoon, C. S., Chung, T. S., Song, H. T., Suh, J. S., Lee, Y. H., & Kim, S. (2010). Scoliosis imaging: What radiologists should know. *Radiographics*, 30(7), 1823–1842. <https://doi.org/10.1148/rg.307105061>
- Koolen, D. A., Kramer, J. M., Neveling, K., Nillesen, W. M., Moore-Barton, H. L., Elmslie, F. V., Toutain, A., Amiel, J., Malan, V., Tsai, A. C. H., Cheung, S. W., Gilissen, C., Verwiel, E. T. P., Martens, S., Feuth, T., Bongers, E. M. H. F., de Vries, P., Scheffer, H., Vissers, L. E. L. M., ... de Vries, B. B. A. (2012). Mutations in the chromatin modifier gene KANSL1 cause the 17q21.31 microdeletion syndrome. *Nature Genetics*, 44(6), 639–641. <https://doi.org/10.1038/ng.2262>
- Koolen, D. A., Morgan, A., & de Vries, B. B. A. (2010). Koolen-de Vries Syndrome. In M. P. Adam, H. H. Ardinger, R. A. Pagon, S. E. Wallace, L. J. H. Bean, K. Stephens, & A. Amemiya (Eds.), *GeneReviews(R)*. University of Washington.
- Koolen, D. A., Pfundt, R., Linda, K., Beunders, G., Veenstra-Knol, H. E., Conta, J. H., Fortuna, A. M., Gillissen-Kaesbach, G., Dugan, S., Halbach, S., Abdul-Rahman, O. A., Winesett, H. M., Chung, W. K., Dalton, M., Dimova, P. S., Mattina, T., Prescott, K., Zhang, H. Z., Saal, H. M., ... De Vries, B. B. A. (2016). The Koolen-de Vries syndrome: A phenotypic comparison of patients with a 17q21.31 microdeletion versus a KANSL1 sequence variant. *European Journal of Human Genetics*, 24(5), 652–659. <https://doi.org/10.1038/ejhg.2015.178>
- Koolen, D. A., Vissers, L. E., Pfundt, R., De Leeuw, N., Knight, S. J. L., Regan, R., Kooy, R. F., Reyniers, E., Romano, C., Fichera, M., Schinzel, A., Baumer, A., Anderlid, B. M., Schoumans, J., Knoers, N. V., Van Kessel, A. G., Sistermans, E. A., Veltman, J. A., Brunner, H. G., & De Vries, B. B. A. (2006). A new chromosome 17q21.31 microdeletion syndrome associated with a common inversion polymorphism. *Nature Genetics*, 38(9), 999–1001. <https://doi.org/10.1038/ng1853>
- Lenke, L. G. (2005). Lenke classification system of adolescent idiopathic scoliosis: Treatment recommendations. *Instructional Course Lectures*, 54, 537–542.
- Lonstein, J. E. (1994). Adolescent idiopathic scoliosis. *Lancet*, 344(8934), 1407–1412. [https://doi.org/10.1016/s0140-6736\(94\)90572-x](https://doi.org/10.1016/s0140-6736(94)90572-x)
- Morgan, A. T., Haaften, L. V., van Hulst, K., Edley, C., Mei, C., Tan, T. Y., Amor, D., Fisher, S. E., & Koolen, D. A. (2018). Early speech development in Koolen de Vries syndrome limited by oral praxis and hypotonia. *European Journal of Human Genetics*, 26(1), 75–84. <https://doi.org/10.1038/s41431-017-0035-9>
- Myers, K. A., Mandelstam, S. A., Ramantani, G., Rushing, E. J., De Vries, B. B., Koolen, D. A., & Scheffer, I. E. (2017). The epileptology of Koolen-de Vries syndrome: Electro-clinico-radiologic findings in 31 patients. *Epilepsia*, 58(6), 1085–1094. <https://doi.org/10.1111/epi.13746>
- Negrini, S., Donzelli, S., Aulisa, A. G., Czaprowski, D., Schreiber, S., De Mauroy, J. C., Diers, H., Grivas, T. B., Knott, P., Kotwicki, T., Lebel, A., Marti, C., Maruyama, T., O'Brien, J., Price, N., Parent, E., Rigo, M., Romano, M., Stikeleather, L., ... Zaina, F. (2018). 2016 SOSORT guidelines: Orthopaedic and rehabilitation treatment of idiopathic scoliosis during growth. *Scoliosis and Spinal Disorders*, 13, 3. <https://doi.org/10.1186/s13013-017-0145-8>
- Rolton, D., Nnadi, C., & Fairbank, J. (2014). Scoliosis: A review. *Paediatrics Child Health*, 24(5), 197–203.
- Sharp, A. J., Hansen, S., Selzer, R. R., Cheng, Z., Regan, R., Hurst, J. A., Stewart, H., Price, S. M., Blair, E., Hennekam, R. C., Fitzpatrick, C. A., Segreaves, R., Richmond, T. A., Guiver, C., Albertson, D. G., Pinkel, D., Eis, P. S., Schwartz, S., Knight, S. J. L., & Eichler, E. E. (2006). Discovery of previously unidentified genomic disorders from the duplication architecture of the human genome. *Nature Genetics*, 38(9), 1038–1042. <https://doi.org/10.1038/ng1862>
- Shaw-Smith, C., Pittman, A. M., Willatt, L., Martin, H., Rickman, L., Gribble, S., Curley, R., Cumming, S., Dunn, C., Kalaitzopoulos, D., Porter, K., Prigmore, E., Krepisch-Santos, A. C. V., Varela, M. C., Koiffmann, C. P., Lees, A. J., Rosenberg, C., Firth, H. V., De Silva, R., & Carter, N. P. (2006). Microdeletion encompassing MAPT at chromosome 17q21.3 is associated with developmental delay and learning disability. *Nature Genetics*, 38(9), 1032–1037. <https://doi.org/10.1038/ng1858>
- Shefi, S., Soudack, M., Konen, E., & Been, E. (2013). Development of the lumbar lordotic curvature in children from age 2 to 20 years. *Spine (Phila Pa 1976)*, 38(10), E602–E608. <https://doi.org/10.1097/BRS.0b013e31828b666b>
- Zollino, M., Marangi, G., Ponzi, E., Orteschi, D., Ricciardi, S., Lattante, S., Murdolo, M., Battaglia, D., Contaldo, I., Mercuri, E., Stefanini, M. C., Caumes, R., Ederly, P., Rossi, M., Piccione, M., Corsello, G., Della Monica, M., Scarano, F., Priolo, M., ... Zackai, E. (2015). Intragenic KANSL1 mutations and chromosome 17q21.31 deletions: Broadening the clinical spectrum and genotype-phenotype correlations in a large cohort of patients. *Journal of Medical Genetics*, 52(12), 804–814. <https://doi.org/10.1136/jmedgenet-2015-103184>
- Zollino, M., Orteschi, D., Murdolo, M., Lattante, S., Battaglia, D., Stefanini, C., Mercuri, E., Chiurazzi, P., Neri, G., & Marangi, G. (2012). Mutations in KANSL1 cause the 17q21.31 microdeletion syndrome phenotype. *Nature Genetics*, 44(6), 636–638. <https://doi.org/10.1038/ng.2257>

SUPPORTING INFORMATION

Additional supporting information can be found online in the Supporting Information section at the end of this article.

How to cite this article: Bouman, A., Bouwmeester, R. N., van Vlimmeren, L. A., Burger, P., Mandel, J.-L., de Vries, B. B. A., de Kleuver, M., Klein, W. M., Geelen, J. M., & Koolen, D. A. (2023). Clinical and radiological assessment of scoliosis in Koolen-de Vries syndrome. *American Journal of Medical Genetics Part A*, 191A:2344–2353. <https://doi.org/10.1002/ajmg.a.63334>