



HAL
open science

Restoring immune tolerance in pemphigus vulgaris

A. Razzaque Ahmed, Mikole Kalesinskas, Srini V Kaveri

► **To cite this version:**

A. Razzaque Ahmed, Mikole Kalesinskas, Srini V Kaveri. Restoring immune tolerance in pemphigus vulgaris. Proceedings of the National Academy of Sciences of the United States of America, 2024, 211 (5), pp.e2317762121. 10.1073/pnas.2317762121 . hal-04677223

HAL Id: hal-04677223

<https://cnrs.hal.science/hal-04677223v1>

Submitted on 25 Aug 2024

HAL is a multi-disciplinary open access archive for the deposit and dissemination of scientific research documents, whether they are published or not. The documents may come from teaching and research institutions in France or abroad, or from public or private research centers.

L'archive ouverte pluridisciplinaire **HAL**, est destinée au dépôt et à la diffusion de documents scientifiques de niveau recherche, publiés ou non, émanant des établissements d'enseignement et de recherche français ou étrangers, des laboratoires publics ou privés.

Restoring immune tolerance in pemphigus vulgaris

A. Razzaque Ahmed, MD, DSc, MPA, FRCP (Edin)^{1,2}, Mikole Kalesinskas, MD¹, Srini V. Kaveri DVM, PhD³

^{1,2} Department of Dermatology, Center for Blistering Diseases, Tufts University School of Medicine, Boston, MA 02111, USA

³ Institut National de la Santé et de la Recherche Médicale, Centre de Recherche des Cordeliers, Sorbonne Université, Université de Paris, France.

Corresponding author:

A. Razzaque Ahmed, MD, DSc, MPA, FRCP (Edin) Professor of Dermatology, Tufts University School of Medicine Director, Center for Blistering Diseases 697 Cambridge Street, Suite 302 Boston, MA, 02135, MA Tel: 617-562-1040

Email: arahmedmd@msn.com

Competing Interest Statement:

The authors declare no competing interest. Classification: Major: Biological Sciences. Minor: Immunology and Inflammation.

Keywords:

intravenous immunoglobulin, pemphigus vulgaris, immune restoration, long-term follow-up, human model

Abstract

Intravenous immunoglobulin (IVIg)-a preparation of polyclonal serum IgG pooled from thousands of blood donors-has been used for nearly three decades, and is proving to be efficient treatment for many autoimmune blistering diseases, including pemphigus vulgaris (PV). Despite its widespread use and therapeutic success, the mechanisms of action of IVIg are not completely understood. However, several hypotheses have been suggested regarding its anti-inflammatory and immunomodulatory actions. In this study, the authors present a twenty-year follow-up of 21 patients with clinical and immunopathological confirmed PV, treated with IVIg as monotherapy, according to an established published protocol. IVIg therapy produced long-term sustained, clinical, serological, and immunopathologic remission. For 20 years, these patients received no drugs and experienced no disease. This observation suggests the establishment of immune balance or restoration of immune regulation in PV. Twelve (57%) of 21 PV patients experienced no relapses during follow-up. Six patients (29%) experienced a relapse due to acute stress or post-coronavirus infection and/or vaccination. Reinstitution of IVIg resulted in prompt sustained recovery. Three patients (14.2%), in clinical and serological remission, died due to unrelated causes. No severe adverse effects from IVIg were documented in all 21 patients. The combination of several anti-inflammatory and immunomodulatory effects of IVIg may explain its beneficial influence in this autoimmune disease. This study provides a human prototype to examine the pathophysiology of autoimmunity and a model to study immune regulation and mechanisms that can facilitate restoring immune tolerance.

Significance Statement

This research demonstrated a twenty-year clinical and serological remission in patients with recalcitrant pemphigus vulgaris (PV), a potentially fatal mucocutaneous autoimmune disease. Conventional immunosuppressive therapy was unsuccessful. Consequently, these patients were treated with intravenous immunoglobulins (IVIg) as monotherapy by a defined protocol. It requires multiple infusions at defined intervals to induce remission. The twenty-year remission was post-IVIg therapy. This would suggest restoration of immune tolerance. IVIg has anti-inflammatory and immunomodulatory effects in the microenvironment. Its long-term effects are not completely studied. This long-term analytical study provides a model to examine autoimmunity and design disease-specific protocols that facilitate the mechanisms to restore immune tolerance in other autoimmune diseases.

Main Text

Introduction

Pemphigus vulgaris (PV) is a potentially fatal autoimmune blistering disease involving the mucous membranes and the skin. (1) It is a chronic disease with high morbidity, protein and fluid loss and systemic infections contributing to mortality, (2, 3) characterized by autoantibodies against desmosomal proteins. Histology demonstrates intraepidermal vesicles with acantholysis.(3) Majority of the patients initially present with oral disease.(2)

The use of systemic corticosteroids (CS) in the 1970s reduced the mortality rate. (4–6) Their serious side effects warranted the use of immunosuppressive agents (ISAs) for their alleged steroid-sparing effect. (7–14) The resultant

prolonged immunosuppression eventually contributed to opportunistic infections, morbidity and mortality. Hence, the need for new modalities for safer treatments with fewer, limited, manageable side effects.

In 2001, 21 PV patients with extensive, widespread severe disease, with multiple relapses and recurrences, who had serious side effects from CS and multiple ISAs, frequent systemic infections and multiple hospitalizations, and were considered recalcitrant to available treatments, were reported. (15) These patients received intravenous immunoglobulin (IVIg) as a treatment of last resort. (15) The purpose of this report was to provide a clinical and serological post-IVIg follow-up of 20-years or more on the same 21 PV patients.

Results

Details of clinical profiles, age at last follow-up, duration of conventional therapies prior to IVIg, and length of clinical remission and follow-up since the 2001 publication on the 21 PV patients are presented in Tables I-III. Eighteen (85.7%) are alive and in remission. Three patients (14.2%) died from unrelated causes, but were in remission at time of death. The total mean duration of clinical remission and follow-up since the 2001 publication in the 21 patients was 17.5 years (range 5.1-30.5). The follow-up is presented in categories based on clinical outcomes as follows:

3.1 Pemphigus vulgaris (PV) patients with uneventful follow-up

Among the 21 patients, twelve patients (57%) had an uneventful follow-up (Table I). Mean duration of conventional therapy prior to IVIg was 28.2 months (range 12-60). The mean length of clinical remission and follow-up since the 2001 publication was 19.4 years (range 10.0-30.3), without recurrences or relapses. After ten years of follow-up, while in clinical and serological remission, one patient was lost to follow-up.

3.2 Patient deaths during follow-up

Three patients (14.2%) in clinical and serological remission died due to unrelated causes (Table II). The mean length of clinical remission and follow-up was 6.9 years (range 5.1-9.1).

3.3 Patients with relapse secondary to acute severe stress

Four patients (19%) experienced a relapse of pemphigus due to acute, severe stress during follow-up. Prior to relapse, the patients were in clinical remission for a mean of 10.4 years (range 5.6-17). The detailed cause of relapses are in Table IIIA. The diagnosis of relapse was confirmed by histology, DIF and serology. All four patients received short-term, mean 11 weeks (range 9-18), low-dose oral prednisone (0.5-1.0 mg/kg/day) and a mean of 11 cycles (range 9-13) of IVIg that resulted in clinical and serological remission and currently remain in remission for a mean of 14 years (range 10-18.5).

3.4 Patients with SARS-CoV-2-related relapse

Two patients (9.5%) relapsed due to the SARS-CoV2 virus or vaccine during follow-up, and are presented in Table IIIB. The first patient was in remission after initial IVIg for 15 years. This patient was hospitalized for PCR-confirmed SARS-CoV2 infection and had a relapse of PV three weeks later. Treated with short-term, mean 11 weeks (range 9-18), low-dose oral prednisone (0.5-1.0 mg/kg/day) and 9 cycles of IVIg, the patient was in clinical and serological remission for three years post-IVIg.

The second patient was in clinical remission after initial IVIg therapy for 14 years, and had a clinical relapse of PV, 3-4 weeks after COVID-19 vaccination. Relapse confirmed by biopsy, DIF and serology and treated with low-dose oral prednisone and 12 cycles of IVIg, resulted in clinical and serological remission that has lasted for two years.

During this 20-year follow-up, no patient experienced any serious side effects or complications from previous IVIg therapy. No malignancies or other autoimmune diseases were reported.

Discussion

The cumulative evidence obtained from several studies suggests that IVIg is an effective alternative treatment for severe or recalcitrant pemphigus vulgaris (PV).(16) In this study, the authors followed 21 PV patients from a previous 2001 publication for a period of twenty years or more.(15) Three patients (14.2%) died and 18 patients (85.8%) are alive and in remission. The indications for IVIg were recalcitrant disease, non-responsiveness to

conventional immunosuppressive therapy (CIST), with severe side effects, and inability to obtain a prolonged clinical remission off-therapy. Once CIST was discontinued, IVIg was used as monotherapy. In the majority of these patients, remission was maintained for a mean of 17.5 years, off-therapy. This was accompanied with absence of pathogenic autoantibodies from the sera and sites of binding in the skin and mucosal tissue. The rationale for this successful outcome could be that IVIg helped in correcting the dysregulated humoral and cellular compartments that are characteristic of the immunopathogenesis of PV and, in turn, restored a long-term physiological immune equilibrium or immune tolerance.

The use of IVIg therapy produced a long-term clinical remission in the 21 patients. Twelve (57%) of 21 PV patients experienced no relapses or recurrences of pemphigus during follow-up (Table I). There were three deaths (14.2%) in the 21 PV patients during long-term follow-up. The deaths were not attributed to IVIg usage. At the time of death, all three patients were in clinical and serological remission (Table II). Six patients (29%) experienced a relapse (Table III). Reinstitution of IVIg, with a short initial course of prednisone, resulted in prompt recovery. Four relapses (19%) were directly associated with severe and traumatic stress in the patients' lives. (Table IIIA). There is significant evidence that acute emotional stress can trigger pemphigus relapse, especially in individuals with a previous history of it. (17–20) Stress has also been documented as a trigger in other autoimmune diseases. (21)

Since the emergence of the new coronavirus (COVID-19), there have been numerous reports on the incidence of exacerbations of PV, which occurred from the infection or the vaccination. (22) Two patients (9.5%), who were in clinical and serological remission for many years, experienced a relapse during follow-up after COVID-19 infection or vaccination (Table IIIB). At that time, IVIg preparations did not contain antibodies to SARS-CoV2 from donors who were either exposed to the virus or vaccinated.

There are several rare but serious adverse effects associated with the use of IVIg (23), however, none were documented throughout the follow-up period.

In the 2001 publication, IVIg therapy was used according to an established protocol, developed by an International Consensus Building Committee of Experts on Autoimmune Blistering Diseases, on the use of IVIg therapy for their treatment. (24) Twenty years later, since these 21 PV patients were still in clinical, serological, and immunopathologic remission, this data suggests that the protocol is effective and may play a vital role in the restoration of physiological immune homeostasis or immune tolerance. Many other autoimmune diseases that use IVIg as a treatment option, do not use a defined protocol. Consequently, long-term remissions are not reported and multiple re-infusions are necessary as in chronic inflammatory demyelinating polyneuropathy (CIDP) or multifocal motor neuropathy (MMN). (25–28) While the authors attribute successful outcome to the published protocol, (24) they do not advocate its use in other autoimmune diseases affecting other organ systems. A novel protocol should be created for every autoimmune disease, that can benefit from IVIg, through consensus building. Recently Rituximab has been recommended as an effective first-line treatment of PV. (29) Studies have demonstrated Rituximab's steroid-sparing effect. (30) However, the rate of relapse on Rituximab increases with length of clinical follow-up, ranging from 40-81%, with long-term rates of clinical remission off-therapy observed in only 39-45%. (31) In addition, complete B-cell depletion, caused by Rituximab, predisposes to infection, which has been observed in 37% of patients. (32) Furthermore, mortality has been reported in 10.2% of patients with PV. (33) The most common cause of mortality reported was infection. (34) Consequently, the addition of IVIg with Rituximab would allow immune prophylaxis. In a prospective study of Rituximab and IVIg combination protocol, 11 patients achieved clinical remission off-therapy, without infection in a 15-year follow-up. (35)

Inflammation is the hallmark of autoimmune conditions. The pathogenic immune response directed against the self-components leads to a dysregulated inflammatory reaction. IVIg exerts its beneficial role by its anti-inflammatory effect and by imposing a physiological immune status. This, in part, may explain the clinical benefits observed by its use in multiple autoimmune diseases. IVIg suppresses inflammation by resetting the threshold for innate immune effector cell activation and inhibition. (36) These mechanisms include; modulation of FcγR expression; inhibition of pro-inflammatory cytokines (IL-1β, IFN-γ, IL-17, TNF-α); production of anti-inflammatory cytokines (IL-1RA, IL-10); neutralization of activated complement components, blockade of macrophage activation and dendritic cell maturation, and upregulation of NK-cell functions. (37) IVIg may also exert its effect, at least in part, by inducing apoptosis of immune cells via Fas-specific or neutrophil-specific antibodies present in the IVIg preparation. (38, 39)

Interestingly, studies by Viard et al. demonstrated that IVIg has a beneficial effect in toxic epidermal necrolysis (TEN), or Lyell's syndrome, wherein they showed that IVIg interferes with the binding of Fas and its natural ligand (Fas L), thereby inhibiting the excessive apoptosis of keratinocytes. (40) It is therefore reasonable to consider that both pro- and antiapoptotic antibodies may be found in IVIg, and that the overall result could depend on the amount of antibodies and their affinity and avidity for their target molecule, Fas.

IVIg also plays a vital role in adaptive immunity, by influencing naïve and mature B-cells, plasma cells, and T-cells, particularly the T_{regs}.(37, 41) Positive clinical response to IVIg correlates with an increased number of CD138+ plasma cells, which produce normal or physiologic antibodies that compete with pathogenic antibodies in the diseased microenvironment.(37) Expansion of antigen-specific T_{regs} further decreases inflammation. (37, 41)

IVIg, through enhanced usage of Vh3-30 and 3-23 gene segments during the VDJ recombination process, promotes normal B-cell production and indirectly downregulates autoreactive Bcells. (37) An increase of normal BCR, by receptor editing, in autoreactive B-cells, is facilitated by IVIg and CD22. Furthermore, decrease in BAFF/APRIL allows for rebalance of the B-cell repertoire. The cumulative evidence demonstrates that IVIg possesses anti-inflammatory properties, in addition to immunomodulation, without the harmful adverse events normally associated with CIST.

While several mechanisms implicating the anti-inflammatory and immunomodulatory effects of IVIg may explain the short-term beneficial influence of IVIg in autoimmune dermatological conditions, it is important to underline the effects that explain the long-term remission, as in this cohort study. The authors believe that one of the important components of IVIg is the high content of natural antibodies (NABs).(42) Natural antibodies, that form a significant fraction of IVIg, are antibodies capable of interacting with a wide range of self- and non-self-antigens in a physiological configuration. NABs bind to pathogens, implicating a role in natural host defense against infectious pathogens by contributing to the removal of senescent cells, debris and transformed malignant cells. NABs also modulate the processing of antigens and their subsequent presentation to T-cells. Of particular relevance for the understanding of the long-term mode of action of IVIg in antibody-mediated autoimmune diseases, is the role of NABs in the maintenance of B-cell homeostasis. NABs prevent the expansion of specific autoreactive clones and are able to regulate self-reactivity of circulating antibodies through idiotypic interactions. The interaction of IVIg with idiotypes of pathogenic autoantibodies accounts for the neutralization of circulating autoantibodies in patients with autoantibody-mediated autoimmune conditions, and modulation of antibody synthesis by B-cells expressing the relevant idiotype. (42) Antibodies to variable region determinants of the T-cell receptor are also present in IVIg and these anti-TCR antibodies may be of relevance for regulation of T-cell function in patients with autoimmune disorders. Therefore, an overall impact of IVIg in restoring the immune homeostasis in autoimmune conditions, is critical for the long-term effects of IVIg that was observed in this cohort.(43) In addition to IVIg, more targeted recombinant approaches impacting humoral immunity in a selective fashion, functioning via FcRn and FcγRs, are currently being explored. (44)

From a recent investigation, using systems biology approaches along with machine learning, IVIg seems to have a pleiotropic effect, implicating a cooperative participation of several target pathways. The impact of each target in clinical benefit could be different for each disease. Thus, the broad range of activity of IVIg could be critical to its beneficial effect in different diseases. (45) The current study has several limitations. This includes the lack of a control group of PV patients with identical recalcitrant disease. Reproducing this study will be difficult, because a twenty-year follow-up will be a significant challenge. In 2001, Rituximab was not available to conduct a comparative study for efficacy in PV.

Conclusion

Despite limitations, certain important conclusions can be drawn from this data on the use of IVIg in PV. Long-term clinical and serological remission was achieved with IVIg, using a defined published protocol of 2g/kg/cycle, which is gradually tapered after a clinical response, demonstrating the efficacy of the protocol. The data suggests that the beneficial effects of IVIg could be due to its anti-inflammatory influences to the microenvironment. IVIg, in part, provides the basis for the reestablishment of an immune equilibrium and the potential to eliminate clinical autoimmunity in PV and restore immune

Materials and Methods

2.1 2001 Publication

In the 2001 publication, patient demographics, diagnostic and inclusion criteria, previous therapies and their side effects, and frequency of recurrence and relapses were described. (15) The salient and some relevant features of the 21 patients published in 2001 are presented as follows; All patients were Caucasian. Mean age at disease onset was 56 years (range 23-83). Five patients had only mucosal, 16 had mucocutaneous disease. All patients had positive direct immunofluorescence (DIF) of perilesional skin and histology, consistent with PV.

Prior to IVIg therapy, the mean dose of prednisone was 77 mg/d (range 50-120). The cumulative mean dose was 35,202 mg (range 14,750-89,500), for a mean duration of 36.4 months (range 12-96 months). Recurrences, defined as appearance of new lesions while on systemic therapy, had a reported frequency with a mean of 5.6 (range 2-12). Relapses, defined as new disease while off-therapy, had a reported frequency with a mean of 7.9 (range 0-18). The indications for IVIg were recalcitrant disease, non-responsiveness to conventional immunosuppressive therapy (CIST), which produced catastrophic and consequential side effects, and inability to obtain a prolonged clinical remission off-therapy.

2.2 The Treatment Protocol

Thirty-eight international experts in an in-person Consensus Development Conference, discussed and published a protocol for the use of IVIg in autoimmune mucocutaneous blistering diseases. (24) (Figure 1)

2.3 CISTs during IVIg therapy

Clinical control was achieved in a mean of 4.5 months (range 2.6-6.5). Tapering of IVIg required a mean of 22.7 months (range 19.8-28.0). After initiation of IVIg, oral prednisone was used for a mean of 4.8 months (range 2.6-7.5). The cumulative dose of prednisone was a mean of 1,850 mg (range 1,180-3,200). ISAs were used for a mean of 2.9 months (range 0-6). Once CIST was discontinued, IVIg was used as monotherapy.

2.4 Statistical difference of clinical outcome parameters

When comparing the following parameters of pre-IVIg and post-IVIg therapy, a high statistically significant difference was reported. (15) These included total dose and duration of prednisone, duration of ISAs, side effects, number of hospital admissions, days of hospitalization, and number of recurrences and relapses.(15) The titers of pemphigus autoantibodies steadily decreased and were nondetectable at the time of publication. (15, 46)

At the time of publication in 2001, patients were observed for a mean of 20.4 months (range 13-73), post-IVIg therapy.

2.5 Post-2001 Publication Follow-up

For the first three years after the last IVIg cycle, all 21 patients were seen at 6-month intervals for three years, then at 9-month intervals, later, at yearly intervals. At each visit, they were clinically examined and serologically tested. A biopsy for DIF was performed, preferably from the same site as diagnosis. Patients who were unable to travel to the Center, their information was obtained from the primary care provider or referring physician.

While the motivations for participating in follow-up differed, the following were present in all the 21 patients.

- (1) Patient Characteristics: All patients had recalcitrant disease and were desperate and frustrated, had a poor quality of life, and were aware that they could have a potentially fatal outcome.
- (2) Cost of Treatment: IVIg therapy was authorized and provided by the individual's insurance companies, at no cost to the patient.
- (3) Site of Infusion: The patients were treated in an ambulatory setting and not hospitalized. Since they were immunocompromised, concerns for infection were somewhat reduced. Presence of other patients in the infusion suite provided a powerful, positive psychological effect, which created a support group environment.

- (4) A conscientious non-binding, non-legal agreement was made between the patients, their families, primary care physicians and referring dermatologists. The patients agreed to a long-term follow-up, to determine if IVIg could produce prolonged, sustained clinical remission. They realized that this information would benefit future patients and their treating physicians.
- 5) In part, the patients' cooperation was based on their sense of gratitude for their recovery from a potentially fatal outcome and the restoration of a high-quality life that IVIg facilitated.
- (6) Majority of the patients were in the healthcare professions. They clearly understood the need and the benefits of such long-term follow-up.

Acknowledgments

This publication is based on research supported by an unrestricted educational grant from the Dysimmune Diseases Foundation.

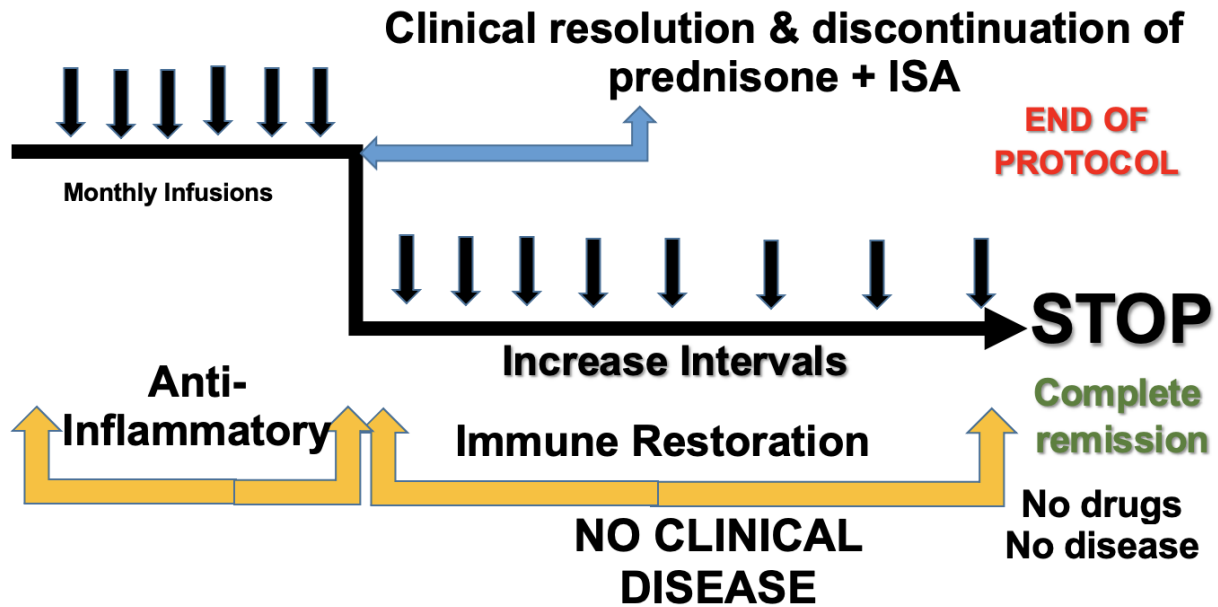
References

1. A. M. Malik, et al., An Updated Review of Pemphigus Diseases. *Medicina (Kaunas)* 57, 1080 (2021).
2. E. Ruocco, A. Baroni, R. Wolf, V. Ruocco, Life-threatening bullous dermatoses: Pemphigus vulgaris. *Clin Dermatol* 23, 223–226 (2005).
3. K. Kridin, Pemphigus group: overview, epidemiology, mortality, and comorbidities. *Immunol Res* 66, 255–270 (2018).
4. M. Cholera, N. Chainani-Wu, Management of Pemphigus Vulgaris. *Adv Ther* 33, 910–958 (2016).
5. J. G. Ryan, Pemphigus: A 20-Year Survey of Experience with 70 Cases. *Arch Dermatol* 104, 14–20 (1971).
6. P. J. Carson, A. Hameed, A. R. Ahmed, Influence of treatment on the clinical course of pemphigus vulgaris. *J Am Acad Dermatol* 34, 645–652 (1996).
7. E. Schmidt, M. Kasperkiewicz, P. Joly, Pemphigus. *Lancet* 394, 882–894 (2019).
8. A. M. Porro, C. A. Seque, M. C. C. Ferreira, M. M. S. E. S. Enokihara, Pemphigus vulgaris. *An Bras Dermatol* 94, 264–278 (2019).
9. J. W. Frew, L. K. Martin, D. F. Murrell, Evidence-Based Treatments in Pemphigus Vulgaris and Pemphigus Foliaceus. *Dermatol Clin* 29, 599–606 (2011).
10. R. L. Yanovsky, M. McLeod, A. R. Ahmed, Treatment of pemphigus vulgaris: part 1– current therapies. *Expert Rev Clin Immunol* 15, 1047–1060 (2019).
11. A. A. Sinha, M. B. Hoffman, E. C. Janicke, Pemphigus vulgaris: Approach to treatment. *European Journal of Dermatology* 25, 103–113 (2015).
12. C. De Simone, G. Caldarola, F. Perino, A. Venier, G. Guerriero, Enteric-coated mycophenolate sodium as a steroid-sparing agent in pemphigus treatment: A retrospective study. *Dermatol Ther* 25, 219–222 (2012).
13. S. Baum, et al., Methotrexate is an effective and safe adjuvant therapy for pemphigus vulgaris. *European Journal of Dermatology* 22, 83–87 (2012).
14. N. Sarma, S. Ghosh, Mycophenolate mofetil as adjuvant in pemphigus vulgaris. *Indian J Dermatol Venereol Leprol* 73, 348–350 (2007).
15. A. R. Ahmed, Intravenous immunoglobulin therapy in the treatment of patients with pemphigus vulgaris unresponsive to conventional immunosuppressive treatment. *J Am Acad Dermatol* 45, 679–690 (2001).
16. J. H. O. Hoffmann, A. H. Enk, High-dose intravenous immunoglobulin in skin autoimmune disease. *Front Immunol* 10, 1090 (2019).
17. Y. Wohl, J. Mashiah, A. Kutz, S. Hadj-Rabia, A. D. Cohen, Pemphigus and depression comorbidity: A case control study. *European Journal of Dermatology* 25, 602–605 (2015).
18. S. Tavakolpour, Pemphigus trigger factors: special focus on pemphigus vulgaris and pemphigus foliaceus. *Arch Dermatol Res* 310, 95–106 (2018).
19. A. Tamir, J. Ophir, S. Brenner, Pemphigus vulgaris triggered by emotional stress [2]. *Dermatology* 189, 210 (1994).
20. S. Morell-Dubois, et al., Stressful life events and pemphigus. *Dermatology* 216, 104–108 (2008).

21. L. Stojanovich, D. Marisavljevic, Stress as a trigger of autoimmune disease. *Autoimmun Rev* 7, 209–213 (2008).
22. K. Aram, A. Patil, M. Goldust, F. Rajabi, COVID-19 and exacerbation of dermatological diseases: A review of the available literature. *Dermatol Ther* 34, e15113 (2021).
23. Y. Guo, X. Tian, X. Wang, Z. Xiao, Adverse effects of immunoglobulin therapy. *Front Immunol* 9, 1299 (2018).
24. A. R. Ahmed, M. V. Dahl, Consensus statement on the use of intravenous immunoglobulin therapy in the treatment of autoimmune mucocutaneous blistering diseases in *Archives of Dermatology*, (2003), pp. 1051–1059.
25. F. Terenghi, et al., How long is IVIg effective in multifocal motor neuropathy? *Neurology* 62, 666–668 (2004).
26. P. K. Chia, S. K. Y. Hung, F. L. Hiew, Clinical and functional change in multifocal motor neuropathy treated with IVIg. *Journal of Clinical Neuroscience* 69, 114–119 (2019).
27. K. Kuitwaard, et al., Maintenance IV immunoglobulin treatment in chronic inflammatory demyelinating polyradiculoneuropathy. *Journal of the Peripheral Nervous System* 22, 425–432 (2017).
28. S. Kuwabara, et al., Intravenous immunoglobulin for maintenance treatment of chronic inflammatory demyelinating polyneuropathy: A multicentre, open-label, 52-week phase III trial. *J Neurol Neurosurg Psychiatry* 88, 832–838 (2017).
29. P. Joly, et al., First-line rituximab combined with short-term prednisone versus prednisone alone for the treatment of pemphigus (Ritux 3): a prospective, multicentre, parallel-group, open-label randomised trial. *The Lancet* 389, 2031–2040 (2017).
30. D. M. Chen, et al., Rituximab is an effective treatment in patients with pemphigus vulgaris and demonstrates a steroid-sparing effect. *British Journal of Dermatology* 182, 1111–1119 (2020).
31. A. S. Payne, N. A. Ran, Rituximab therapy in pemphigus and other autoantibody-mediated diseases. *F1000Res* 6, 83 (2017).
32. J. E. Frampton, Rituximab: A Review in Pemphigus Vulgaris. *Am J Clin Dermatol* 21, 149–156 (2020).
33. L. Quintarelli, et al., Clinical Patterns, Survival, Comorbidities, and Treatment Regimens in 149 Patients With Pemphigus in Tuscany (Italy): A 12-Year Hospital-Based Study. *Front Immunol* 13, 895490 (2022).
34. K. Kridin, S. Zelber-Sagi, R. Bergman, Mortality and cause of death in patients with pemphigus. *Acta Derm Venereol* 97, 607–611 (2017).
35. A. R. Ahmed, S. Kaveri, Z. Spigelman, Long-Term Remissions in Recalcitrant Pemphigus Vulgaris. *New England Journal of Medicine* 373, 2693–2694 (2015).
36. I. Schwab, F. Nimmerjahn, Intravenous immunoglobulin therapy: How does IgG modulate the immune system? *Nat Rev Immunol* 13, 176–189 (2013).
37. A. R. Ahmed, S. Kaveri, Reversing autoimmunity combination of rituximab and intravenous immunoglobulin. *Front Immunol* 9, 1189 (2018).
38. N. K. Prasad, et al., Therapeutic preparations of normal polyspecific IgG (IVIg) induce apoptosis in human lymphocytes and monocytes: a novel mechanism of action of IVIg involving the Fas apoptotic pathway. *J Immunol* 161, 3781–3790 (1998).
39. S. Von Gunten, H. U. Simon, Granulocyte death regulation by naturally occurring autoantibodies. *Adv Exp Med Biol* 750, 157–172 (2012).
40. I. Viard, et al., Inhibition of toxic epidermal necrolysis by blockade of CD95 with human intravenous immunoglobulin. *Science* (1979) 282, 490–493 (1998).
41. T. Tha-In, J. Bayry, H. J. Metselaar, S. V. Kaveri, J. Kwekkeboom, Modulation of the cellular immune system by intravenous immunoglobulin. *Trends Immunol* 29, 608–615 (2008).
42. M. D. Kazatchkine, et al., V Region-Mediated Selection of Autoreactive Repertoires by Intravenous Immunoglobulin (i.v.Ig). *Immunol Rev* 139, 79–107 (1994).
43. M. D. Kazatchkine, S. V. Kaveri, Immunomodulation of Autoimmune and Inflammatory Diseases with Intravenous Immune Globulin. *New England Journal of Medicine* 345, 747–755 (2001).
44. A. Shock, D. Humphreys, F. Nimmerjahn, Dissecting the mechanism of action of intravenous immunoglobulin in human autoimmune disease: Lessons from therapeutic modalities targeting Fc γ receptors. *Journal of Allergy and Clinical Immunology* 146, 492–500 (2020).
45. C. Segú-Vergés, et al., Systems biology and artificial intelligence analysis highlights the pleiotropic effect of IVIg therapy in autoimmune diseases with a predominant role on B cells and complement system. *Front Immunol* 13, 901872 (2022).

46. N. Sami, K. C. Bhol, R. A. Ahmed, Influence of intravenous immunoglobulin therapy on autoantibody titers to desmoglein 3 and desmoglein 1 in pemphigus vulgaris. *European Journal of Dermatology* 13, 377–381 (2003).

IVIg Treatment Protocol



Figures and Tables

Figure 1. Ahmed IVIg Treatment Protocol

Diagrammatic representation of the Ahmed protocol for using intravenous immunoglobulin (IVIg). Initially there were monthly infusions of IVIg (anti-inflammatory phase) as systemic corticosteroids (CS) and immunosuppressive agents (ISA) were gradually discontinued. Upon clinical recovery and three months after discontinuation of CS and ISA, the intervals between IVIg cycles were increased to 6, 8, 10, 12, and 14, weeks. Last infusion was at 16 weeks interval. During this phase, immune restoration occurs. This was the end of the protocol. Patients were disease and drug free and in complete clinical remission.

Table I. Pemphigus vulgaris (PV) patients with uneventful follow-up

Patient No.	Age (y) at onset/Sex	Duration of conventional tx prior to IVIg (mo)	Duration of remission & f/u since 2001 publication (y)	Age at last f/u (y)	Current Clinical Profile
1	71/M	50	16.9	92	Currently living in elderly housing facility
2	71/F	60	16.0	92	Currently living in elderly housing facility
3	76/F	32	18.4	97	Currently living in elderly housing facility
4	65/M	20.8	30.3	97	Currently living in elderly housing facility
5	59/F	32	19.4	81	Currently living in assisted living facility
6	58/M	15	20.75	80	Currently living in assisted living facility
7	57/F	28	19.6	79	Currently living at home with daughter
8	55/M	24	20.0	77	Currently living at home
9	49/F	18	20.5	71	Currently living at home – independent
10	42/F	22	20.1	64	Currently living at home Employed, full-time working
11	41/F	12	21.0	63	Currently living at home Employed, full-time working
12	69/M	25	10.0	Unknown	Followed for 10 y. after last IVIg infusion. Not reachable. Single man- No family.

y, years; mo, months; tx; treatment, f/u, follow-up

Table II. Patient deaths during follow-up

Patient No.	Age (y) at onset/Sex	Duration of conventional tx prior to IVIg (mo)	Duration of remission & f/u since 2001 publication (y)	Age at last f/u (y)	Clinical Profile
13	62/M	84	6.5	75.5	Bladder + Prostate Ca in remission prior to PV. Tumor in remission for 6 y. post-IVIg Sudden tumor recurrence, mets & death in 9 mo. PV in remission at time of death
14	80/F	22	9.1	91	Died in sleep No autopsy PV in remission at time of death
15	83/F	17	5.1	89.6	Ruptured aortic aneurysm PV in remission at time of death

y, years; *mo*, months; *tx*, treatment, *f/u*, follow-up; *Ca*, Cancer; *PV*, Pemphigus vulgaris; *mets*, metastasis

Table III. Patients with relapse during follow-up

Patient No.	Age (y) at onset/Sex	Duration of conventional tx prior to IVIg (mo)	Duration of remission & f/u since 2001 publication (y)	Age at last f/u (y)	Clinical Profile	Duration of relapse (mo)	Treatment of relapse & f/u
(A) Relapse secondary to acute severe stress							
16	60/M	30	17.5	80	Was in clinical remission for 7 y. Recurrence 4 wk. after spousal death. Autoantibody + Bx & DIF +	3	Prednisone 40 mg + taper x4 mo, IVIg 9 cycles Psych tx. needed Currently in remission for 10 y.
17	67/M	34	17.1	87	Was in clinical remission for 5.6 y. Recurrence 5 wk. after house fire. Autoantibody + Bx & DIF +	5	Prednisone 40 mg + taper, IVIg 13 cycles Psych tx. needed Currently in remission for 11.5 y.
18	35/M	40	18.6	57	Was in clinical remission for 17 y. Recurrence 6 wk. after total bankruptcy & house auctioning. Autoantibody + Bx & DIF +	3	Prednisone 60 mg + taper IVIg 10 cycles Psych tx. needed Currently in remission for 16 y.
19	34/F	30	30.5	67	Was in clinical remission for 12 y. Recurrence 4 wk. after son's death in Afghanistan. She is a single mother. Autoantibody + Bx & DIF +	4	Prednisone 40 mg + taper IVIg 12 cycles Psych tx. needed Currently in remission for 18.5 y.
(B) SARS-CoV-2-related relapses							
20	23/F	96	15	46	12 y. in remission Contracted severe COVID-19 infection Hospitalized- Not on ventilator PV relapse occurred 3 wk. later Skin only, no mucosal involvement Autoantibody + Bx & DIF +	3.5	Prednisone 40 mg + taper IVIg 9 cycles Currently in remission for 3 y.
21	27/F	67	16.4	49	14.4 y. in remission Received COVID-19 vaccine PV relapse occurred 4 wk. later Sx in oral cavity+ skin Autoantibody + Bx & DIF +	4.3	Prednisone 60 mg + taper IVIg 12 cycles Currently in remission for 2 y.

y, years; mo, months; wk, weeks; tx, treatment; f/u, follow-up; Sx, symptoms; Bx, biopsy; DIF, Direct immunofluorescence; +, positive

