



**HAL**  
open science

## **Abnormal Connectivity of the Head Neural Integrator in Cervical Dystonia**

Giuseppe A Zito, Emmanuel Roze, Clément Tarrano, Salim Ouarab, Prasanthi Jegatheesan, Asya Ekmen, Benoît Béranger, Romain Valabregue, Cécile Hubsch, Sophie Sangla, et al.

### ► **To cite this version:**

Giuseppe A Zito, Emmanuel Roze, Clément Tarrano, Salim Ouarab, Prasanthi Jegatheesan, et al.. Abnormal Connectivity of the Head Neural Integrator in Cervical Dystonia. *Movement Disorders*, 2025, <10.1002/mds.70014>. <hal-05383936>

**HAL Id: hal-05383936**

**<https://cnrs.hal.science/hal-05383936v1>**

Submitted on 26 Nov 2025

HAL is a multi-disciplinary open access archive for the deposit and dissemination of scientific research documents, whether they are published or not. The documents may come from teaching and research institutions in France or abroad, or from public or private research centers.

L'archive ouverte pluridisciplinaire HAL, est destinée au dépôt et à la diffusion de documents scientifiques de niveau recherche, publiés ou non, émanant des établissements d'enseignement et de recherche français ou étrangers, des laboratoires publics ou privés.



Distributed under a Creative Commons CC BY-NC-ND 4.0 - Attribution - Non-commercial use - No Derivative Works - International License

## RESEARCH ARTICLE

## Abnormal Connectivity of the Head Neural Integrator in Cervical Dystonia

Giuseppe A. Zito, PhD,<sup>1</sup> Emmanuel Roze, MD PhD,<sup>2,3,4\*</sup> Clément Tarrano, MD,<sup>2,4,5</sup> Salim Ouarab, MSc,<sup>6</sup> Prasanthi Jegatheesan, PhD,<sup>2</sup> Asya Ekmen, MD, PhD,<sup>2</sup> Benoît Béranger, MSc,<sup>6</sup> Romain Valabregue, PhD,<sup>6</sup> Cécile Hubsch, MD, PhD,<sup>7</sup> Sophie Sangla, MD,<sup>8</sup> Cécilia Bonnet, MD PhD,<sup>2</sup> Cécile Delorme, MD,<sup>3,4</sup> Aurélie Méneret, MD, PhD,<sup>2,3</sup> Bertrand Degos, MD, PhD,<sup>9,10</sup> Floriane Bouquet, MD,<sup>4</sup> Marion Apoil Brissard, MD,<sup>11</sup> Marie Vidailhet, MD,<sup>2,3,4</sup> Dominique Hasboun, MD,<sup>2,4</sup> Pierre Pouget, PhD,<sup>2</sup> Yulia Worbe, MD PhD,<sup>2,4,5†</sup> and Cécile Gallea, PhD<sup>2†\*</sup>

**ABSTRACT: Background:** Cervical dystonia is characterized by abnormal neck and head movements, possibly related to a dysfunction of the interstitial nucleus of Cajal (INC) and the head neural integrator, a system responsible for the control of head and eye movements. However, neuroanatomical evidence of alterations in the head neural integrator in cervical dystonia is sparse.

**Objectives:** We investigated structural and functional integrity of the INC and its connections in cervical dystonia.

**Methods:** This cross-sectional, observational study compared 19 cervical dystonia patients and 21 healthy controls, using anatomical, diffusion-weighted, and resting-state functional images. We reconstructed tracts converging on the INC, and involved in the control of head movements. We evaluated group differences in microstructural integrity using fixel-based analysis, and effective connectivity using dynamic causal modeling.

**Results:** Compared with controls, patients showed microstructural abnormalities within the INC and cerebral peduncle. Effective connectivity showed abnormal self-inhibition in the INC, substantia nigra, and vermis in patients, with decreased excitation from the substantia nigra to the INC, increased inhibition from the deep cerebellar nuclei and primary sensorimotor cortex, and decreased excitation from the INC to the cerebellar vermis.

**Conclusions:** A dysfunction of the INC might contribute to altered sensorimotor integration in cervical dystonia, and abnormal feedback from its afferent connections could alter its integrative function, resulting in a disturbed head and neck posture. © 2025 The Author(s). *Movement Disorders* published by Wiley Periodicals LLC on behalf of International Parkinson and Movement Disorder Society.

**Key Words:** interstitial nucleus of Cajal; fixel-based analysis; dynamic casual models; brainstem

Cervical dystonia (CD) is a focal form of dystonia, characterized by sustained or intermittent neck movements, resulting in abnormal posture of head, neck,

and/or shoulders.<sup>1,2</sup> CD is considered a large-scale-network disorder, and includes nodes in the brainstem,<sup>3-5</sup> the basal ganglia,<sup>6,7</sup> the sensorimotor and

<sup>1</sup>Swiss Paraplegic Research, Nottwil, Switzerland; <sup>2</sup>Movement Investigation and Therapeutics Team, Sorbonne Université, INSERM U1127, CNRS UMR 7225, Paris Brain Institute, Paris, France; <sup>3</sup>Assistance Publique – Hôpitaux de Paris, DMU Neurosciences, Paris, France; <sup>4</sup>Department of Neurology, Assistance Publique – Hôpitaux de Paris, Pitié-Salpêtrière Hospital, Paris, France; <sup>5</sup>Department of Neurophysiology, Saint-Antoine Hospital, Assistance Publique – Hôpitaux de Paris – Sorbonne University, Paris, France; <sup>6</sup>Center for Neuroimaging Research (CENIR), Paris Brain Institute, Sorbonne University, UPMC Univ Paris 06, Inserm U1127, CNRS UMR 7225, Paris, France; <sup>7</sup>Service de Neurologie, CHUV Lausanne, Lausanne, Switzerland; <sup>8</sup>Service de Neurologie, Hôpital de la Fondation Rothschild, Paris, France; <sup>9</sup>Neurology Unit, AP-HP, Avicenne University Hospital, Bobigny, France; <sup>10</sup>Center for Interdisciplinary Research in Biology, Collège de France, CNRS UMR7241/INSERM U1050, Université PSL, Paris, France; <sup>11</sup>Polyclinique du Parc, Université de Caen Normandie, Caen, France

This is an open access article under the terms of the [Creative Commons Attribution-NonCommercial-NoDerivs](#) License, which permits use and distribution in any medium, provided the original work is properly cited, the use is non-commercial and no modifications or adaptations are made.

\*Correspondence to: Drs. Emmanuel Roze and Cécile Gallea, Paris Brain Institute (ICM) – Salpêtrière Hospital, 4783 Boulevard de l'Hôpital, 75013 Paris, France; E-mail: [emmanuel.roze@aphp.fr](mailto:emmanuel.roze@aphp.fr) and [cecile.gallea.icm@gmail.com](mailto:cecile.gallea.icm@gmail.com)

†These authors contributed equally to this work.

**Relevant conflicts of interest/financial disclosures:** This work was funded by the Swiss National Science Foundation (P400PM\_183958 and P5R5PM\_203160/1), AMADYS, Fondation Brou de Laurière, Merz-Pharma. This project was also supported by Agence Nationale de la Recherche (ANR) under the framework of the European Joint Programme on Rare Diseases (EJP RD, ANR-16-CE37-0003-03). The authors declare no conflicts of interest.

**Funding agency:** This work was funded by the Swiss National Science Foundation (P400PM\_183958 and P5R5PM\_203160/1), AMADYS, Fondation Brou de Laurière, Merz-Pharma. This project was also supported by Agence Nationale de la Recherche (ANR) under the framework of the European Joint Programme on Rare Diseases (EJP RD, ANR-16-CE37-0003-03).

**Received:** 26 April 2025; **Revised:** 28 June 2025; **Accepted:** 4 August 2025

Published online in Wiley Online Library ([wileyonlinelibrary.com](http://wileyonlinelibrary.com)). DOI: 10.1002/mds.70014

frontoparietal regions, the insula, and the cerebellum.<sup>6,8</sup> In parallel, CD has been linked to a dysfunction of the head neural integrator, a system by which eye and head movements are coordinated through the integration of gaze velocity signals into tonic position commands.<sup>9,10</sup> In particular, the interstitial nucleus of Cajal (INC) represents a central hub of the head neural integrator, processing information from spinal, subcortical, and cortical areas to control head and eye movements.<sup>11,12</sup> The INC lays in the brainstem within the medial longitudinal fasciculus (MLF), and is part of the reticular formation, ventrolateral to the periaqueductal gray matter in the rostral part of the midbrain.<sup>12</sup> Studies in animals and humans have confirmed that the INC influences the control of the head,<sup>13</sup> vertical and torsional eye movements, and vestibulo-ocular responses.<sup>14-18</sup>

Early research in CD patients has shown that vertical head movements and contraction of the neck muscles can be modulated by electrical stimulation of the INC.<sup>12</sup> Electrical recording of INC neurons in CD patients has suggested that the oculomotor function is normal in CD, whereas combined head-eye movement is defective, possibly due to abnormal head turning, which could interfere with saccadic function.<sup>3,10</sup>

One attractive hypothesis on the pathogenesis of CD is that abnormal feedback from the cerebellum, basal ganglia, or cerebral cortex converging on the head neural integrator can alter its integrative function and subsequent generation of the motor program. Alternatively, an intrinsic dysfunction of the INC and disrupted communication with structures involved in its efferent pathways could explain the defective head neural integrator in CD.<sup>13,19-23</sup>

Indeed, the INC receives afferent fibers from the deep cerebellar nuclei,<sup>24</sup> cortical regions such as the frontal eye field (FEF), the supplementary motor area (SMA), and the sensorimotor cortex, as well as the substantia nigra (SN).<sup>12</sup> Studies have further postulated that abnormal activity of lateral cerebellar lobules and dentate nucleus in CD could affect the feedback system that stabilizes gaze during head movements.<sup>6,15,19,25,26</sup> Likewise, abnormal integration of the neck proprioceptive information at the cerebellar level could partially explain the mechanisms of CD.<sup>27</sup> CD patients also show functional and structural abnormalities in widespread cortical networks involving parietal, motor, and premotor cortices connected with the INC.<sup>6,7,28,29</sup> In particular, head shift has been associated with structural and functional changes in the FEF and of the head/trunk representation areas in the sensorimotor cortex.<sup>5,30</sup> There is also evidence that the nigro-brainstem pathway might functionally contribute to symptoms in CD.<sup>3,31,32</sup>

The mechanisms leading to dysfunction of the head neural integrator in CD, whether they are associated to INC intrinsic properties or to dysregulation of the INC

connections, are unknown, mostly because technical challenges have hampered direct neuroimaging evidence of structural or functional dysfunctions of the INC.

Here, after careful localization of the INC through a systematic pipeline, we investigated morphometry of white matter fibers in the circuitry of the head neural integrator using fixel-based analysis (FBA), as well as effective connectivity using dynamic causal modeling (DCM) on resting-state functional magnetic resonance imaging (fMRI). We hypothesized that, compared with healthy controls (HC), CD patients show abnormalities in the INC and its circuitry, at both structural and functional levels.

## Methods

### Subjects and General Procedure

Nineteen CD patients (7 males, mean age =  $47.3 \pm 8.6$  years) and 21 HC (9 males, mean age =  $45.3 \pm 10.6$  years) participated in this cross-sectional, observational study. We included patients with a diagnosis of idiopathic CD, no botulinum toxin injection (BoT) within 3 months prior to the examination, and stable pharmacological treatment for at least 1 month prior to the experiment. We excluded participants with: (i) a neurological disorder other than CD, (ii) any secondary etiology of CD, and (iii) incompatibility with MR environment. All patients performed the Toronto Western Spasmodic Torticollis Rating Scale (TWSTRS), subscale for severity, at the time of inclusion to assess symptom severity.<sup>33</sup> Between-group differences in age were assessed with independent-sample *t*-tests, and differences in the ratio between male and female participants were assessed with  $\chi^2$  tests.

During the MR session, participants lay still in the scanner while fixating a cross displayed on a screen. Eye-tracking was employed to monitor their gaze. We acquired diffusion-weighted imaging (DWI), resting-state fMRI, and one structural image in one single session with a 3 T Magnetom Prisma (Siemens, DE) and a 64-channel head coil. Detailed acquisition parameters and preprocessing steps are included as Supplementary Material and Supplementary Figure S1.

The study was carried out in accordance with the latest version of the Declaration of Helsinki and approved by the local Ethics Committee (approval number: C17-04-AU1360, [ClinicalTrials.gov](https://clinicaltrials.gov) ID: NCT03351218). All participants gave their written informed consent prior to inclusion.

### Localization of the Interstitial Nucleus of Cajal

The exact delineation of the INC was done together with an experienced neuroanatomist (D.H.), by using anatomical landmarks, and then verified by two independent procedures.

We first used the Atlas of the Human Brainstem as the template for the identification of the INC.<sup>34</sup> In the atlas, we measured the total length from the obex to the meso-diencephalic junction, which was 64 mm, and searched for the INC on each plane along the vertical line. The INC was visible from the plane obex+41 mm to obex+47 mm (Supplementary Table S1).

We then considered the T1-weighted images in MNI space and realigned them to the sagittal plane with the obex, the floor of the fourth ventricle, and the posterior commissure (Fig. 1A). In this way, the T1-weighted images and the brainstem atlas presented the same orientation. We then imported the realigned T1-weighted images into Mango (Research Imaging Institute, University of Texas, San Antonio, TX, USA), and set the reference point at the tip of the obex in the midsagittal plane. For each histological plane, we chose the nearest MR axial planes of the atlas between obex+41 mm to obex+47 mm, and selected obex+45 mm as the best slice. After superimposing the atlas regions over the T1-weighted images (Fig. 1B), the INC was localized in the upper midbrain, at the level of the superior colliculus, below the rostral interstitial nucleus of the MLF, at the level of the upper part of the red parvocellular nucleus.

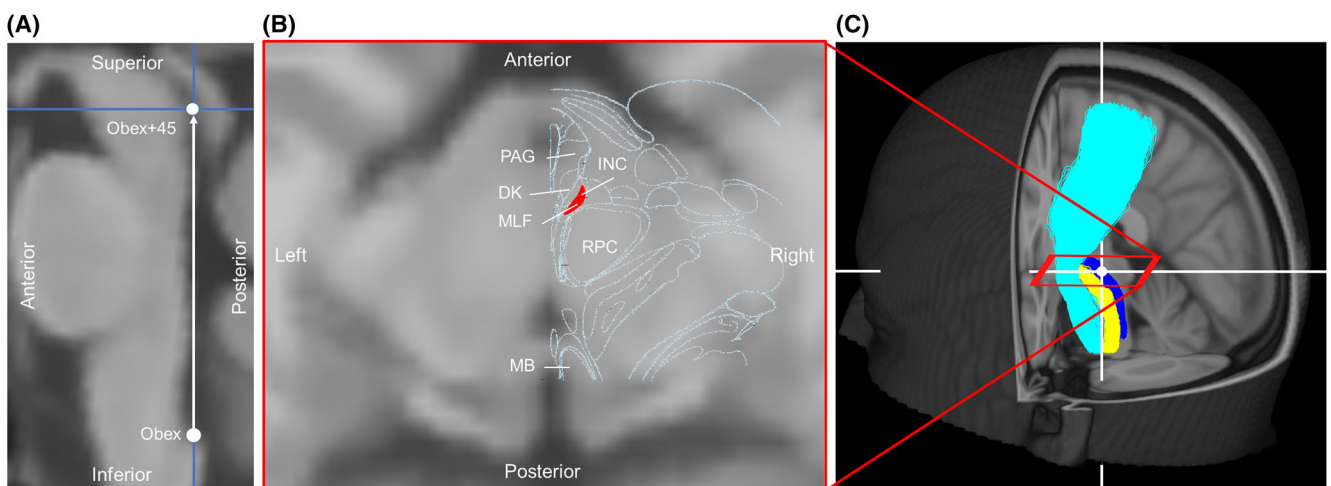
With the first verification method, we checked that the INC was intermingled with the MLF (Fig. 1C, see also Supplementary Material for detailed extraction of the MLF). With the second verification method, we checked that it was ventrolateral to the nucleus of Darkschewitsch and dorsolateral to the red parvocellular nucleus.

### Fixel-Based Analysis (FBA)

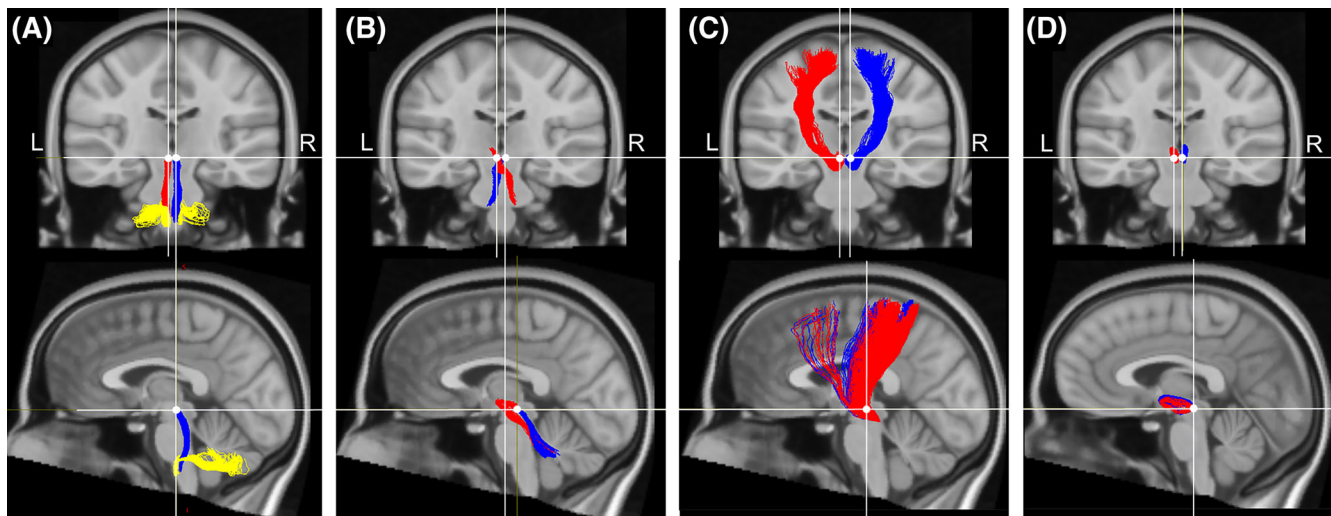
In order to define the tracts of interest (TOIs) of the head neural integrator, we reconstructed the white

matter fibers passing through the INC from the whole-brain tractogram, based on existing literature in animal and human research.<sup>12,35</sup> We then isolated seven tracts responsible for eye and head control: (i) a tract connecting the right and left INC to the cerebellar vermis, flocculus and para-flocculus, passing through the inferior olive and the inferior cerebellar peduncle (Fig. 2A),<sup>36,37</sup> (ii) two tracts connecting the right and left INC to the contralateral dentate and fastigial nuclei of the cerebellum, respectively, through the superior cerebellar peduncle (Fig. 2B),<sup>35,38</sup> (iii) two tracts connecting the right and left INC to the ipsilateral FEF, SMA, and neck representation area of the sensorimotor cortex, respectively, through the cerebral peduncle (Fig. 2C), and (iv) two tracts connecting the left and right INC to the ipsilateral SN (Fig. 2D; see details on the employed regions of interest – ROIs – in the Supplementary Material and Supplementary Fig. S2).<sup>39,40</sup> Other INC connections not involved in eye and head movement were not extracted. To verify the specificity of the INC tracts, we reconstructed the neighboring medial lemniscus, corticospinal and cerebellothalamic tracts, and verified that no overlap existed between these tracts and the INC ones. (Supplementary Fig. S3). For each voxel of the INC, we considered a 5000-fiber streamline with the following tracking parameters: step size = 0.5 mm, maximum trace length = 100 mm, and maximum angle between successive steps = 45°. <sup>41</sup> We then binarized the identified tracts, merged them in one single TOI, and consider that as the actual TOI for the statistical analyses.

We investigated white matter fiber-specific differences between CD patients and HC with FBA.<sup>42</sup> We extracted fiber density (FD) and fiber bundle cross-section (FC), as indicators of the within-voxel intra-



**FIG. 1.** Localization of the interstitial nucleus of Cajal (INC). (A) Sagittal view. (B) Axial view at Obex+45. (C) Three-dimensional (3D) visualization of the INC within the medial longitudinal fasciculus (MLF). The MLF is depicted in dark blue, the medial lemniscus in yellow, and the corticospinal tract in light blue. White crosshairs indicate the INC, and the red box indicates the axial view in 3D. PAG, periaqueductal grey; DK, nucleus of Darkschewitsch; RPC, red parvocellular nucleus; MB, mamillary body. [Color figure can be viewed at [wileyonlinelibrary.com](http://wileyonlinelibrary.com)]



**FIG. 2.** Tractography of the interstitial nucleus of Cajal (INC) and definition of the tracts of interest (TOIs). (A) Efferent tract from the bilateral INC to the cerebellar vermis and flocculus. (B) Afferent tracts from the cerebellar dentate and fastigial nuclei to the contralateral INC. (C) Afferent tracts from the frontal eye field (FEF), supplementary motor area (SMA), and neck representation area of the somatosensory cortex to the ipsilateral INC. (D) Afferent tracts from the bilateral substantia nigra to the ipsilateral INC. Crosshairs indicate the INC. Tracts through the right INC are depicted in blue, tracts through the left INC are depicted in red, and climbing fibers from the bilateral olive to the cerebellar flocculus, para-flocculus, and vermis are depicted in yellow. [Color figure can be viewed at [wileyonlinelibrary.com](http://wileyonlinelibrary.com)]

axonal volume of a fiber bundle and between-voxel intra-axonal volume of the fiber bundle, respectively. We also computed a third measure combining FD and FC (ie, FDC). We performed connectivity-based smoothing and statistical inference with connectivity-based fixel enhancement (CFE), using 2 million streamlines,  $C = 0.5$ ,  $E = 2$ ,  $H = 3$ , and smoothing = 10 mm full width at half maximum.<sup>43</sup> Finally, we implemented a general linear model (GLM) testing statistical differences between CD patients and HC in FD, FC, and FDC, respectively, in the defined TOIs. We included total intracranial volume (TIV), age and sex as nuisance regressors, and used family-wise error (FWE) to correct for multiple comparisons ( $p_{\text{corrected}} < 0.050$ ).<sup>44</sup>

### Dynamic Casual Modeling (DCM)

We studied the effective connectivity with dynamic casual modeling (DCM), and addressed directionality of information across regions connected to the INC. ROIs, as defined in the FBA and transformed into MNI space (see Supplementary Fig. S4), included the merged left and right INC ( $n = 20$  voxels) to ensure sufficient BOLD signal resolution. ROIs were sorted into those sending information to the INC (ie, SMA, FEF, SN, deep cerebellar nuclei, and neck/trunk representation in the primary sensorimotor regions, as identified from the Brainnetome Atlas<sup>45</sup> and previous research<sup>30</sup>), and those receiving information from the INC (ie, bilateral cerebellar vermis, flocculus, and para-flocculus). BOLD signals were extracted as the first eigenvariate of the voxels within each region. Using parametric empirical Bayes (PEB) methodology, we determined the direction and strength of excitatory

and inhibitory connections.<sup>46-48</sup> We defined different models based on the categories of ROIs. All the models included the bilateral INC. Models of afferent connections to the INC were based on the laterality of anatomical connections converging on the INC, with a maximum of four input ROIs. For instance, we included in the same model the left cortical (associative and primary somatosensory) areas, left SN, and the right deep cerebellar nuclei, and entered the right cortical areas, right SN, and left deep cerebellar nuclei in a separate model. The model of efferent connections from the INC included the vermis, flocculus, and paraflocculus.

For each analysis (ie, two cortical afferents, two cerebellar afferents, and one cerebellar efferent, respectively), the PEB model tested both the commonalities across all participants and between-group differences. All models included framewise displacement as covariate to account for potential influence of head movements. Then, we used a data-driven approach (ie, automatic search) over connection parameters to remove any parameters from the PEB not contributing to the model (ie, the commonalities across participants and between-group differences). The parameter values from the final iteration of the search were averaged and weighted by their model evidence (Bayesian model averaging) considering all participants.<sup>36</sup>

Finally, we extracted two measures from the resting-state effective connectivity: intrinsic connectivity and coupling parameter between nodes. The former, also referred to as self-inhibition, is a marker of internal instability of a region, reflecting how sensitive a region is to afferent inputs. The latter reflects how one area

drives the activity of another in a positive or negative manner, termed excitatory for positive parameters and inhibitory for negative parameters. We report estimated parameters with a high level of evidence (posterior probability,  $P > 0.95$ ) based on free energy.<sup>36</sup>

## Results

### Population

No significant differences were found in age, cognitive abilities, and sex ratio between male and female participants (Table 1). Thirteen patients suffered from torticollis as a major clinical presentation, four from lateral shift and two from laterocollis. Seven patients showed right laterality of head position. A detailed description of the clinical presentation is displayed in Supplementary Table S2.

### Fixel-Based Analysis (FBA)

The results of FBA evidenced significant differences between CD patients and HC. The tracts from the right and left sensorimotor and premotor regions towards the ipsilateral INC showed decreased FDC in CD patients, within the bilateral INC proper ( $P_{\text{corrected}} = 0.046$ ), and within the bilateral cerebral peduncle ( $P_{\text{corrected}} = 0.038$ , Fig. 3). Similarly, CD patients showed reduced FD in the bilateral cerebral peduncle ( $P_{\text{corrected}} = 0.044$ ). These abnormalities were located in white matter fibers that specifically connect the cerebral cortex and the INC, as they did not overlap with the corticospinal tract and the cerebellothalamic tract (see Supplementary Fig. S3).

### Dynamic Casual Modeling (DCM)

The results of DCM evidenced significant differences between CD patients and HC in the effective connectivity (Supplementary Tables S3–S5). Commonalities are displayed in Figure 4A,C and show the results of the

baseline characteristics of connectivity parameters. Based on these commonalities, we can infer on the group differences (increase or decrease) displayed in Figure 4B,D. Effective connectivity showed group differences in both self-inhibition and coupling parameters. Compared with controls, patients had decreased self-inhibition of the INC and SN, but increased self-inhibition of the associative frontal cortex and the vermis (see short curved arrows in Fig 4B and 4D). In addition, patients showed increased inhibitory connection from areas sending information to the INC (i.e., from the deep cerebellar nuclei and the left primary sensorimotor cortex). Patients showed decreased excitatory connection from the bilateral SN to the INC (Fig. 4B). Lastly, patients showed decreased excitatory connection from the INC to the cerebellar vermis (Fig. 4D).

## Discussion

Compared with HC, CD patients showed microstructural abnormalities, namely decreased FD and FDC, in the INC and within the cerebral peduncles connecting motor and premotor regions to the INC. Patients also showed lower self-inhibition in the INC and SN, as well as higher self-inhibition in the cerebellar vermis and associative frontal areas. Moreover, cerebellar, SN, and primary sensorimotor connections had abnormal modulatory drive on the INC, and the INC showed abnormal modulatory drive on the cerebellar vermis. Our findings bring experimental evidence in humans supporting an important role of the head neural integrator in the pathogenesis of CD.

Localizing the INC is challenging, due to its small size and position within the midbrain.<sup>12</sup> Based on a-priori neuroanatomical knowledge, we propose a pipeline to identify its location. Using a well-known atlas,<sup>34</sup> we defined precise anatomical landmarks, such as the obex and the fourth ventricle to isolate the axial plane containing the INC, as well as the nucleus of

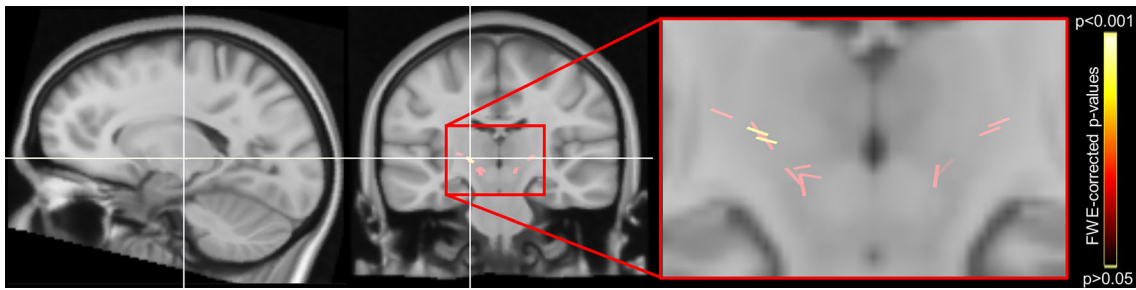
**TABLE 1** Study participants' clinical and demographic information.

Parameter	CD (N = 19)	HC (N = 21)	Statistics
Sex (male/female)	7/12	9/12	$\chi(1) = 0.15, P = 0.698$
Age (years), mean $\pm$ SD	47.3 $\pm$ 8.6	45.3 $\pm$ 10.6	$t(38) = 0.66, P = 0.512$
WAIS-IV	116.3 $\pm$ 5.6	116.3 $\pm$ 4.8	$t(38) = 0.02, P = 0.984$
BDI	3.7 $\pm$ 4.3	0.9 $\pm$ 1.3	$t(38) = 2.84, P = 0.007$
TWSTRS	18.0 $\pm$ 4.3	–	–
Overall medication, n (% of CD)	19 (100%)	–	–
BoT, n (% of CD) <sup>a</sup>	17 (89.5%)	–	–

Note: Comparison of clinical and demographic scores between groups.

Abbreviations: BoT, botulinum toxin injection; BDI, Beck Depression Inventory; CD, cervical dystonia; HC, healthy controls; SD, standard deviation; TWSTRS, Toronto Western Spasmodic Torticollis Rating Scale; WAIS, Wechsler Adult Intelligence Scale.

<sup>a</sup>Last botulinum toxin injection administered at least 3 months prior to the experiment.

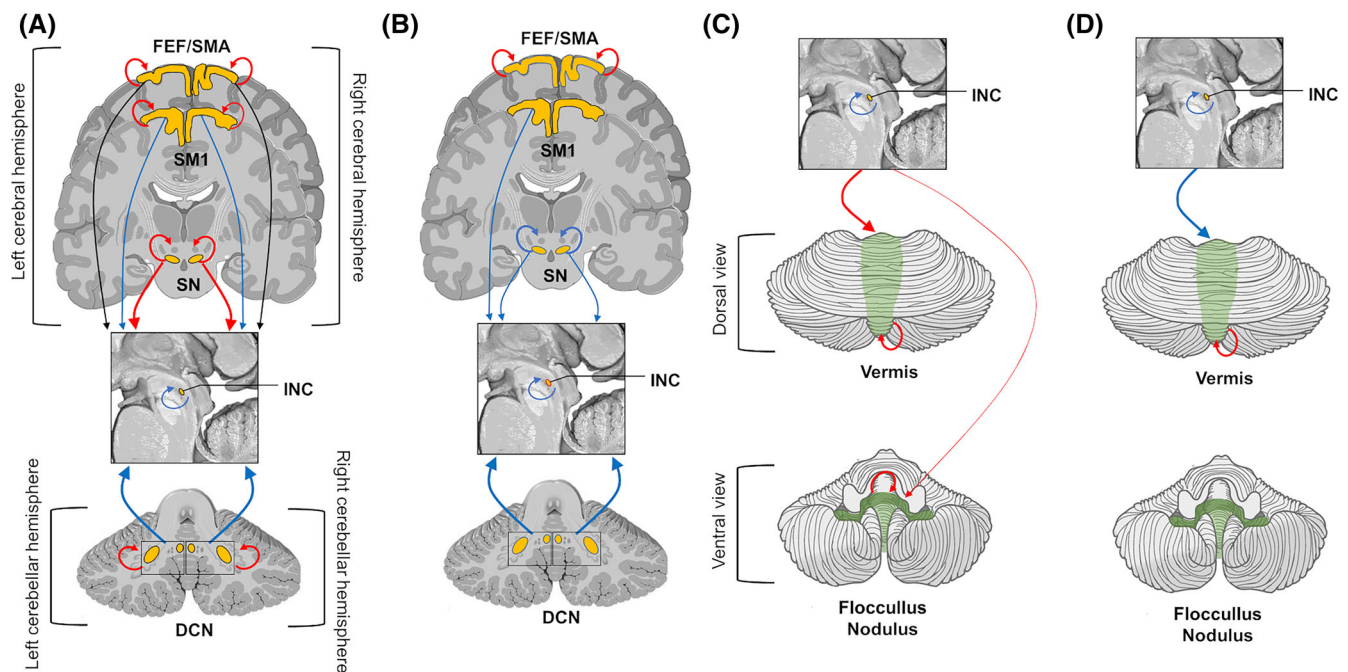


**FIG. 3.** Results of fixel-based analysis. Reduced FDC (a measure combining fiber density and fiber bundle cross-section) in patients in the cerebral peduncle, bilaterally. Crosshairs indicate the peak of the significant differences. Clusters represent the *P*-values corrected for multiple comparisons with family-wise error (FWE). [Color figure can be viewed at [wileyonlinelibrary.com](http://wileyonlinelibrary.com)]

Darkschewitsch, the red parvocellular nucleus, and the superior colliculus for the in-plane localization of the INC. Next, we confirmed the INC localization by reconstructing the MLF based on independent procedures described in the literature and verified its overlap with the INC.<sup>12</sup> We used a combination of cutting-edge methods (ie, FBA and DCM) to investigate the head neural integrator network and its dysfunction in CD. More precise than standard voxel-based methods, FBA enables the investigation of microstructural properties of white matter fibers, such as direction within a fiber bundle connecting distant brain areas.<sup>49,50</sup> For instance, the differences observed in the cerebral peduncle were likely due to a smaller number of axons or the

presence of smaller axons (ie, reduced FD), or a combination of smaller axons and axonal shrinkage (ie, reduced FDC).<sup>42</sup> Complementarily, DCM brought valuable insights on the INC afferent and efferent connections, and on the sensitivity of a specific brain area to its afferent input.<sup>46</sup>

Some limitations should be mentioned. We cannot reliably distinguish causal, compensatory, and epiphenomenal mechanisms across networks.<sup>7</sup> Of note, we considered excitatory/inhibitory connections in the context of DCM (ie, when a given region negatively drove the activity of the other region).<sup>51</sup> However, we cannot infer causal relationships at the neurophysiological level (ie, on the effect one neuron has on the firing activity of



**FIG. 4.** Results of dynamic causal modeling (DCM) analysis. (A–B). Models with afferent connections to the interstitial nucleus of Cajal (INC). (C–D) Model with efferent connections from the INC. (A) and (C) display the main effect of the connection, from the model averaging over the whole study population. (B) and (D) display the group difference with *P* > 0.95. Red arrows display positive coupling parameters termed excitatory connections. Blue arrows display negative coupling parameters termed inhibitory connections. The arrow thickness coded for the strength of coupling parameters. For details on the coupling strength see Supplementary Table S2. FEF, frontal eye field; SMA, supplementary motor area; SM1, primary sensorimotor cortex; SN, substantia nigra. [Color figure can be viewed at [wileyonlinelibrary.com](http://wileyonlinelibrary.com)]

another).<sup>52</sup> In addition, we did not verify the INC location using an eye-movement paradigm or vibration stimulation over the neck during task-based fMRI. This would have been possible with a 7 T scanner rather than the 3 T scanner used in the present study. Future research may examine the specific activity of the INC with such task-based fMRI experiments. It is worth noting that even though CD is mainly a disorder of head posture, the activity of the head neural integrator is tightly related to the control of saccadic eye movements,<sup>53</sup> though our study design did not include behavioral measures of eye movements.

Prior research has investigated head movements in CD, and has suggested that the abnormal neck posture could be explained by deficient activity of the INC circuitry.<sup>20</sup> However, direct evidence in humans of a role of the INC in CD is missing.<sup>20,54,55</sup> For instance, recording of neurons in cats have shown that the INC receives afferent information from neck proprioceptors, mediating the control of the head,<sup>56,57</sup> and pharmacological deactivation of the INC in monkeys leads to deficits in holding the head still.<sup>17,18</sup> Our findings reveal abnormal microstructural integrity of the INC, complemented by a decrease of INC self-inhibition, in a population of CD patients. Inhibitory input of self-connection controls the gain of regional response to extrinsic connection,<sup>46,58</sup> influencing the decay of synaptic activity<sup>59</sup> and the excitatory/inhibitory balance of a specific region (ie, the less positive the self-connection, the less inhibited the region, and the more this region is sensitive to the inputs from the network,<sup>46</sup> which is what we observed for the INC in CD patients). We suggest that the intrinsic instability of the INC contributes to abnormal processing of the sensorimotor information, which in turn may account for a dysfunction of the head neural integrator.

In addition to an intrinsic INC dysfunction, an impairment of the head neural integrator could be aggravated by an imbalance of its afferent connections.<sup>20</sup> Our results support this hypothesis, as we found that incoming connections from the cerebellum were structurally intact but functionally altered. CD patients had increased inhibitory connection from the deep cerebellar nuclei to the INC, possibly indicating that cerebellar signals sent to the INC could interfere with its integrative functions controlling neck and head position.<sup>60</sup> We suggest that abnormal coupling from the cerebellum to the INC could then be associated with abnormal feedback processing from the neck proprioceptive information in CD patients. In addition, we found decreased excitatory connection from the INC to the vermis in CD patients. The vermis receives somatosensory information on head posture via ascending spinal pathways, as well as cortical information from the medial motor and premotor cortices.<sup>61</sup> We previously demonstrated that the connectivity of the

vermis is altered in CD,<sup>30</sup> and our findings indicate that a dysfunction of the cerebellar-INC connectivity may play a role in the disruption of information processing related to neck sensory input.<sup>62,63</sup>

We also observed increased inhibitory connection from the cortical sensorimotor areas towards the INC in CD patients, which was complemented by reduced FDC in the cerebral peduncle connecting the sensorimotor cortex to the INC. Previous research has consistently found an involvement of the motor areas in CD,<sup>64</sup> and we showed that the white matter fibers of the cerebral peduncle are locally altered in CD in regions specific to INC projections, with no overlap with cerebellothalamic or corticospinal tracts. In addition, we found that self-inhibition was increased in associative frontal areas in CD patients, but this had no impact on information transfer to the INC. This may indicate that the associative frontal regions have more stable intrinsic activity than the sensorimotor ones, hence their efferent connections are less affected. In other words, symptoms of dystonia may arise from a dysfunction of the head neural integrator at the level of cerebellar and primary sensorimotor projections, rather than its associative frontal connections.

We considered the SN as the component of the basal ganglia connected to the head neural integrator and involved in the neck/head posture.<sup>65</sup> CD patients had weaker self-inhibition in the SN, and disrupted connectivity from the SN to the INC. We suggest that reduced input from the SN could have a synergic effect on an intrinsically unstable INC, and produce an abnormal activity during head holding.<sup>10</sup> Other factors that could play a role in the INC instability are the projections carrying proprioceptive information from the spinal cord, such as the spinothalamic tract and the medial lemniscus. However, the connections of these tracts to the INC are not well delineated in humans, and their role in the head neural integrator remains speculative.

Of note, our results did not evidence an effect of laterality of head position in the INC and its connections, which was expected as our sample included patients with mixed right and left tilts. In CD, the neck is physically twisted towards one side of the body, considering the midline as reference. However, a lateral head tilt results from the engagement of both left and right side muscles, and we still miss a robust clinical method to evaluate laterality of CD. Future research may address this topic by stratifying patients with right and left head tilts, which was not possible in the current study due to the small sample size.

In addition, although the investigation of patients with a tremulous or jerky form of CD may be hampered by obvious technical limitations, they represent a large group of patients in clinical practice. Future studies may therefore consider the inclusion of patients encompassing the full phenomenological spectrum of

CD to further examine the contribution of the head neural integrator to the clinical presentation. Similarly, as new avenues on the role of midbrain structures in the pathophysiology of CD emerge, future research may test the hypothesis that CD is related to abnormalities in the superior colliculus, which may disrupt the activity of the midbrain attentional orienting network, and contribute to overt symptoms of dystonia.<sup>3</sup>

In summary, a common mechanism of dystonia is a distorted feedback processing abnormally integrated with motor commands, resulting in dystonic movements. Our findings of structural and functional abnormalities in the head neural integrator in CD patients suggest that midbrain structures, especially the INC, could be a key player in the specific case of CD. We propose that altered feedback from the cortical and cerebellar regions, or from spinal pathways conveying neck proprioceptive information onto the head neural integrator, could alter its integrative function, resulting in a disturbed head and neck posture. Alternatively, the structural and functional changes in the INC could reflect an attempt to compensate aberrant afferent input accompanying the dystonic movements. ■

**Author Roles:** (1) Research Project: A. Conception, B. Organization, C. Execution; (2) Statistical Analysis: A. Design, B. Execution, C. Review and Critique; (3) Manuscript Preparation: A. Writing of the First Draft, B. Review and Critique. G.A.Z.: 2A, 2B, 2C, 3A, 3B.

E.R.: 1A, 1B, 2C, 3A, 3B.

C.T.: 1C, 3B.

S.O.: 2A, 2B, 2C, 3B.

P.J.: 1C, 3B.

A.E.: 1C, 3B.

B.B.: 2A, 2B, 2C, 3B.

R.V.: 2A, 2B, 2C, 3B.

C.H.: 1C, 3B.

S.S.: 1C, 3B.

C.B.: 1C, 3B.

C.D.: 1C, 3B.

A.M.: 1C, 3B.

B.D.: 1C, 3B.

F.B.: 1C, 3B.

M.A.B.: 1C, 3B.

M.V.: 1A, 1B, 1C, 3B.

D.H.: 2C, 3B.

P.P.: 1A, 1B, 3B.

Y.W.: 1A, 1B, 2A, 2B, 2C, 3A, 3B.

C.G.: 1A, 1B, 2A, 2B, 2C, 3A, 3B.

**Acknowledgments:** The authors would like to acknowledge the Swiss Paraplegic Research, AMADYS Foundation, Merz-Pharma, E-rare Eurodycover, the Paris Brain Institute, and the University Hospitals Pitié-Salpêtrière for support. They would also like to thank all the study participants.

**Full Financial Disclosure for All Authors (for the Previous 12 Months):** G.A.Z. is supported by the Swiss Paraplegic Research and the Research Committee of the Swiss Paraplegic Foundation. E.R. received honoraria for presentations from Orkyn, Aguetant, Elivie, Merz-Pharma, and Janssen, and for participating in advisory boards from Merz-Pharma, Elivie, Teva, and BIAL. He received research support from Merz-Pharma, Orkyn, Elivie, Everpharma, AMADYS, ADCY5.org, Dystonia Medical Research Foundation, Hope For Annabel, Cure Alternating Hemiplegia of Childhood Alternating Hemiplegia of Childhood Foundation, Alternating Hemiplegia of Childhood Association of Iceland Association française de l'hémiplégie alternante, and Alternating Hemiplegia of Childhood Kids of Netherlands. C.T. received a PhD grant from the 'Fondation pour la Recherche Médicale'. B.B. is supported by the Paris Brain Institute. C.D. received a research grant from the Fondation de France (grant number

00113315) and travel grants from Medtronic, Boston Scientific, and Merz-Pharma. A.M. received a travel grant from Merz. B.D. received research support from Merz-Pharma, Orkyn, and Elivie; received honoraria for presentations from Ipsen and Merz-Pharma, and for participating in advisory boards from Merz-Pharma and Orion; and received travel grants from Adelia, Orkyn, and Merz-Pharma. M.V. received honorarium from MDS and EAN and grants/research support from patients' associations (tremor, APTES; dystonia, Dystonia Coalition; and AMADYS, PSP France, France Parkinson) and research foundation FRM (Medical Research Foundation). Y.W. received research support from Agence Nationale de la Recherche, Dystonia Medical Research Foundation, and Fondation de France; and has received travel grants from Merz-Pharma and the European Society for the Study of Tourette Syndrome (ESSTS) (ANR-22-RAR4-000).

## Data Availability Statement

The data supporting the findings of this study are available from the corresponding author upon reasonable request.

## References

- Kilic-Berkmen G, Wright LJ, Perlmutter JS, et al. The dystonia coalition: a multicenter network for clinical and translational studies. *Front Neurol* 2021;12:660909.
- Albanese A, Bhatia KP, Cardoso F, et al. Isolated cervical dystonia: diagnosis and classification. *Mov Disord* 2023;38(8):1367–1378.
- Hutchinson M, Isa T, Molloy A, et al. Cervical dystonia: a disorder of the midbrain network for covert attentional orienting. *Front Neurol* 2014;5:54.
- Blood AJ, Kuster JK, Woodman SC, et al. Evidence for altered basal ganglia-brainstem connections in cervical dystonia. *PLoS One* 2012;7(2):e31654.
- Prell T, Peschel T, Köhler B, Bokemeyer MH, Dengler R, Günther A, Grosskreutz J. Structural brain abnormalities in cervical dystonia. *BMC Neurosci* 2013;14(1):1–14.
- Prudente CN, Hess EJ, Jinnah H. Dystonia as a network disorder: what is the role of the cerebellum? *Neuroscience* 2014;260:23–35.
- Quartarone A, Hallett M. Emerging concepts in the physiological basis of dystonia. *Mov Disord* 2013;28(7):958–967.
- Burciu RG, Hess CW, Coombes SA, et al. Functional activity of the sensorimotor cortex and cerebellum relates to cervical dystonia symptoms. *Hum Brain Mapp* 2017;38(9):4563–4573.
- Berardelli A, Rothwell J, Hallett M, Thompson P, Manfredi M, Marsden C. The pathophysiology of primary dystonia. *Brain* 1998;121(7):1195–1212.
- Sedov A, Popov V, Shabalov V, Raeva S, Jinnah HA, Shaikh AG. Physiology of midbrain head movement neurons in cervical dystonia. *Mov Disord* 2017;32(6):904–912.
- Dalezios Y, Scudder C, Highstein S, Moschovakis A. Anatomy and physiology of the primate interstitial nucleus of Cajal. II. Discharge pattern of single efferent fibers. *J Neurophysiol* 1998;80(6):3100–3111.
- Fukushima K. The interstitial nucleus of Cajal and its role in the control of movements of head and eyes. *Prog Neurobiol* 1987;29(2):107–192.
- Fukushima K, Takahashi K, Fukushima J, Ohno M, Kimura T, Kato M. Effects of lesion of the interstitial nucleus of Cajal on vestibular nuclear neurons activated by vertical vestibular stimulation. *Exp Brain Res* 1986;64:496–504.
- Kokkoroyannis T, Scudder C, Balaban C, Highstein S, Moschovakis A. Anatomy and physiology of the primate interstitial nucleus of Cajal I. Efferent projections. *J Neurophysiol* 1996;75(2):725–739.
- Yu M, Wang S-M. *Neuroanatomy, Interstitial Nucleus of Cajal*. Tampa, Florida: StatPearls, 2019.
- Farshadmanesh F, Byrne P, Keith GP, Wang H, Corneil BD, Crawford JD. Cross-validated models of the relationships between neck muscle electromyography and three-dimensional head kinematics during gaze behavior. *J Neurophysiol* 2012;107(2):573–590.

17. Farshadmanesh F, Klier EM, Chang P, Wang H, Crawford JD. Three-dimensional eye-head coordination after injection of muscimol into the interstitial nucleus of Cajal (INC). *J Neurophysiol* 2007;97(3):2322–2338.
18. Klier EM, Wang H, Constantin AG, Crawford JD. Midbrain control of three-dimensional head orientation. *Science* 2002;295(5558):1314–1316.
19. Morigaki R, Miyamoto R, Matsuda T, Miyake K, Yamamoto N, Takagi Y. Dystonia and cerebellum: from bench to bedside. *Life* 2021;11(8):776.
20. Shaikh AG, Zee DS, Crawford JD, Jinnah HA. Cervical dystonia: a neural integrator disorder. *Brain* 2016;139(10):2590–2599.
21. Tang Q, Ni L, Xu X, Chen H, Hu X. Etiology and Pathophysiology of Cervical Dystonia.
22. Draganski B, Thun-Hohenstein C, Bogdahn U, Winkler J, May A. “Motor circuit” gray matter changes in idiopathic cervical dystonia. *Neurology* 2003;61(9):1228–1231.
23. Obermann M, Yaldizli O, De Greiff A, et al. Morphometric changes of sensorimotor structures in focal dystonia. *Mov Disord* 2007;22(8):1117–1123.
24. Novello M, Bosman LW, de Zeeuw CI. A systematic review of direct outputs from the cerebellum to the brainstem and diencephalon in mammals. *Cerebellum* 2024;23(1):210–239.
25. Aïssa HB, Sala RW, Margarint ELG, et al. Functional abnormalities in the cerebello-thalamic pathways in a mouse model of DYT25 dystonia. *elife* 2022;11:e79135.
26. Prudente CN, Stilla R, Singh S, et al. A functional magnetic resonance imaging study of head movements in cervical dystonia. *Front Neurol* 2016;7:201.
27. Popa T, Hubsch C, James P, et al. Abnormal cerebellar processing of the neck proprioceptive information drives dysfunctions in cervical dystonia. *Sci Rep* 2018;8(1):2263.
28. Battistella G, Termsarasab P, Ramdhani RA, Fuertinger S, Simonyan K. Isolated focal dystonia as a disorder of large-scale functional networks. *Cereb Cortex* 2015;27(2):bhv313.
29. de Vries PM, Johnson KA, de Jong BM, Gieteling EW, Bohning DE, George MS, Leenders KL. Changed patterns of cerebral activation related to clinically normal hand movement in cervical dystonia. *Clin Neurol Neurosurg* 2008;110(2):120–128.
30. Zito GA, Tarrano C, Jegatheesan P, et al. Somatotopy of cervical dystonia in motor-cerebellar networks: evidence from resting state fMRI. *Parkinsonism Relat Disord* 2022;94:30–36.
31. Burbaud P, Bonnet B, Guehl D, Lagueny A, Bioulac B. Movement disorders induced by gamma-aminobutyric agonist and antagonist injections into the internal globus pallidus and substantia nigra pars reticulata of the monkey. *Brain Res* 1998;780(1):102–107.
32. Holmes AL, Forcelli PA, DesJardin JT, et al. Superior colliculus mediates cervical dystonia evoked by inhibition of the substantia nigra pars reticulata. *J Neurosci* 2012;32(38):13326–13332.
33. Consky E, Basinski A, Belle L, Ranaway R, Lang A. The Toronto Western spasmodic torticollis rating scale (TWSTRS): assessment of validity and inter-rater reliability. *Neurology* 1990;40(suppl 1):445.
34. Paxinos G, Xu-Feng H, Sengul G, Watson C. Organization of Brainstem Nuclei. Amsterdam, The Netherlands: The Human Nervous System; 2012.
35. Prati JM, Pontes-Silva A, Gianlorenço ACL. The cerebellum and its connections to other brain structures involved in motor and non-motor functions: a comprehensive review. *Behav Brain Res* 2024;465:114933.
36. S JA. Anatomy and Physiology of Ocular Motor Systems. Baltimore, Maryland: Walsh and Hoyt’s clinical Neuro-Ophthalmology; 2004.
37. Sanchez K, Rowe FJ. Role of neural integrators in oculomotor systems: a systematic narrative literature review. *Acta Ophthalmol* 2018;96(2):e111–e118.
38. Fujita H, Kodama T, Du Lac S. Modular output circuits of the fastigial nucleus for diverse motor and nonmotor functions of the cerebellar vermis. *elife* 2020;9:e58613.
39. Flemming KD. Brainstem and Cranial Nerves: 11 Longitudinal Pathways of the Brainstem. Oxford, UK: Mayo Clinic Neurology Board Review; 2021:99.
40. Rucker JC, Lavin PJ. Neuro-ophthalmology: ocular motor system. Amsterdam, The Netherlands: Bradley’s Neurology in Clinical Practice E-Book; 2021:201.
41. Behrens TE, Berg HJ, Jbabdi S, Rushworth MF, Woolrich MW. Probabilistic diffusion tractography with multiple fibre orientations: what can we gain? *NeuroImage* 2007;34(1):144–155.
42. Raffelt DA, Tournier J-D, Smith RE, Vaughan DN, Jackson G, Ridgway GR, Connelly A. Investigating white matter fibre density and morphology using fixel-based analysis. *NeuroImage* 2017;144:58–73.
43. Raffelt DA, Smith RE, Ridgway GR, et al. Connectivity-based fixel enhancement: whole-brain statistical analysis of diffusion MRI measures in the presence of crossing fibres. *NeuroImage* 2015;117:40–55.
44. Winkler AM, Ridgway GR, Webster MA, Smith SM, Nichols TE. Permutation inference for the general linear model. *NeuroImage* 2014;92:381–397.
45. Fan L, Li H, Zhuo J, et al. The human brainnetome atlas: a new brain atlas based on connective architecture. *Cereb Cortex* 2016;26(8):3508–3526.
46. Zeidman P, Jafarian A, Corbin N, Seghier ML, Razi A, Price CJ, Friston KJ. A guide to group effective connectivity analysis, part 1: first level analysis with DCM for fMRI. *NeuroImage* 2019;200:174–190.
47. Frässle S, Harrison SJ, Heinze J, et al. Regression dynamic causal modeling for resting-state fMRI. *Hum Brain Mapp* 2021;42(7):2159–2180.
48. Zeidman P, Jafarian A, Seghier ML, Litvak V, Cagnan H, Price CJ, Friston KJ. A guide to group effective connectivity analysis, part 2: second level analysis with PEB. *NeuroImage* 2019;200:12–25.
49. Johansen-Berg H, Behrens TE. Diffusion MRI: From Quantitative Measurement to In Vivo Neuroanatomy. Oxford, UK: Academic Press; 2013.
50. Zatorre RJ, Fields RD, Johansen-Berg H. Plasticity in gray and white: neuroimaging changes in brain structure during learning. *Nat Neurosci* 2012;15(4):528–536.
51. Friston KJ. Statistical Parametric Mapping. New York, New York: Neuroscience Databases: A Practical Guide; 2003:237–250.
52. Bathien N. Inhibition in neurophysiology. *L’encephale* 1978;4(5 Suppl):481–488.
53. Voogd J, Schraa-Tam CK, van der Geest JN, De Zeeuw CI. Visuomotor cerebellum in human and nonhuman primates. *Cerebellum* 2012;11:392–410.
54. Shaikh AG, Zee DS, Jinnah H. Oscillatory head movements in cervical dystonia: dystonia, tremor, or both? *Mov Disord* 2015;30(6):834–842.
55. Shaikh AG, Wong AL, Zee DS, Jinnah HA. Keeping your head on target. *J Neurosci* 2013;33(27):11281–11295.
56. Fukushima K, Ohno M, Kato M. Responses of cat mesencephalic reticulospinal neurons to stimulation of superior colliculus, pericruciate cortex, and neck muscle afferents. *Exp Brain Res* 1981;44(4):441–444.
57. Bakker D, Richmond F, Abrahams V. Central projections from cat suboccipital muscles: a study using transganglionic transport of horseradish peroxidase. *J Comp Neurol* 1984;228(3):409–421.
58. Snyder AD, Ma L, Steinberg JL, Woisard K, Moeller FG. Dynamic causal modeling self-connectivity findings in the functional magnetic resonance imaging neuropsychiatric literature. *Front Neurosci* 2021;15:636273.
59. Friston KJ, Harrison L, Penny W. Dynamic causal modelling. *NeuroImage* 2003;19(4):1273–1302.
60. Ruigrok TJ. Cerebellar Influences on Descending Spinal Motor Systems. London, UK: Handbook of the Cerebellum and Cerebellar Disorders; 2021:625–660.

61. Coffman KA, Dum RP, Strick PL. Cerebellar vermis is a target of projections from the motor areas in the cerebral cortex. *Proc Natl Acad Sci* 2011;108(38):16068–16073.
62. Mahajan A, Gupta P, Jacobs J, et al. Impaired saccade adaptation in tremor-dominant cervical dystonia—evidence for maladaptive cerebellum. *Cerebellum* 2021;20:678–686.
63. Hirsig A, Barbey C, Schüpbach MW, Bargiotas P. Oculomotor functions in focal dystonias: a systematic review. *Acta Neurol Scand* 2020;141(5):359–367.
64. Lehericy S, Tijssen MA, Vidailhet M, Kaji R, Meunier S. The anatomical basis of dystonia: current view using neuroimaging. *Mov Disord* 2013;28(7):944–957.
65. Hikosaka O, Takikawa Y, Kawagoe R. Role of the basal ganglia in the control of purposive saccadic eye movements. *Physiol Rev* 2000; 80(3):953–978.

## Supporting Data

Additional Supporting Information may be found in the online version of this article at the publisher's web-site.